



Diagnostic Slide Session, Case 2020-3

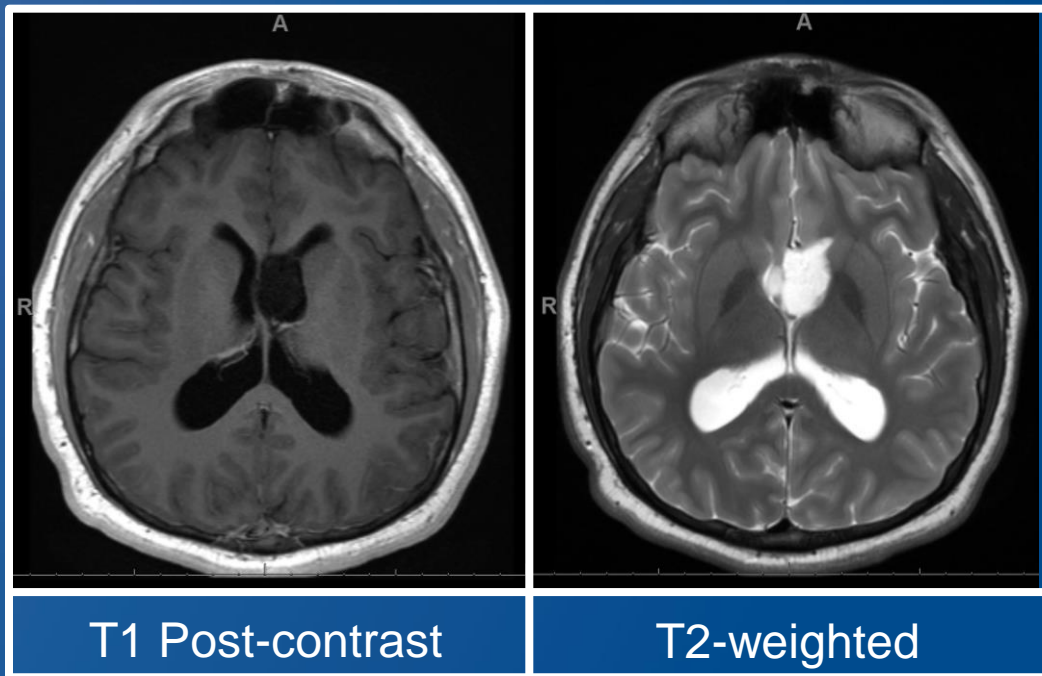
Bartholomew White, M.D., Meaghan Morris, M.D., Ph.D.,
Christopher Gocke, M.D., Fausto Rodriguez, M.D.

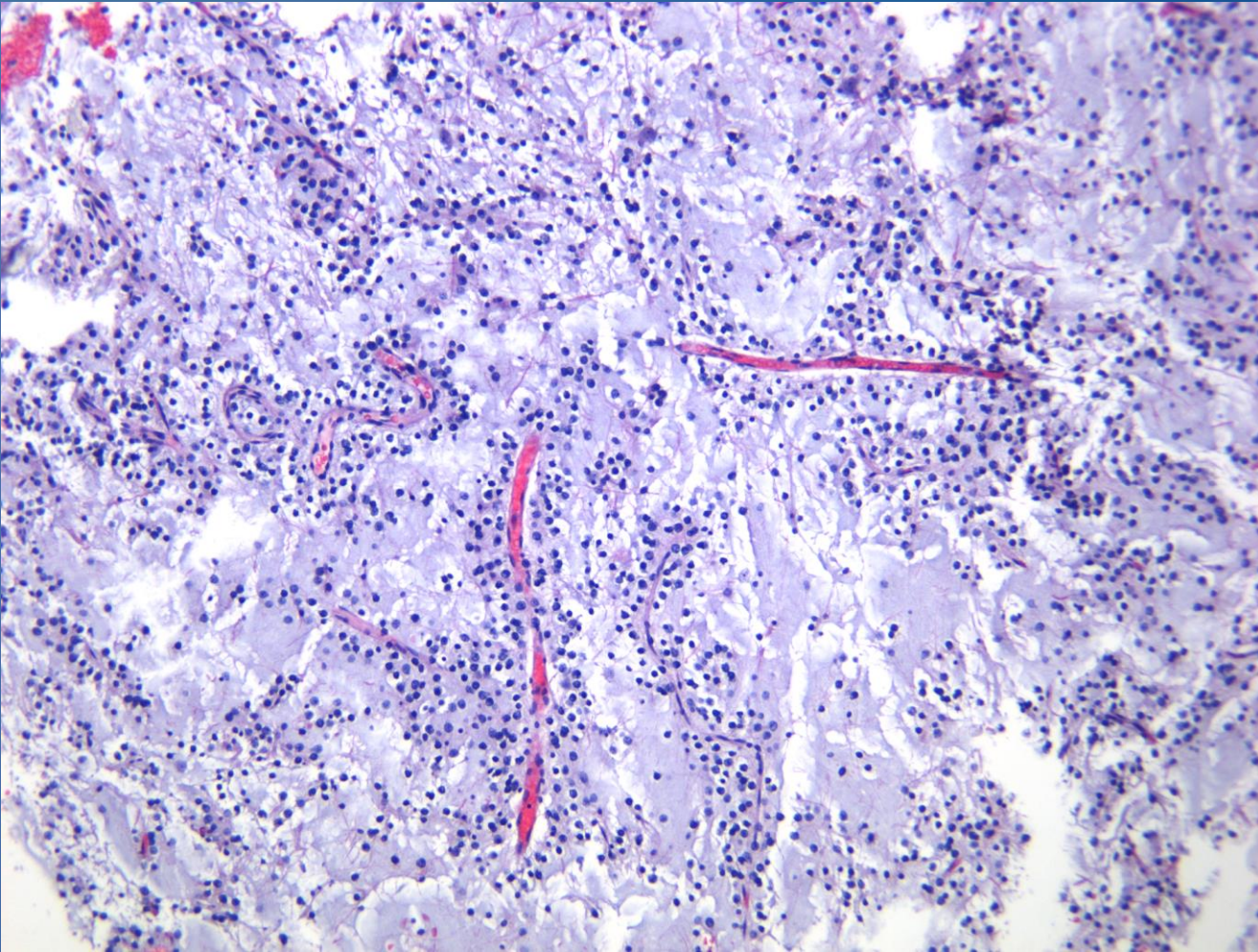
Presented by: Bartholomew White, M.D.
June 10, 2020

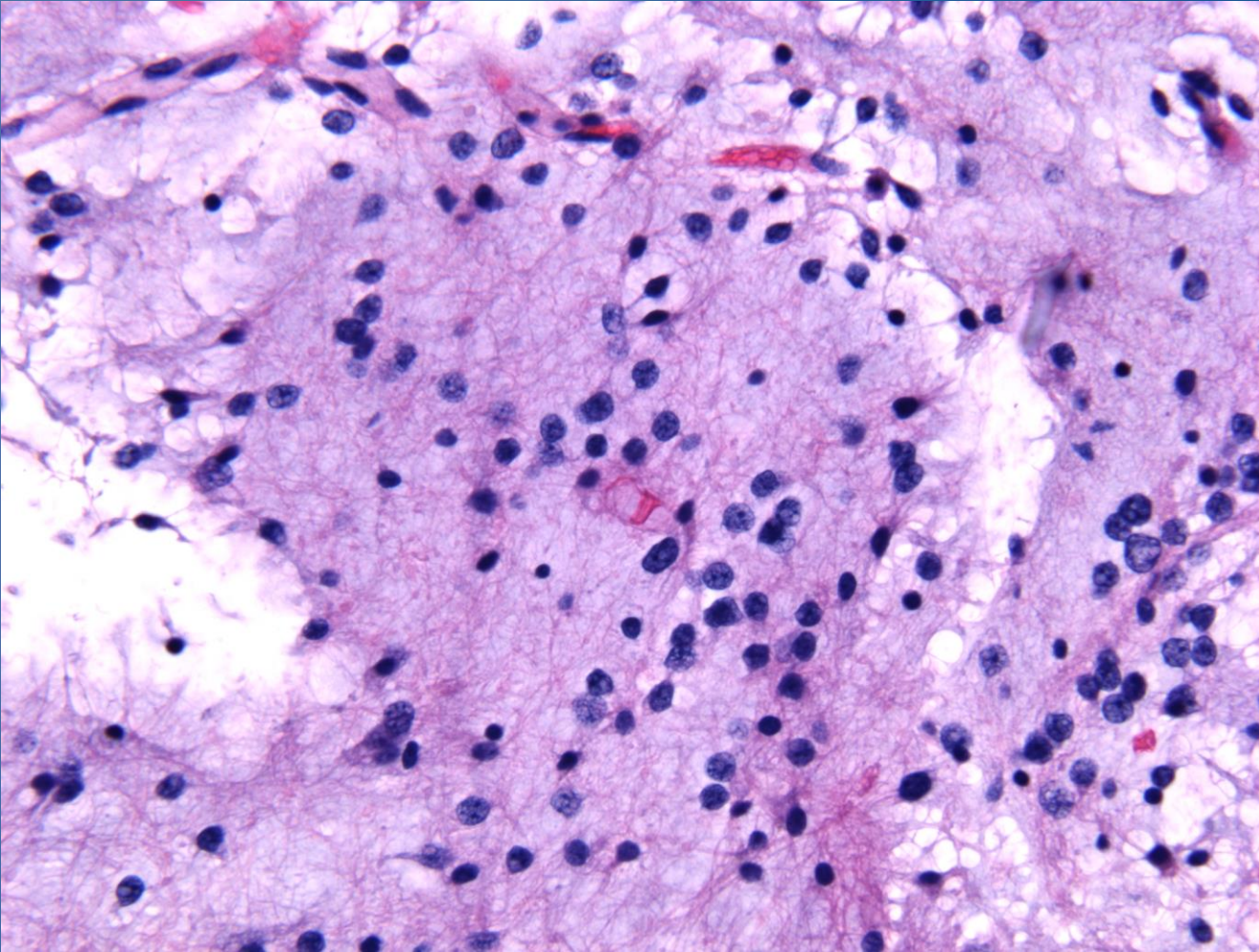
No Disclosures

Clinical History and Imaging

- A 20-year-old male presents with episodes of unresponsiveness or writhing movements.
- No other pertinent past medical history.





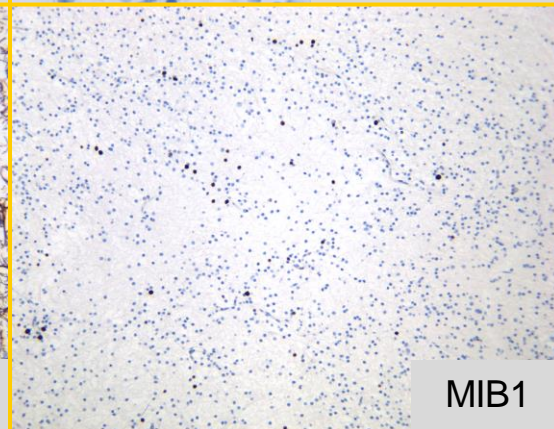
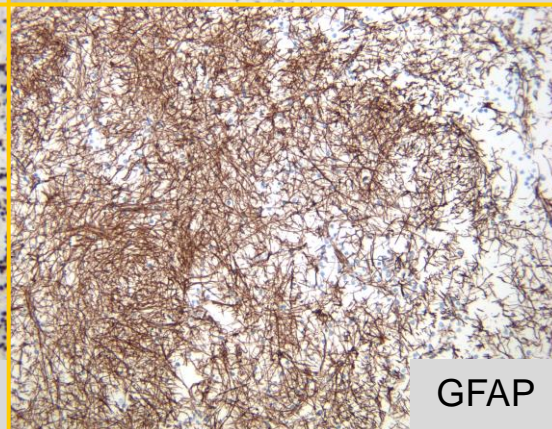
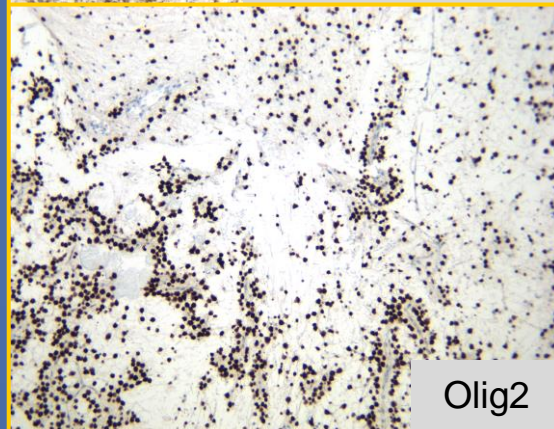
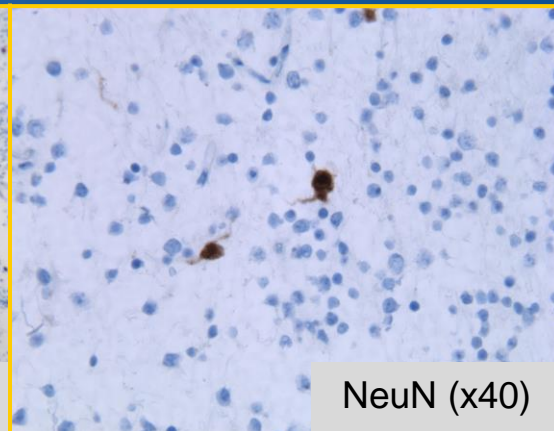
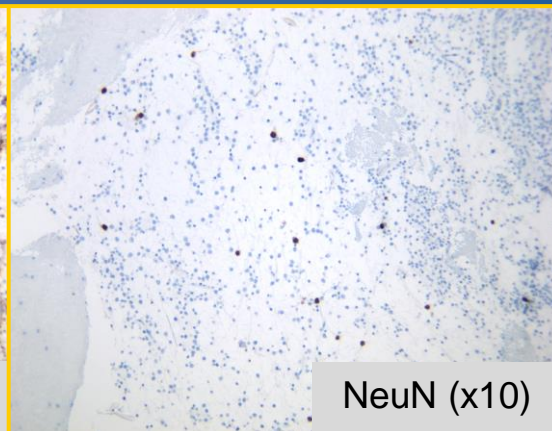
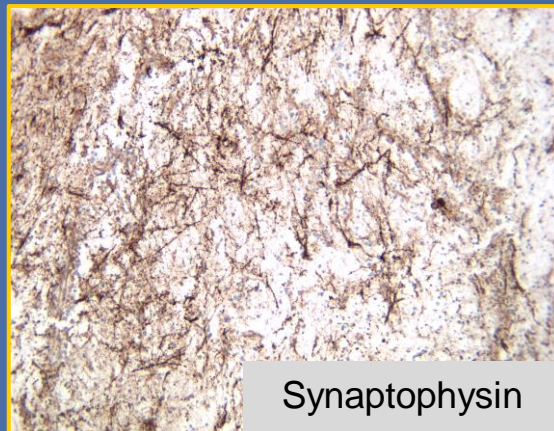


Discussion points

- 1) Differential Diagnosis
- 2) Ancillary Testing
- 3) Additional Comments

Differential Diagnosis

- Dysembryoplastic neuroepithelial tumor
- Myxoid glioneuronal tumor
- Pilocytic astrocytoma
- Central neurocytoma
- Rosette-forming glioneuronal tumor



Dysembryoplastic Neuroepithelial Tumor-Like Neoplasm of the Septum Pellucidum: A Lesion Often Misdiagnosed as Glioma

Report of 10 Cases

Blaire L. Baisden, M.D., Daniel J. Brat, M.D., Ph.D., Elias R. Melhem, M.D., Marc K. Rosenblum, M.D., Andrew P. King, M.B., Ch.B., M.R.C.P.ATH, and Peter C. Burger, M.D.

Molecular Analysis

Key mutation results:

BRAF NOT DETECTED
IDH1 NOT DETECTED
IDH2 NOT DETECTED

Notes	Chr:Pos	Base Change	Gene	AA_change	%VAF
Note	chr4:55136831	AA>TT	PDGFRA	p.K385L	40.15



Myxoid glioneuronal tumor of the septum pellucidum and lateral ventricle is defined by a recurrent *PDGFRA* p.K385 mutation and DNT-like methylation profile

David A. Solomon^{1,2} · Andrey Korshunov^{3,4} · Martin Sill^{5,6,7} · David T. W. Jones^{5,6} · Marcel Kooij^{5,6} · Stefan M. Pfister^{5,6,7} · Xuemo Fan⁸ · Serguei Bannykh⁸ · Jethro Hu⁹ · Moise Danielpour¹⁰ · Rong Li¹¹ · James Johnston¹² · Elaine Cham¹³ · Tabitha Cooney¹⁴ · Peter P. Sun¹⁵ · Nancy Ann Oberheim Bush¹⁶ · Michael McDermott¹⁷ · Jessica Van Ziffle^{1,2} · Courtney Onodera^{1,2} · James P. Grenert^{1,2} · Boris C. Bastian^{1,2} · Javier E. Villanueva-Meyer¹⁸ · Melike Pekmezci¹ · Andrew W. Bollen¹ · Arie Perry^{1,17}

Received: 28 June 2018 / Revised: 4 July 2018 / Accepted: 4 July 2018
© Springer-Verlag GmbH Germany, part of Springer Nature 2018

RESEARCH ARTICLE

Myxoid glioneuronal tumor, *PDGFRA* p.K385-mutant: clinical, radiologic, and histopathologic features

Calixto-Hope G. Lucas¹ ; Javier E. Villanueva-Meyer²; Nicholas Whipple³; Nancy Ann Oberheim Bush^{4,5}; Tabitha Cooney⁶; Susan Chang^{4,5}; Michael McDermott⁷; Mitchel Berger⁷; Elaine Cham⁸; Peter P. Sun⁹; Angelica Putnam¹⁰; Hong Zhou¹⁰; Robert Bollo¹¹; Samuel Cheshier¹¹; Matthew M. Poppe¹²; Kar-Ming Fung¹³; Sarah Sung¹⁴; Chad Glenn¹⁵; Xuemo Fan¹⁶; Serguei Bannykh¹⁶; Jethro Hu¹⁷; Moise Danielpour¹⁸; Rong Li¹⁹; Elizabeth Alva²⁰; James Johnston²¹; Jessica Van Ziffle^{1,22}; Courtney Onodera^{1,22}; Patrick Devine^{1,22}; James P. Grenert^{1,22}; Julieann C. Lee¹ · Melike Pekmezci¹ · Tarik Tihan¹ · Andrew W. Bollen¹; Arie Perry^{1,7} ; David A. Solomon^{1,22}

Neuro-Oncology






21(6), 800–808, 2019 | doi:10.1093/neuonc/noz037 | Advance Access date 6 February 2019

Septal dysembryoplastic neuroepithelial tumor: a comprehensive clinical, imaging, histopathologic, and molecular analysis

Jason C. H. Chiang, Julie H. Harrel, Ryuma Tanaka, Xiaoyu Li, Ji Wen, Chenran Zhang, Daniel R. Boué, Tracy M. Rauch, J. Todd Boyd, Jie Chen, Joseph C. Corbo, Thomas W. Bouldin, Scott W. Elton, Le-Wen L. Liu, Deborah Schofield, Sunhee C. Lee, John-Paul Bouffard, Maria-Magdalena Georgescu, Rimal H. Dossani, Maria A. Aguiar, Richard A. Sances, Ali G. Saad, Frederick A. Boop, Ibrahim Qaddoumi, and David W. Ellison

MEETING REPORT

cIMPACT-NOW update 6: new entity and diagnostic principle recommendations of the cIMPACT-Utrecht meeting on future CNS tumor classification and grading

David N. Louis¹ ; Pieter Wesseling^{2,3}; Kenneth Aldape⁴; Daniel J. Brat⁵; David Capper^{6,7}; Ian A. Cree⁸; Charles Eberhart⁹; Dominique Figarella-Branger¹⁰ ; Maryam Fouladi¹¹; Gregory N. Fuller¹²; Caterina Giannini^{13,14}; Christine Haberler¹⁵; Cynthia Hawkins¹⁶; Takashi Komori¹⁷; Johan M. Kros¹⁸; HK Ng¹⁹; Brent A. Orr²⁰; Sung-Hye Park²¹; Werner Paulus²²; Arie Perry²³; Torsten Pietsch²⁴ ; Guido Reifenberger^{25,26}; Marc Rosenblum²⁷; Brian Rous^{8,28}; Felix Sahm^{29,30,31}; Chitra Sarkar³² ; David A. Solomon²³ ; Uri Tabori³³; Martin J. van den Bent³⁴; Andreas von Deimling^{29,30}; Michael Weller³⁵; Valerie A. White⁸; David W. Ellison^{8,20}

Myxoid glioneuronal tumor

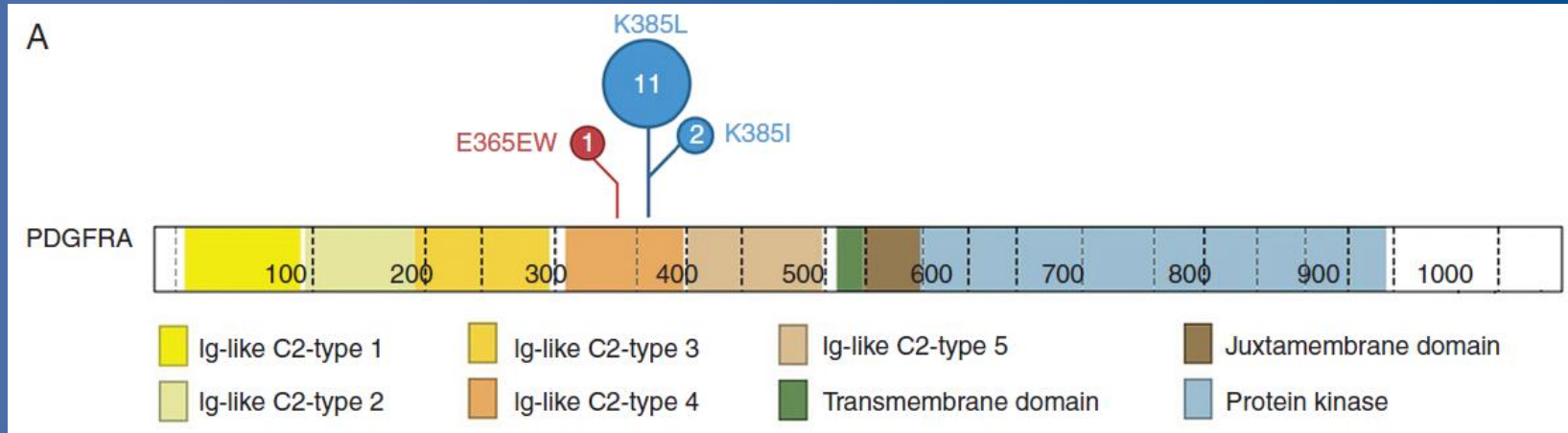
Clinical Features

- Median age of presentation is 23.6 years
- Headaches are the most common presenting symptom
- Associated with relapse in a minority of patients

Imaging Characteristics

- Circumscribed mass most often in the septal region
- Indolent neoplasms
 - Can show ventricular dissemination
- Associated with hydrocephalus

Molecular Characteristics



The K385 mutation most commonly involves a dinucleotide substitution which codes for the Ig-like C2-type 4 domain. This domain mediates the receptor-receptor interaction required for protein activation, suggesting a gain of function mutation.

Thank you for your attention.



A special thanks to my mentors.

- The Johns Hopkins crew
 - Charles Eberhart
 - David Nauen
 - Fausto Rodriguez
 - Juan Troncoso
 - Liam Chen
- Charles Specht
 - Penn State Hershey Medical Center
- Harry Kellermier
 - Summa Health Systems
- Jennifer Baccon
 - Akron Children's Hospital

Selected References

- 1) Baisden BL, Brat DJ, Melhem ER, Rosenblum MK, King AP, Burger PC. Dysembryoplastic neuroepithelial tumor-like neoplasm of the septum pellucidum: a lesion often misdiagnosed as glioma: report of 10 cases. *Am J Surg Pathol*. 2001;25(4):494-499.
- 2) Solomon DA, Korshunov A, Sill M, et al. Myxoid glioneuronal tumor of the septum pellucidum and lateral ventricle is defined by a recurrent PDGFRA p.K385 mutation and DNT-like methylation profile. *Acta Neuropathol*. 2018;136(2):339-343.
- 3) Lucas CG, Villanueva-Meyer JE, Whipple N, et al. Myxoid glioneuronal tumor, PDGFRA p.K385-mutant: clinical, radiologic, and histopathologic features. *Brain Pathol*. 2020;30(3):479-494.
- 4) Chiang JCH, Harreld JH, Tanaka R, et al. Septal dysembryoplastic neuroepithelial tumor: a comprehensive clinical, imaging, histopathologic, and molecular analysis. *Neuro Oncol*. 2019;21(6):800-808.
- 5) Louis DN, Wesseling P, Aldape K, et al. cIMPACT-NOW update 6: new entity and diagnostic principle recommendations of the cIMPACT-Utrecht meeting on future CNS tumor classification and grading [published online ahead of print, 2020 Apr 19]. *Brain Pathol*. 2020;10.1111/bpa.12832.