

**49th ANNUAL DIAGNOSTIC SLIDE SESSION, 2008  
DIAGNOSES AND REFERENCES**

**MODERATOR: Anthony T. Yachnis, M.D.**

**EDITOR: Leroy R. Sharer, M.D.**

**Case 2008-2**

**Submitted by:** Juan M Bilbao, Beverley Young and Lorne Zinman, Departments of Pathology and Neurology, Sunnybrook Hospital, University of Toronto, CANADA

**Diagnosis: Sporadic glioneuronal tauopathy with features of corticobasal degeneration in a patient with the clinical phenotype of primary lateral sclerosis**

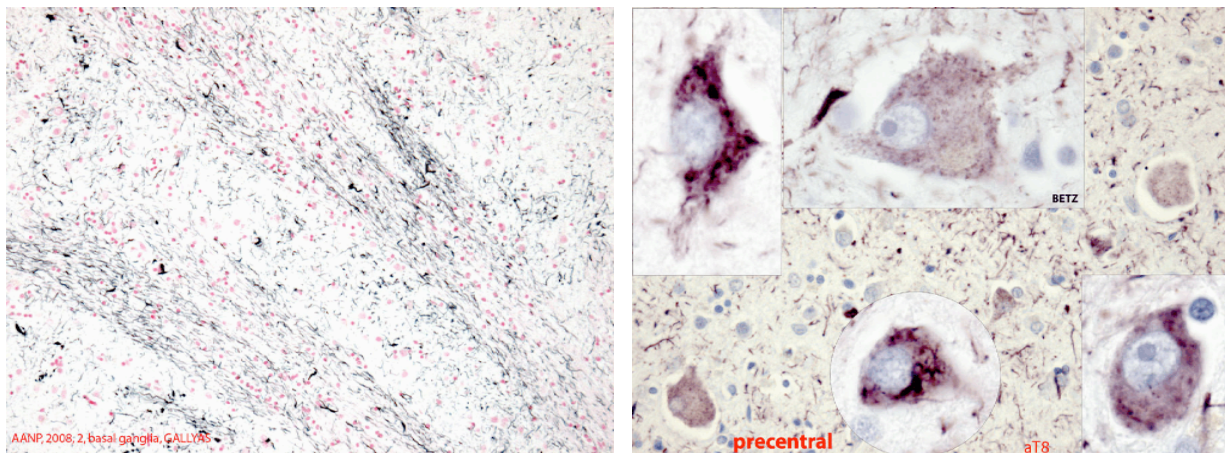
**Comment:** Ballooned neurons and Gallyas-positive threads were present in the pre-central gyrus but not in the post-central gyrus, also with intense gliosis by GFAP staining in the pre- but not the post-central gyrus. There was tau positivity in Betz cells and in large pyramidal neurons, with the glial pathology of CBD in white matter on Gallyas stain. The ventral horn neurons in the cord had tangles, with threads in the background.

**From the Presenter:** This was a florid tauopathy in a patient that clinically had features of primary lateral sclerosis without cognitive decline. There was no evidence of ALS pathology, and immunohistochemical studies for ubiquitin and TDP-43 were negative.

**References:**

Kuroda S, Otsuki S, Tateishi J, Hirano A: Neurofibrillary degeneration in a case of quadriplegia and myoclonic movement. *Acta Neuropathol* 1979; 45:105-109.

Piao Y-S, Tan C-F, Iwanaga K, Kakita A, et al: Sporadic four-repeat tauopathy with frontotemporal degeneration, parkinsonism and motor neuron disease. *Acta Neuropathol* 2005; 110:600-609.



Case 2008-2: Gallyas (left) and aT8 (right) stained sections.