

2014 Diagnostic Slide Session

Case 1

Vanessa Dimayuga Smith, MD

Dianne Wilson, MD
Janna Neltner, MD
Peter Nelson, MD, PhD
Craig Horbinski, MD, PhD



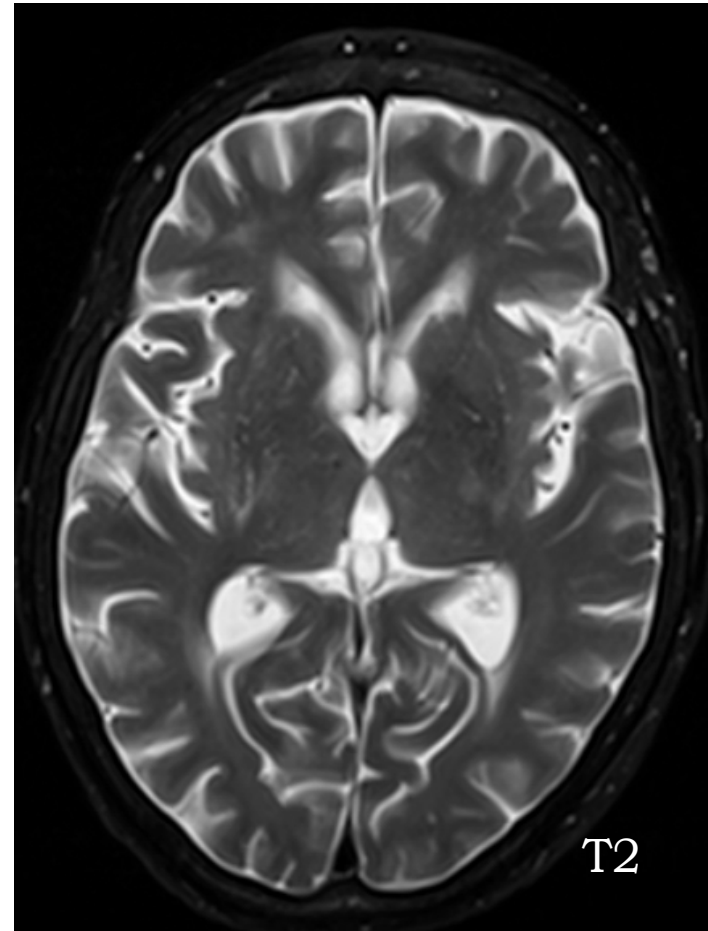
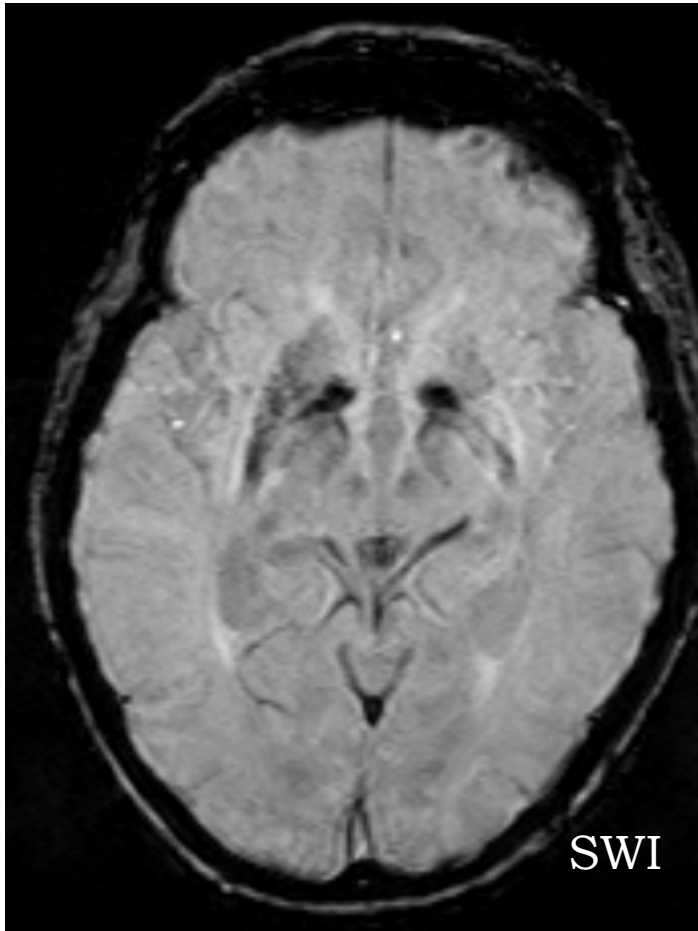
Disclosures

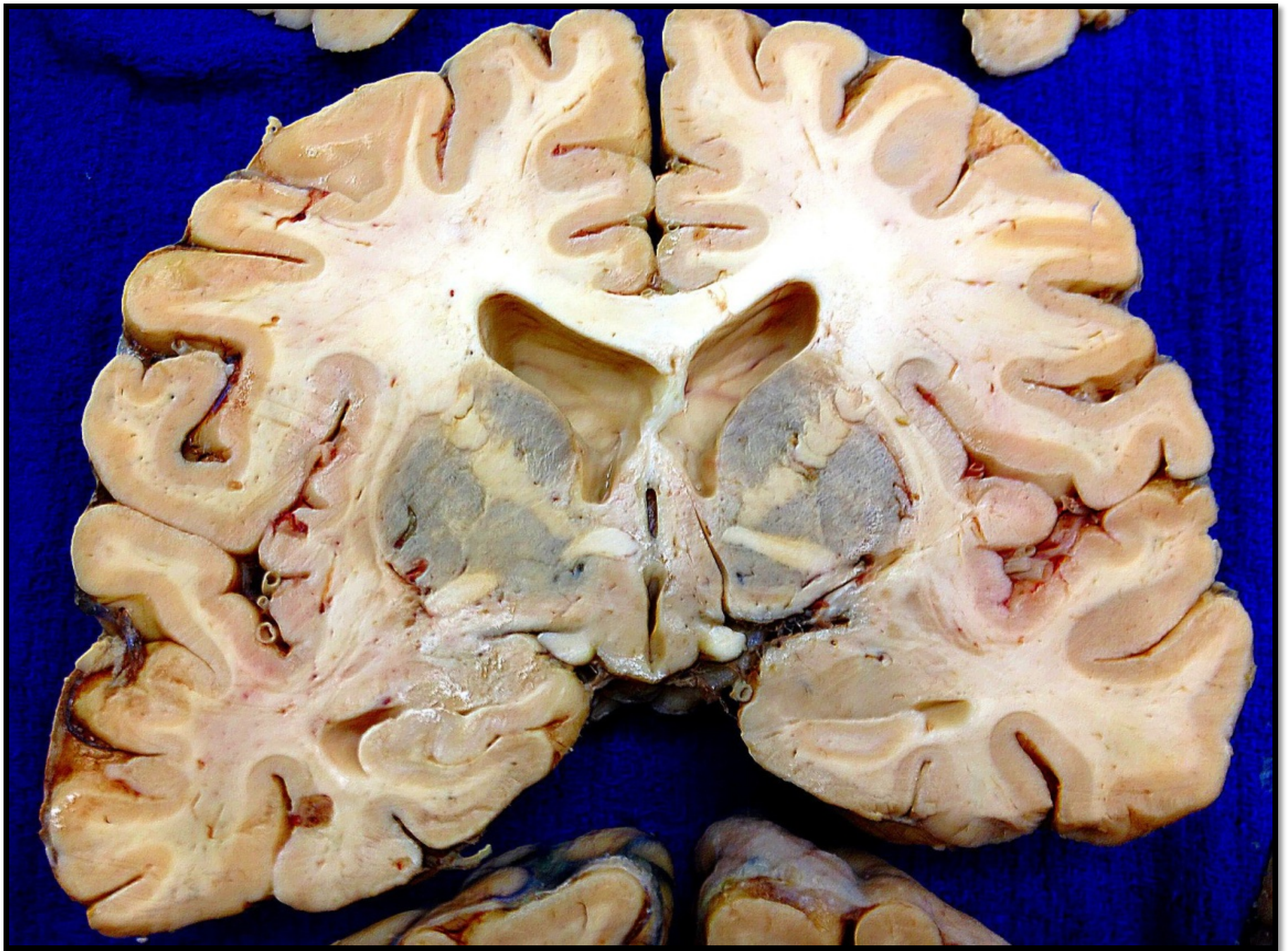
No relevant financial
relationships or conflicts
of interest

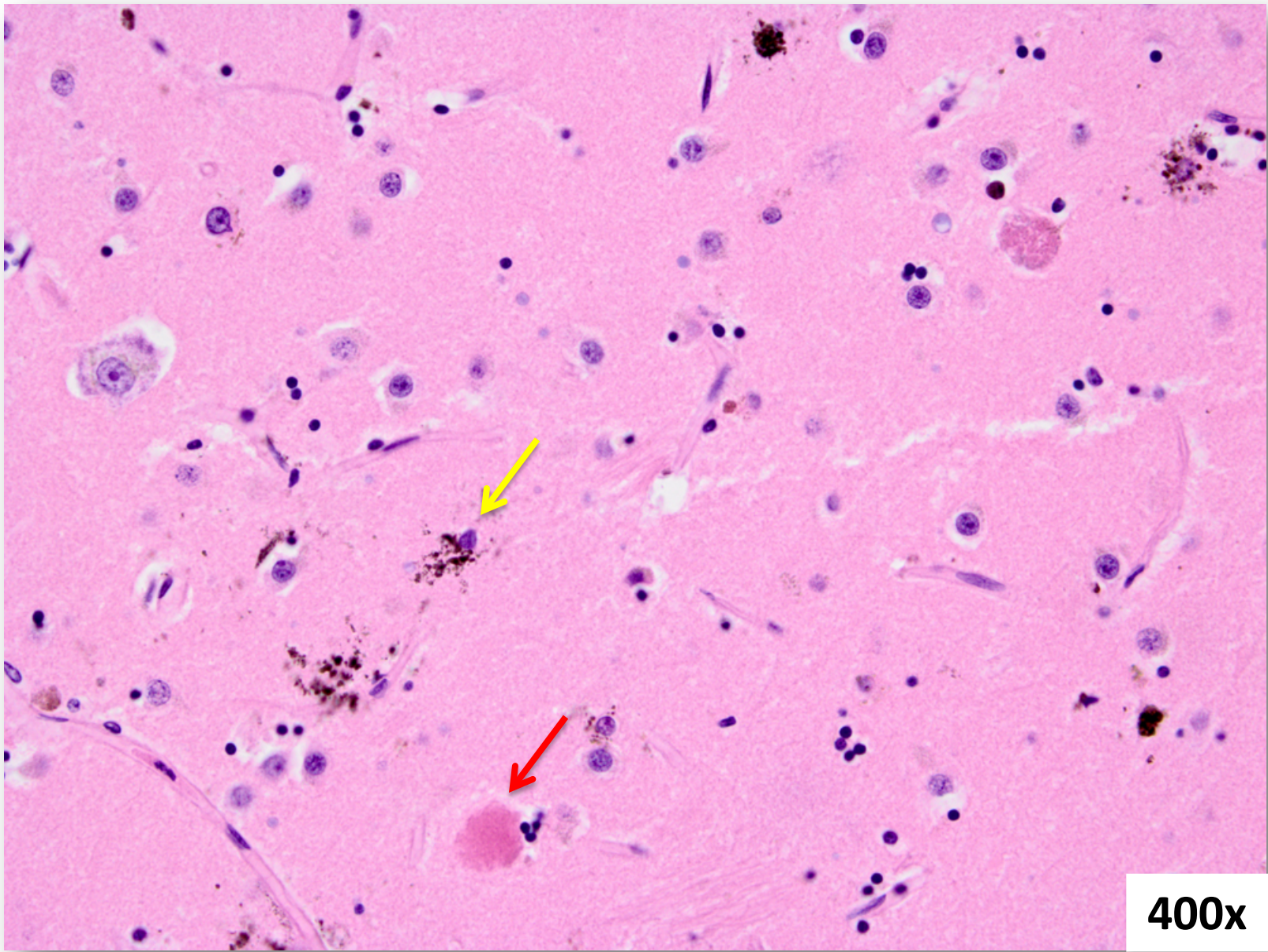
Clinical History

- 72 yo F with depression, possible wide based-gait and chronic RA
- Admitted for septic shock
- Died 10 days after admission
- Perforated gastric ulcer on autopsy

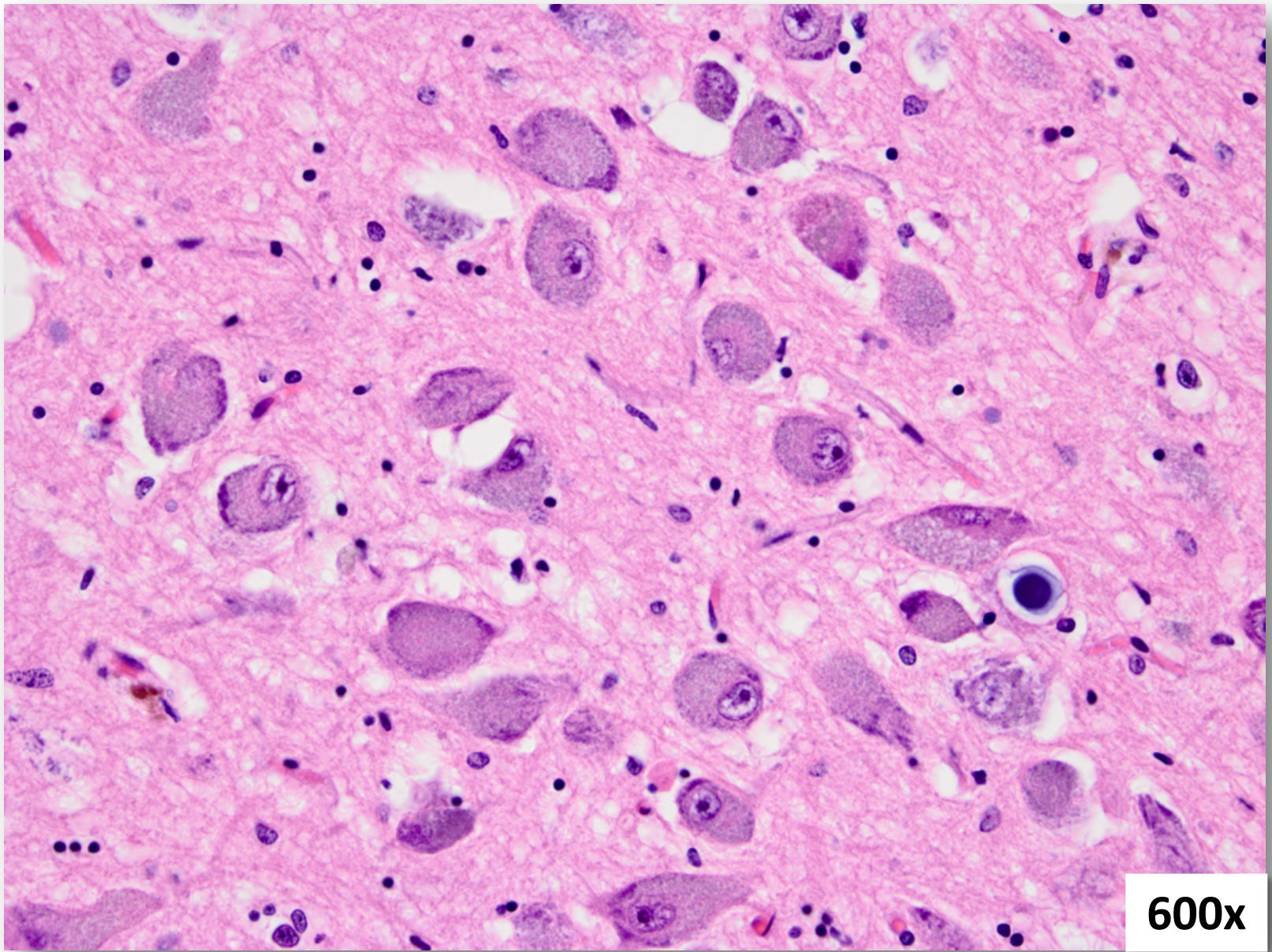
Imaging



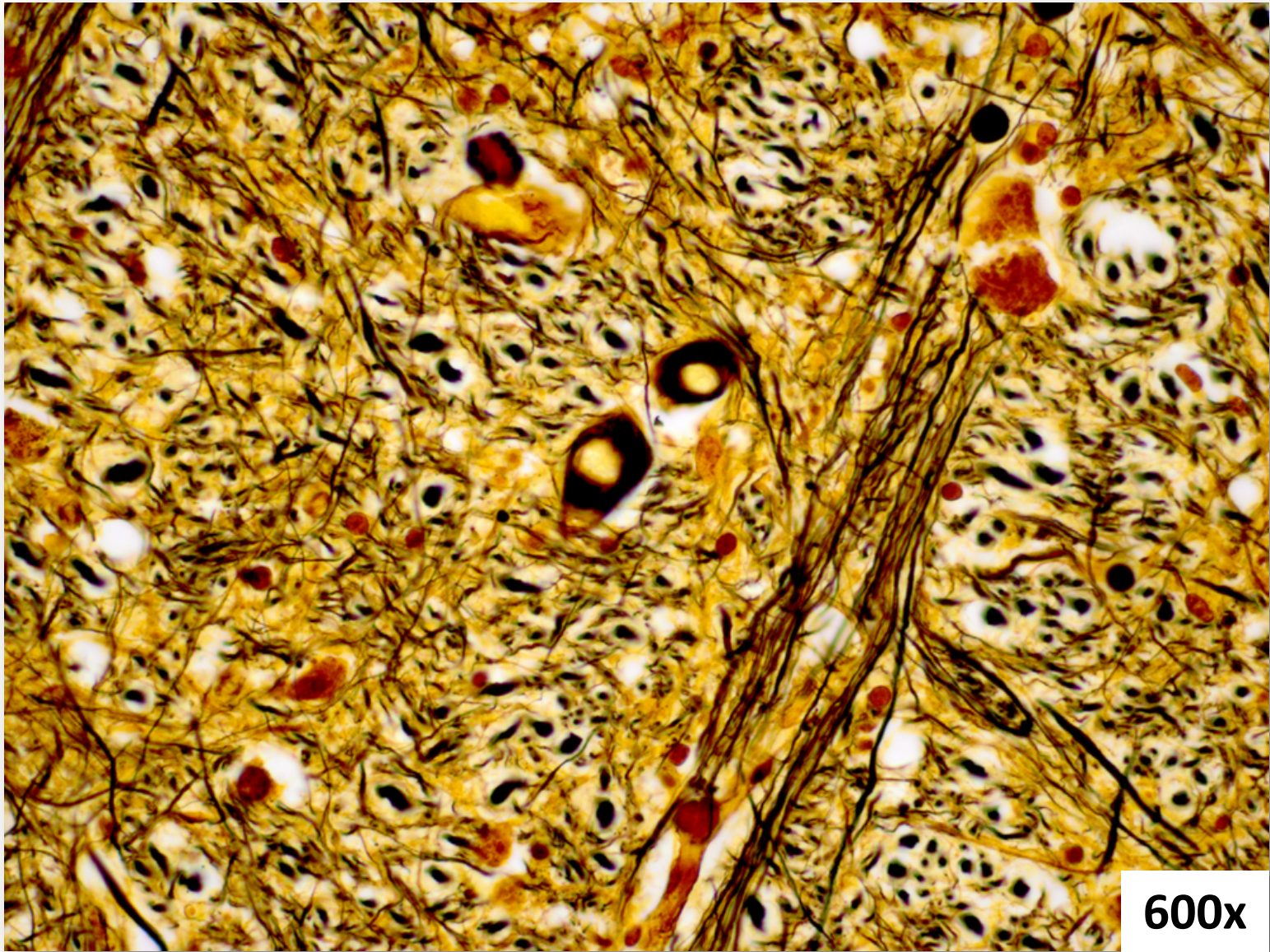




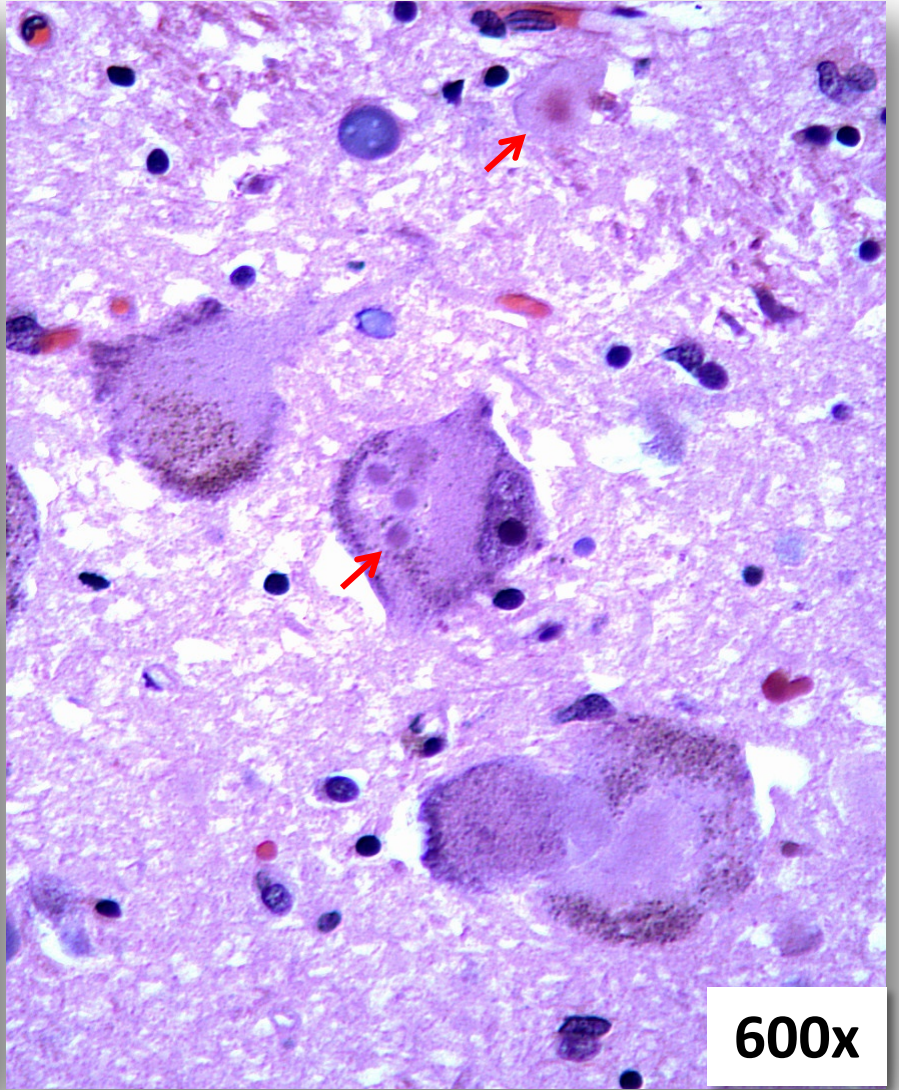
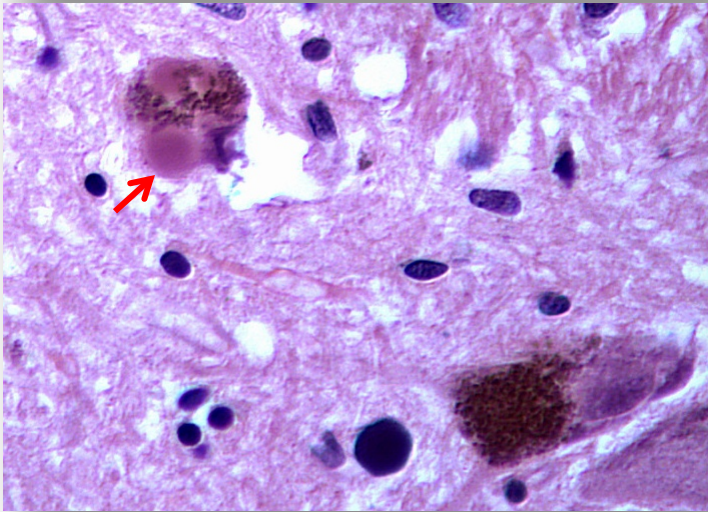
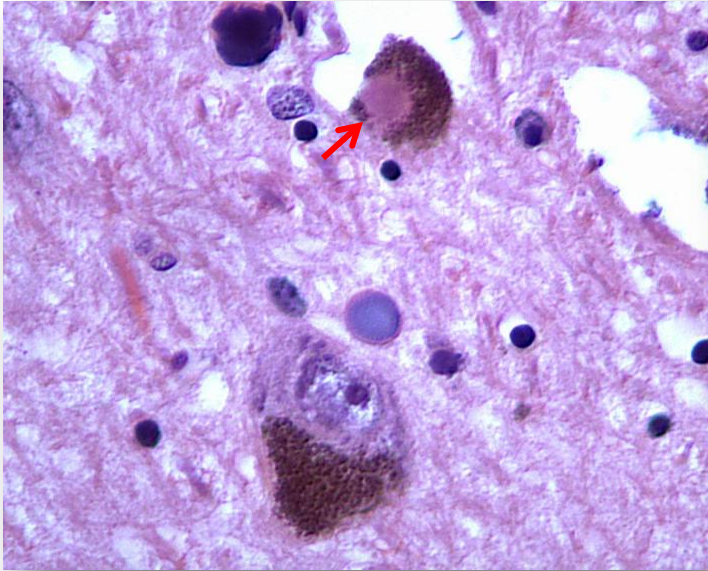
400x



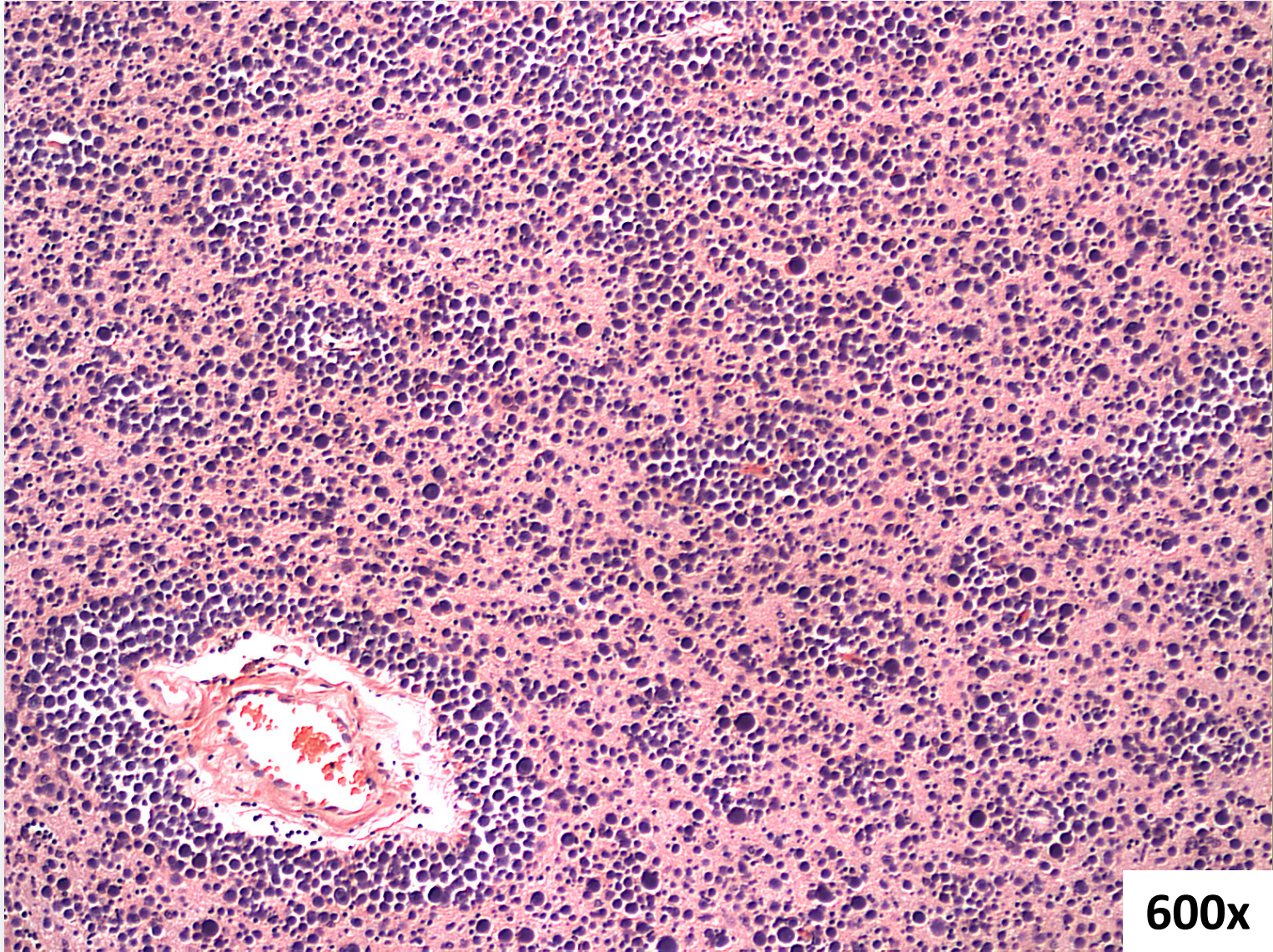
600x



600x



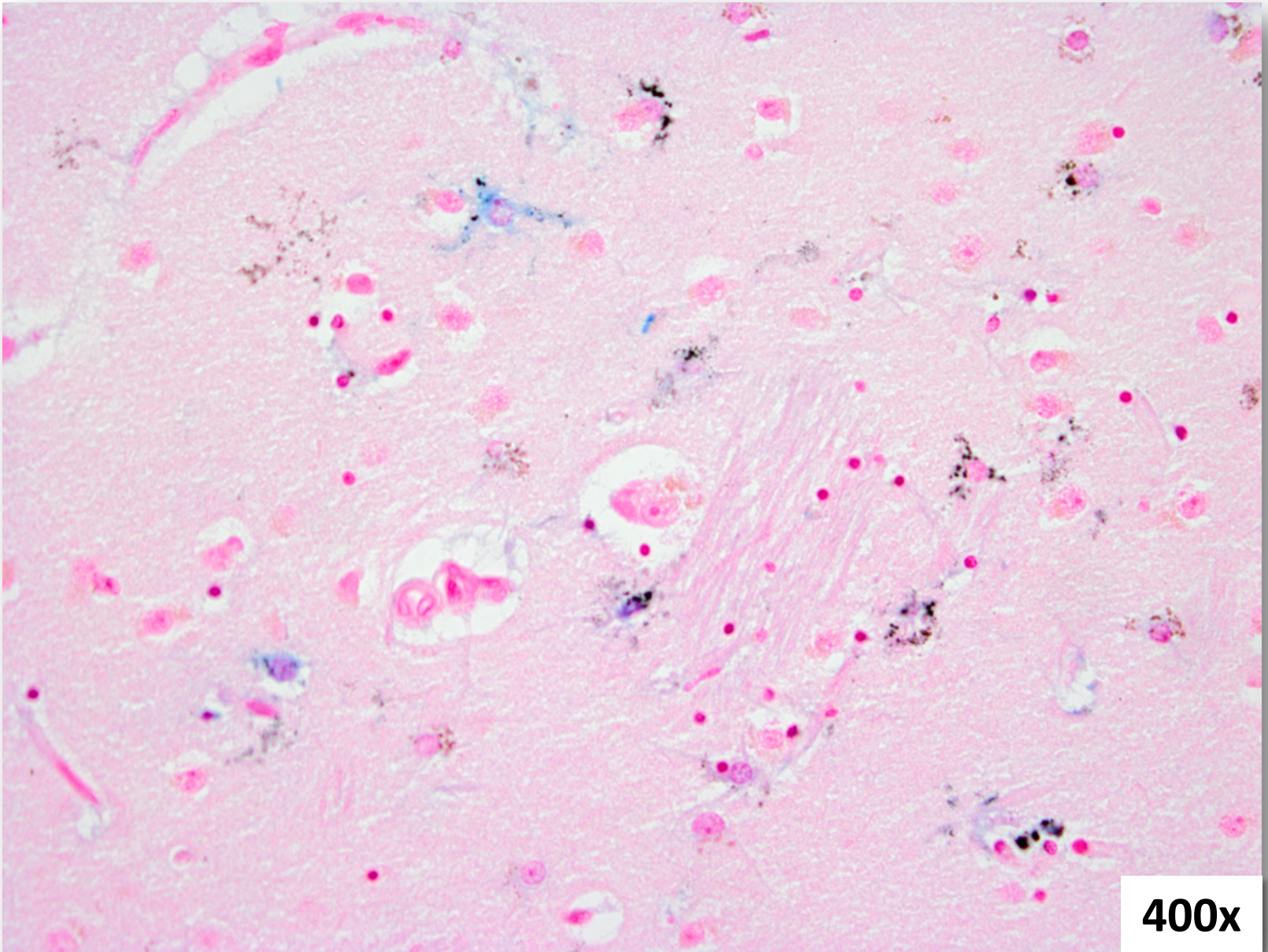
600x



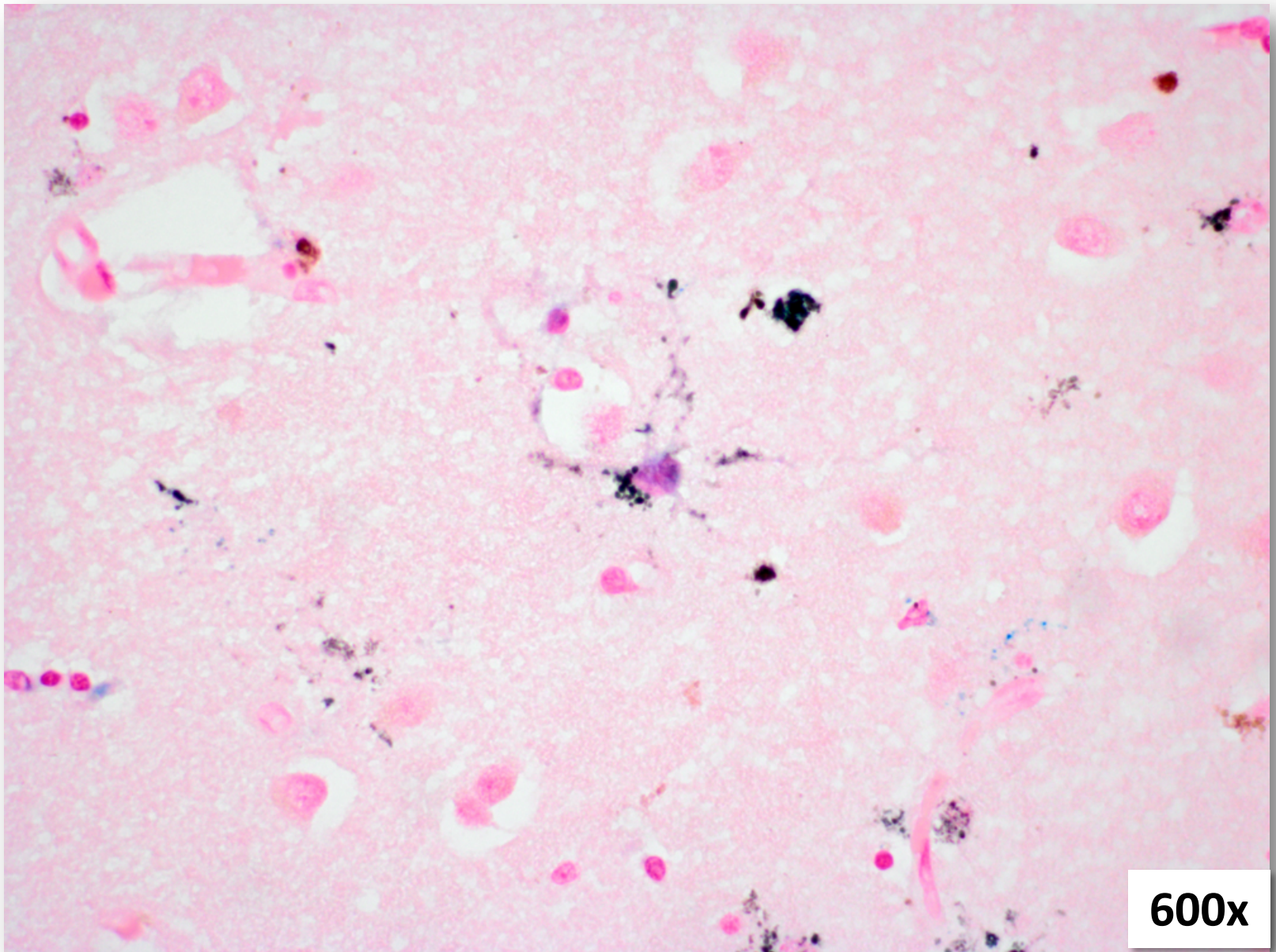
600x

Additional stains?

Diagnosis?



400x



600x

FINAL DIAGNOSIS

Neurodegeneration with
Brain Iron
Accumulation
(NBIA)

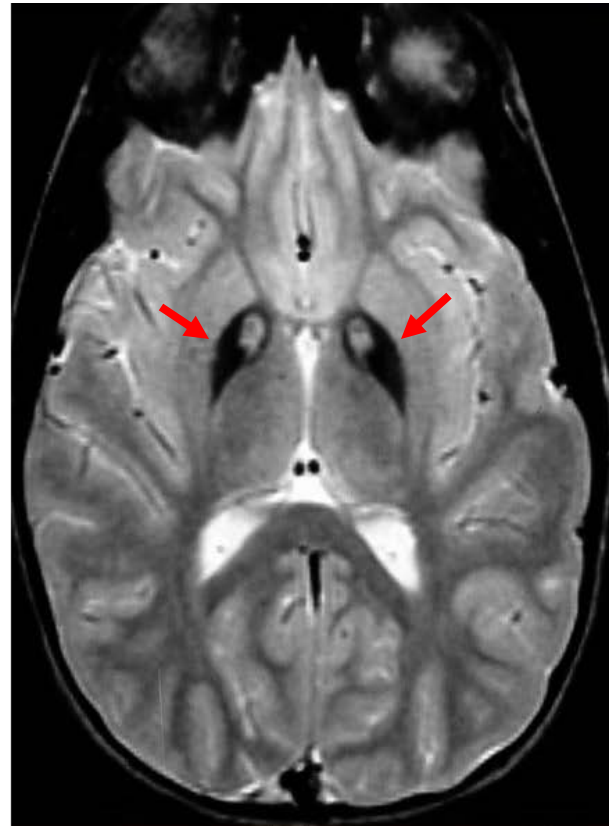
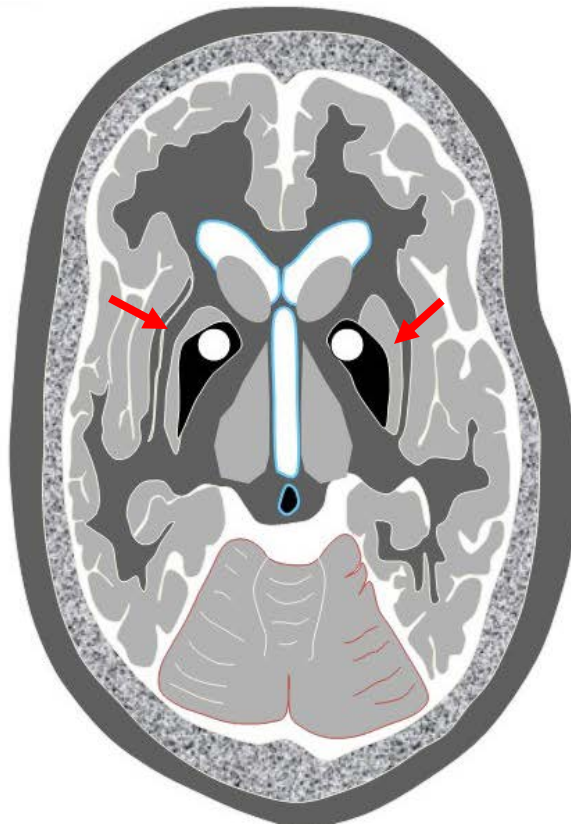
NBIA

- Clinically and genetically heterogeneous
- Pathologic Hallmarks
 - Iron deposition
 - Neuroaxonal spheroids
 - Lewy bodies +/- Tau pathology

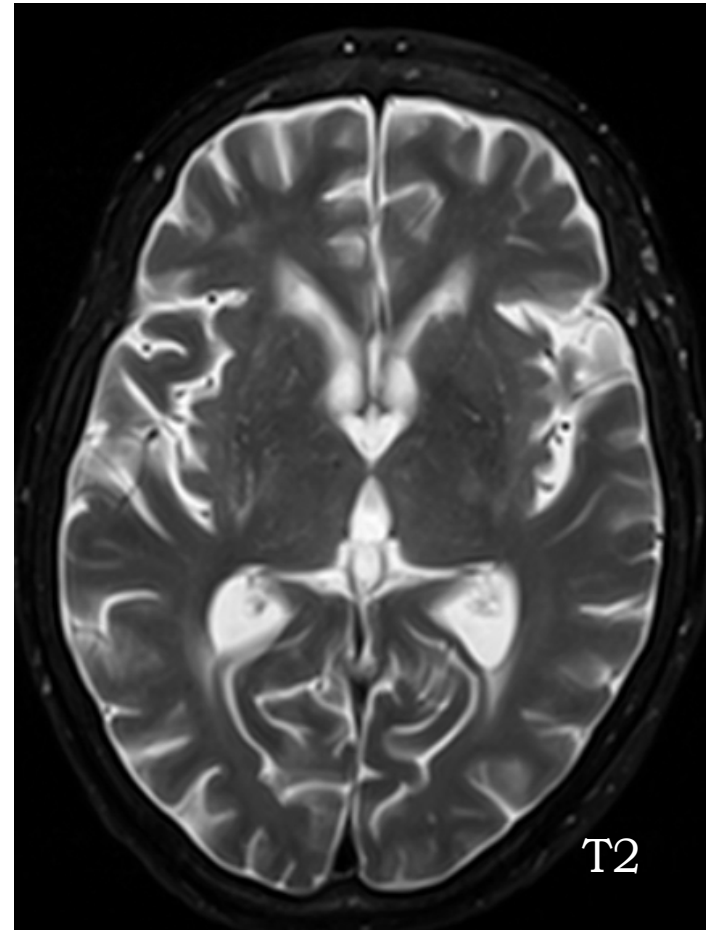
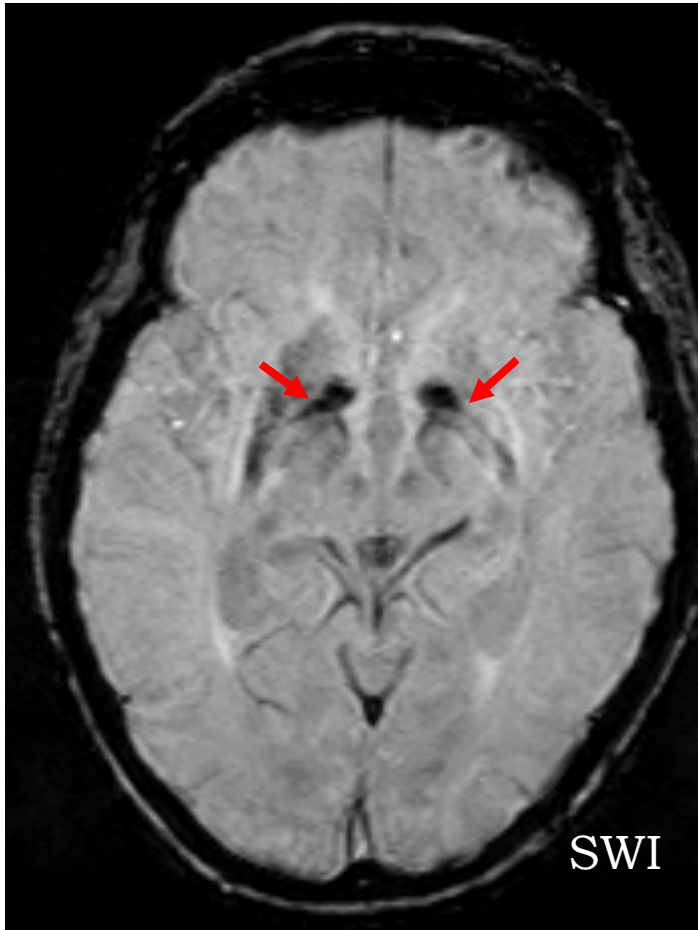
NBIA

- Extrapyrarnidal symptoms, gait abnormalities, dementia
- Poor prognosis
- No definitive therapy

“Eye of the Tiger” Sign



Imaging



NBIA Subtypes

Type	Associated Gene	Pathologic Features
Type I / PKAN	<i>PANK2</i>	NFTs, spheroids
Type II / PLAN	<i>PLA2G6</i>	Lewy bodies, NFTs, spheroids
MPAN	<i>c19orf12</i>	Lewy bodies, NFTs, spheroids
BPAN	<i>WDR45</i>	Lewy bodies, NFTs, spheroids
ACP	<i>CP</i>	Foamy spheroid bodies, bizarre astrocytes
NFT	<i>FTL</i>	Distorted, iron-laden nuclei
FAHN	<i>FA2H</i>	???
KRS	<i>ATP13A2</i>	???

Differential Diagnosis

- Huntington disease
- Wilson disease
- Other neuroaxonal dystrophy
- Parkinson's disease
- Vitamin E deficiency

References

1. Schneider, S., Hardy, J., Bhatia, K. “Syndromes of Neurodegeneration with Brain Iron Accumulation (NBIA): and Update of Clinical Presentations, Histologic and Genetic Underpinnings, and Treatment Considerations.” *Movement Disorders*, 2012, 27: 42-53.
2. Kruer, M. “The Neuropathology of Neurodegeneration with Brain Iron Accumulation.” *International Review of Neurobiology*, 2013, 110: 165 -194.
3. Schneider, S., Dusek, P., Hardy, J., Westenberger, A., Jancovic, J., Bhatia, K. “Genetics and Pathophysiology of Neurodegeneration with Brain Iron Accumulation (NBIA).” *Current Neuropharmacology*, 2013, 11: 59-79.

THANK YOU!