



JOHNS HOPKINS
M E D I C I N E

Case 2015-4

Abeer Tabbarah, M.D.

Barbara Crain, M.D. Ph.D.

Fausto Rodriguez, M.D.

Johns Hopkins University
Baltimore, M.D.

Disclosures

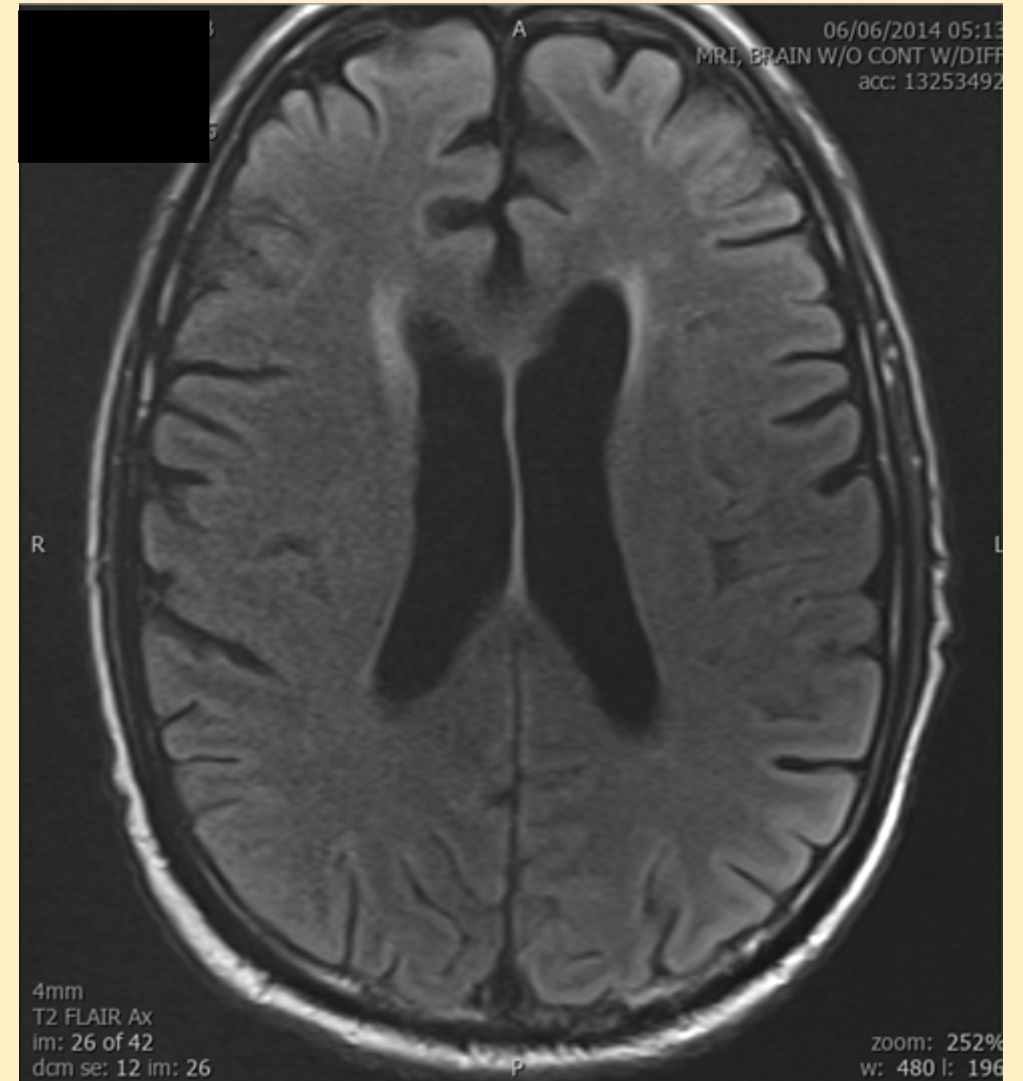
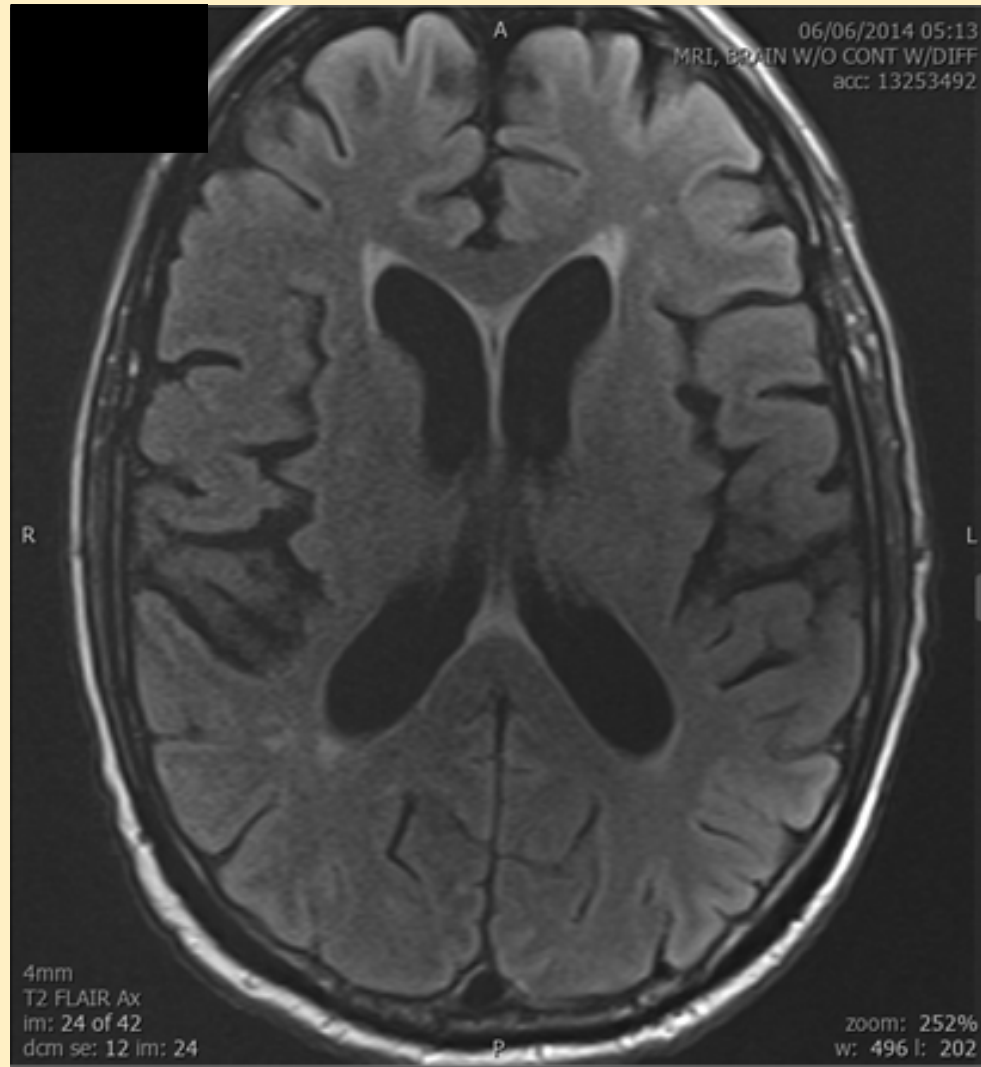
- None

Clinical history

Clinical history

- 73 year old black man
- PMH: angioimmunoblastic T-cell lymphoma (2009) s/p chemotherapy with complete remission (2010)
- Treatment-related acute myeloid leukemia (2012)
- Non-myeloablative haploidentical bone marrow transplant (4/2014)
- Aphasia, gait imbalance, and altered mental status (6/2014)
- Generalized tonic-clonic seizure (6/2014)
- Abnormal EEG activity (6-7/2014)
- Aplastic bone marrow with failed graft
- Polymicrobial bacteremia and septic shock (7/2014)

MRI T2 FLAIR



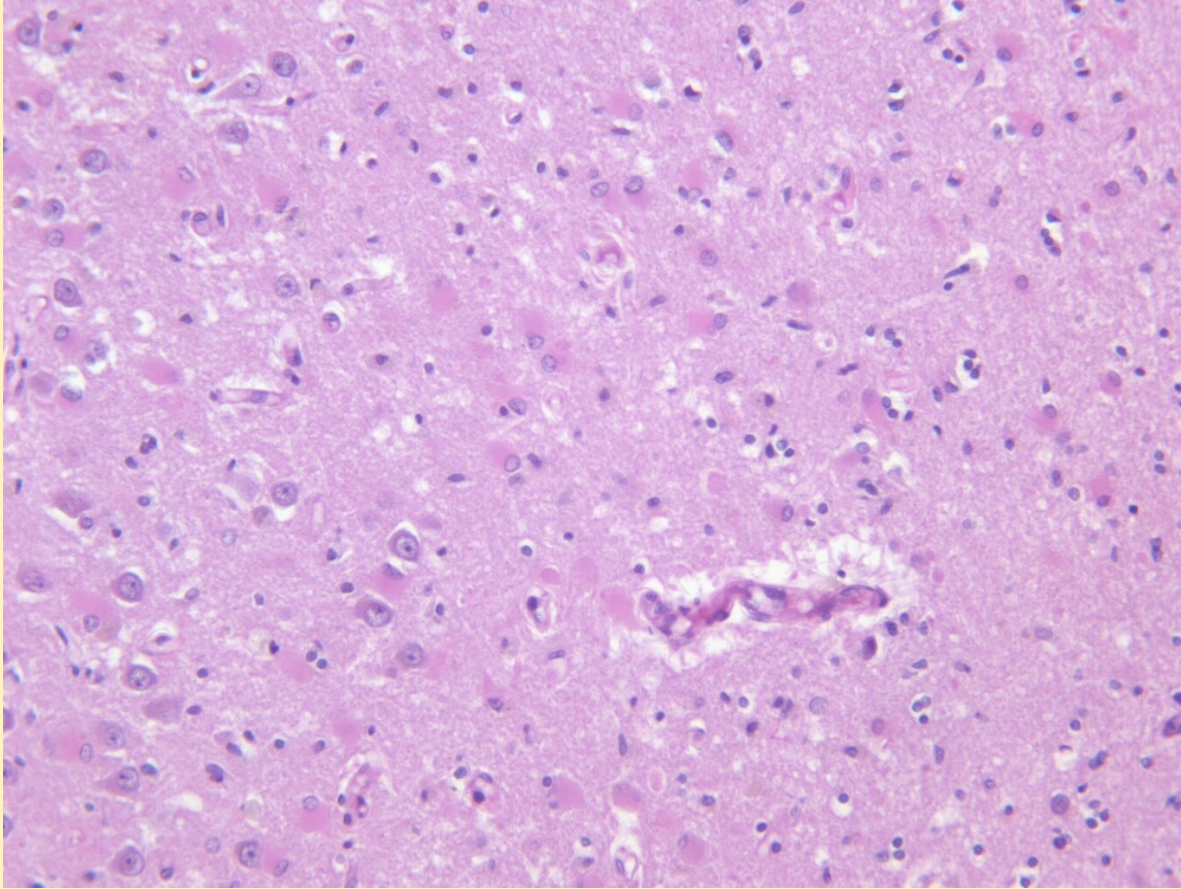
Autopsy findings

Neuropathology

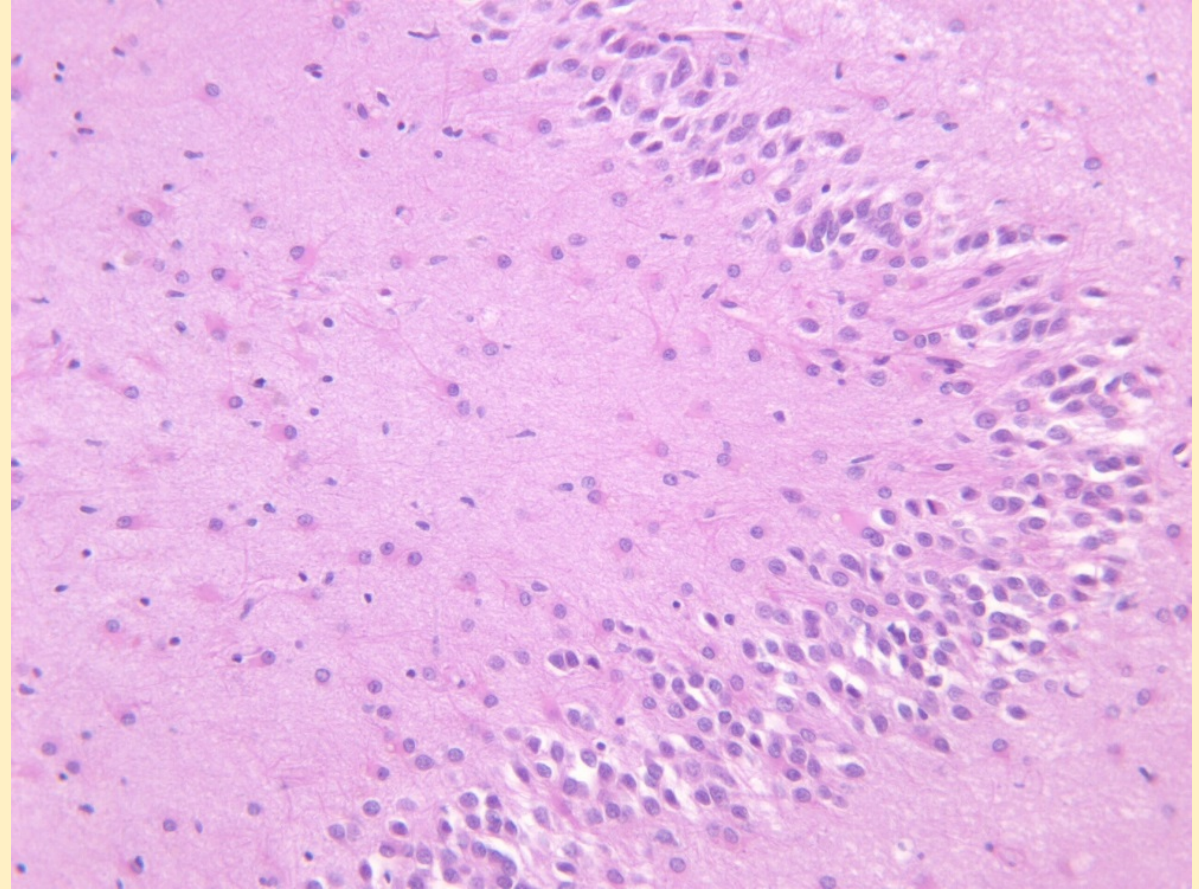
- Brain weight: 1530 g (ref 1100-1700 g)
- Moderately dilated ventricular system bilaterally
- Remote lacunar infarct, 3 mm, right putamen
- Atherosclerosis, multifocal, non-occlusive, circle of Willis and branches

Hippocampus

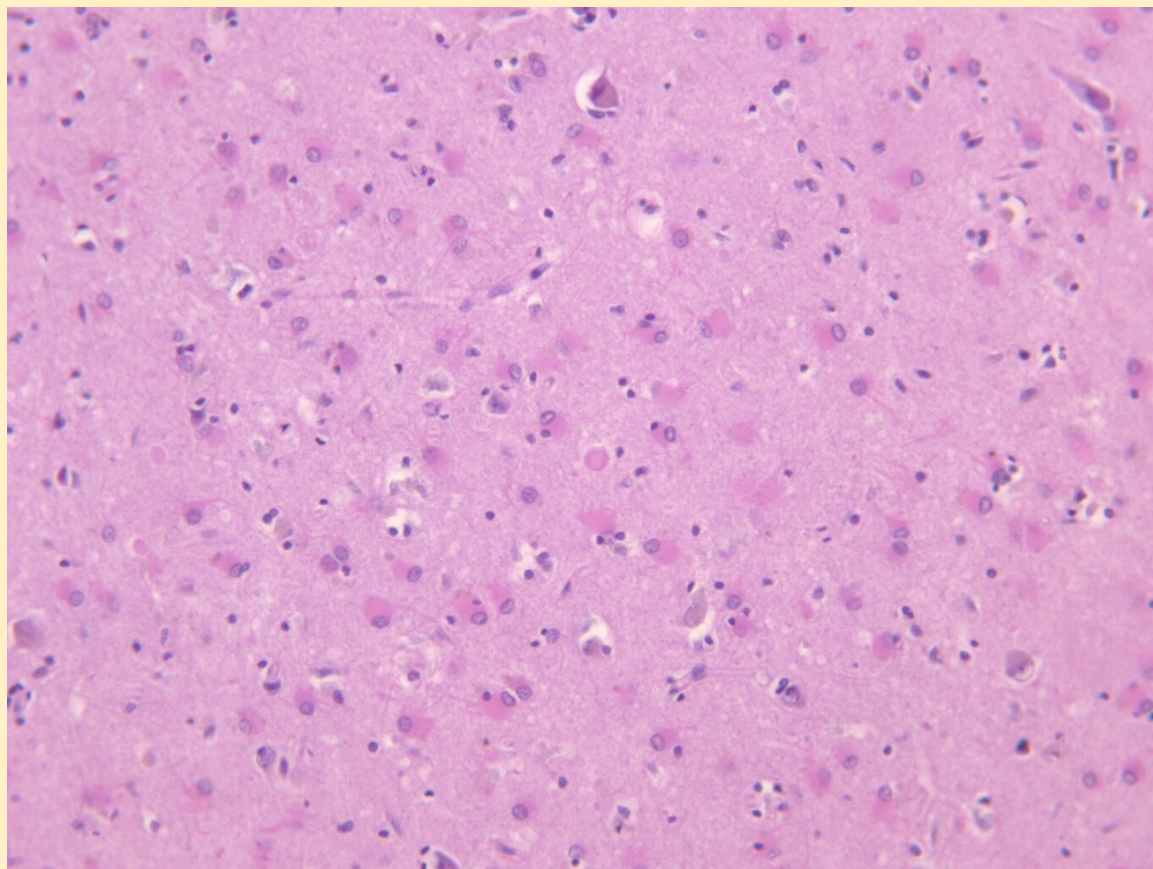
CA1



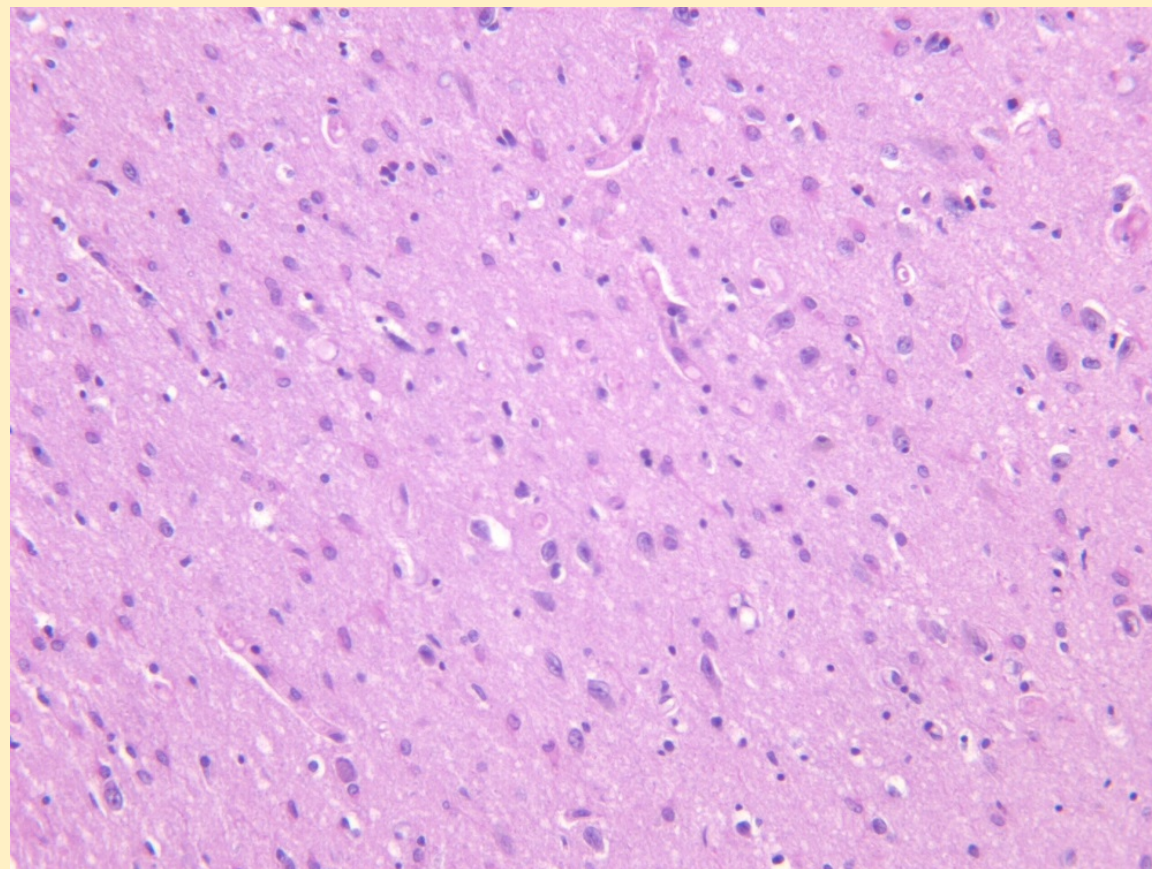
CA4



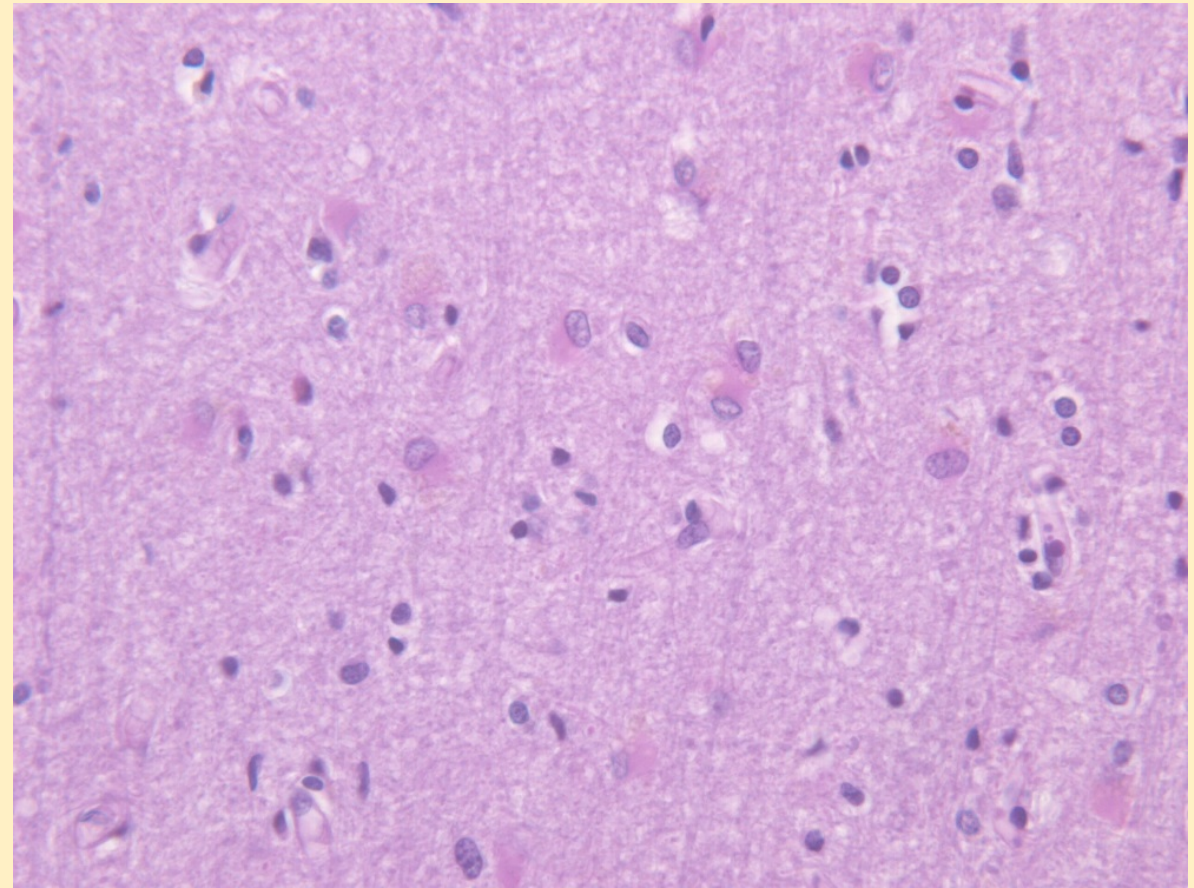
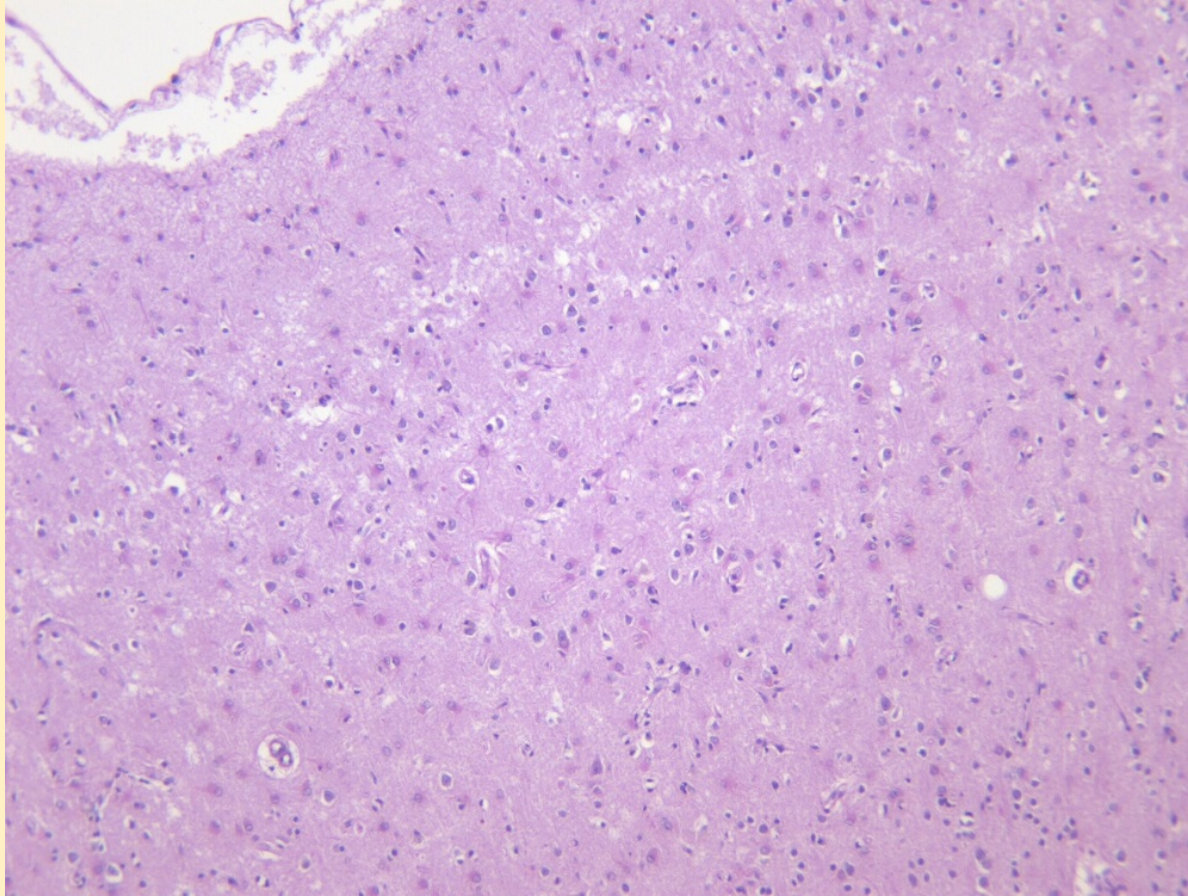
Amygdala



Caudate



Parietal cortex



Neuropathology

- No active inflammation or viral inclusions
- Watershed areas, Purkinje cells not involved

Discussion

Lumbar puncture results

- CSF HHV6 PCR (6/2014) **positive**: 107240 copies/mL
- Treated with ganciclovir and foscarnet
- CSF HHV6 PCR (7/2014) **negative**: <500 copies/mL

Additional testing

- Unstained sections of formalin fixed paraffin-embedded brain tissue sent to the CDC
- HHV6 A and B PCR: negative

Diagnosis

- *Consistent with HHV-6 post-infectious sequelae*
- Hypoxic/ischemic change

Post-transplant acute limbic encephalitis (PALE)

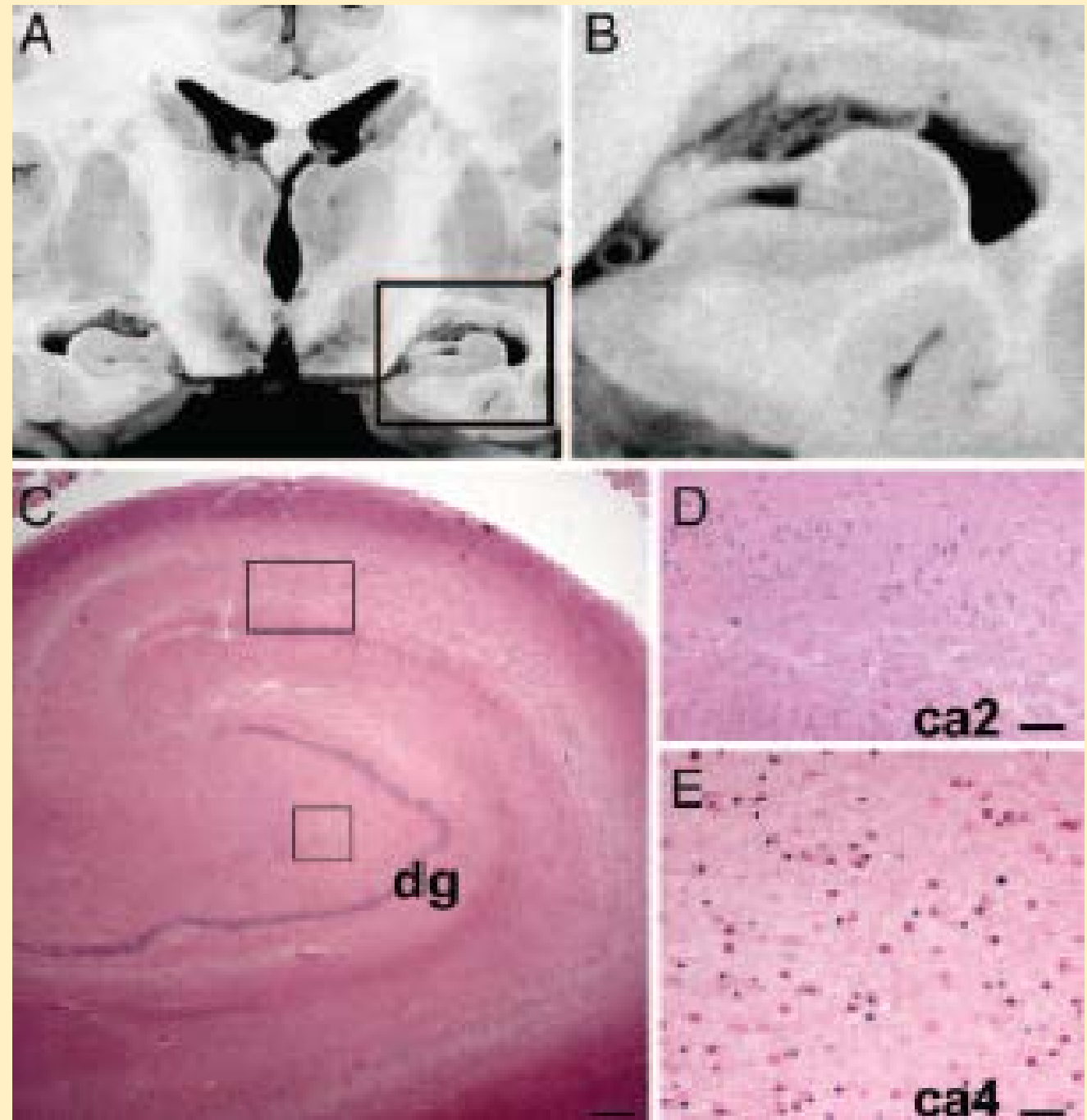
- Allogeneic hematopoietic stem cell transplantation (HSCT)
- 15-60 days post HSCT
- Clinical features:
 - Marked anterograde amnesia
 - Seizures or EEG abnormalities
 - Syndrome of inappropriate antidiuretic hormone (SIADH)
- All ages
- Men more vulnerable than women
- Mild CSF pleocytosis
- Bilateral T2/FLAIR hyperintensities within uncus, amygdala, and hippocampus, extending into the subiculum and entorhinal cortex

Is PALE caused by HHV-6?

- CSF PCR detected HHV-6 in majority of cases
- Negative cases due to:
 - less sensitive assay
 - undetectable levels in CSF but detected in postmortem brain

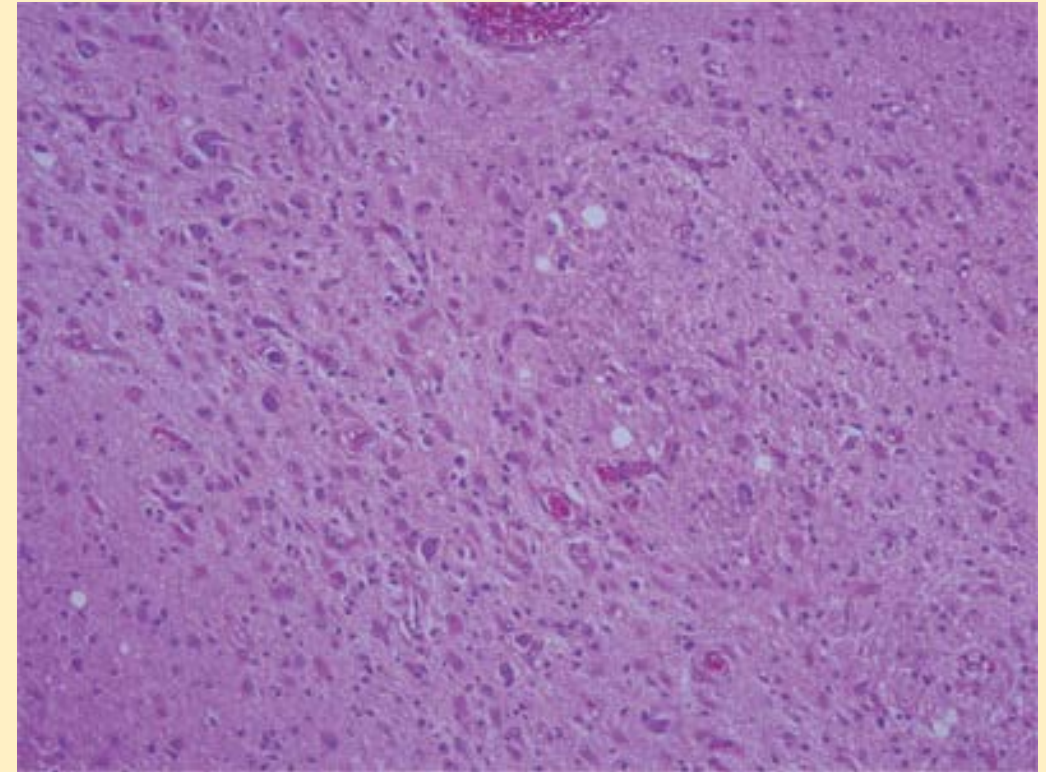
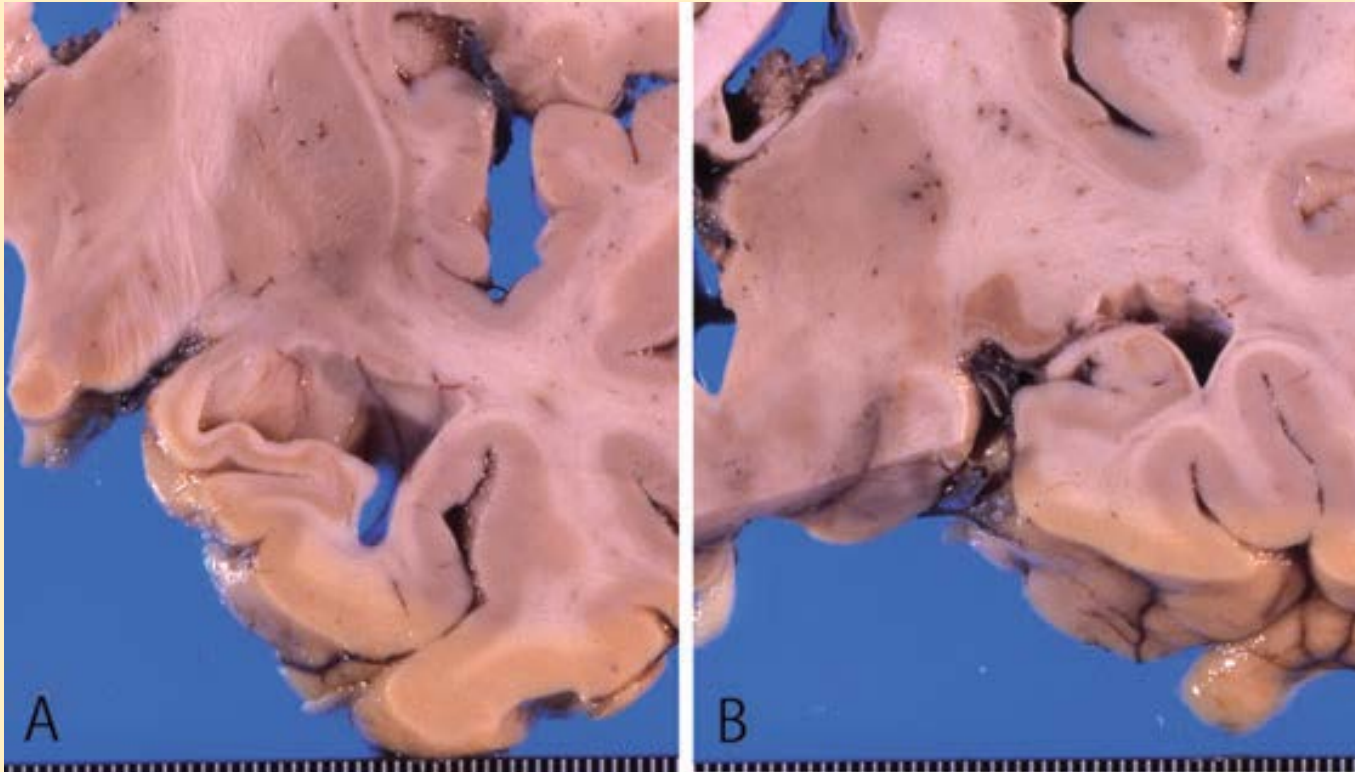
Neuropathology

Hippocampus



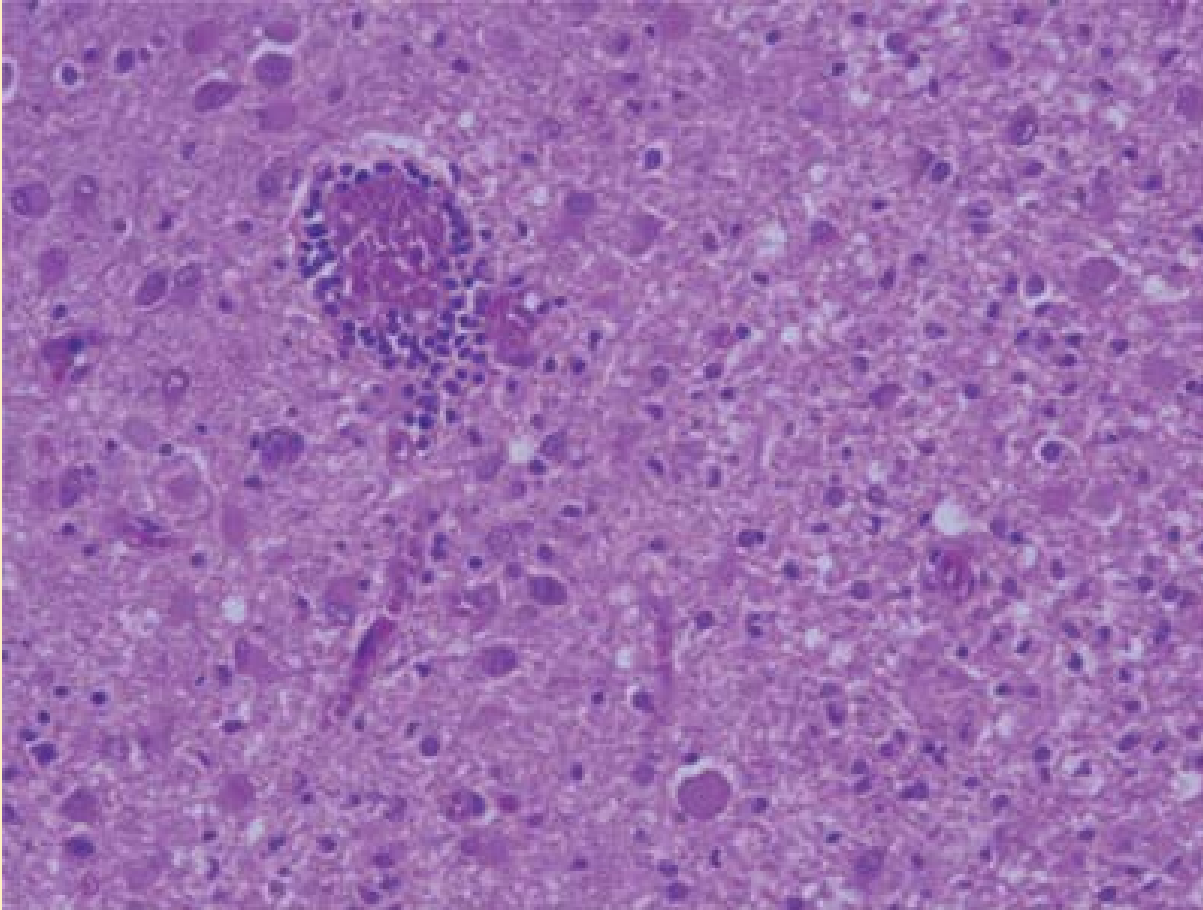
Neuropathology

Hippocampus

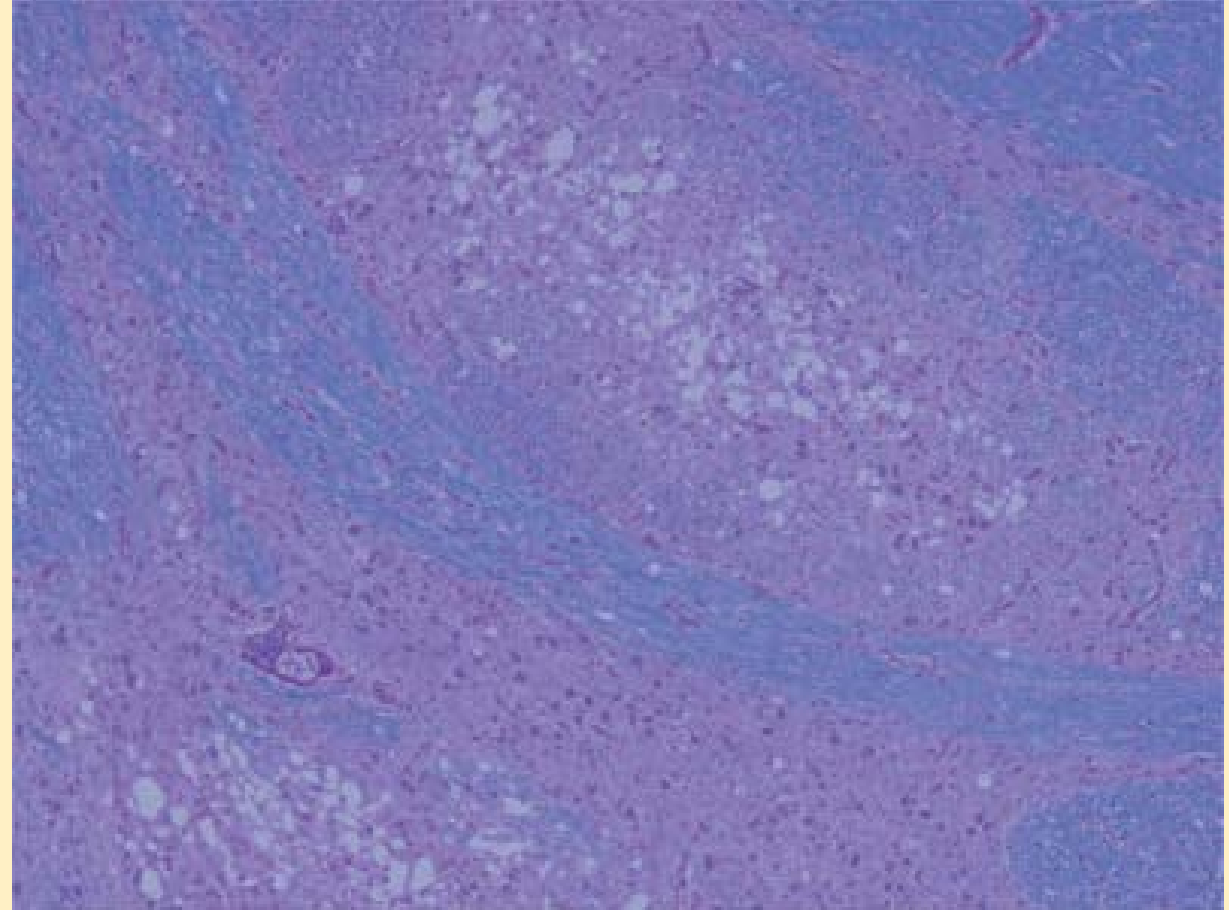


Neuropathology

Clastrum

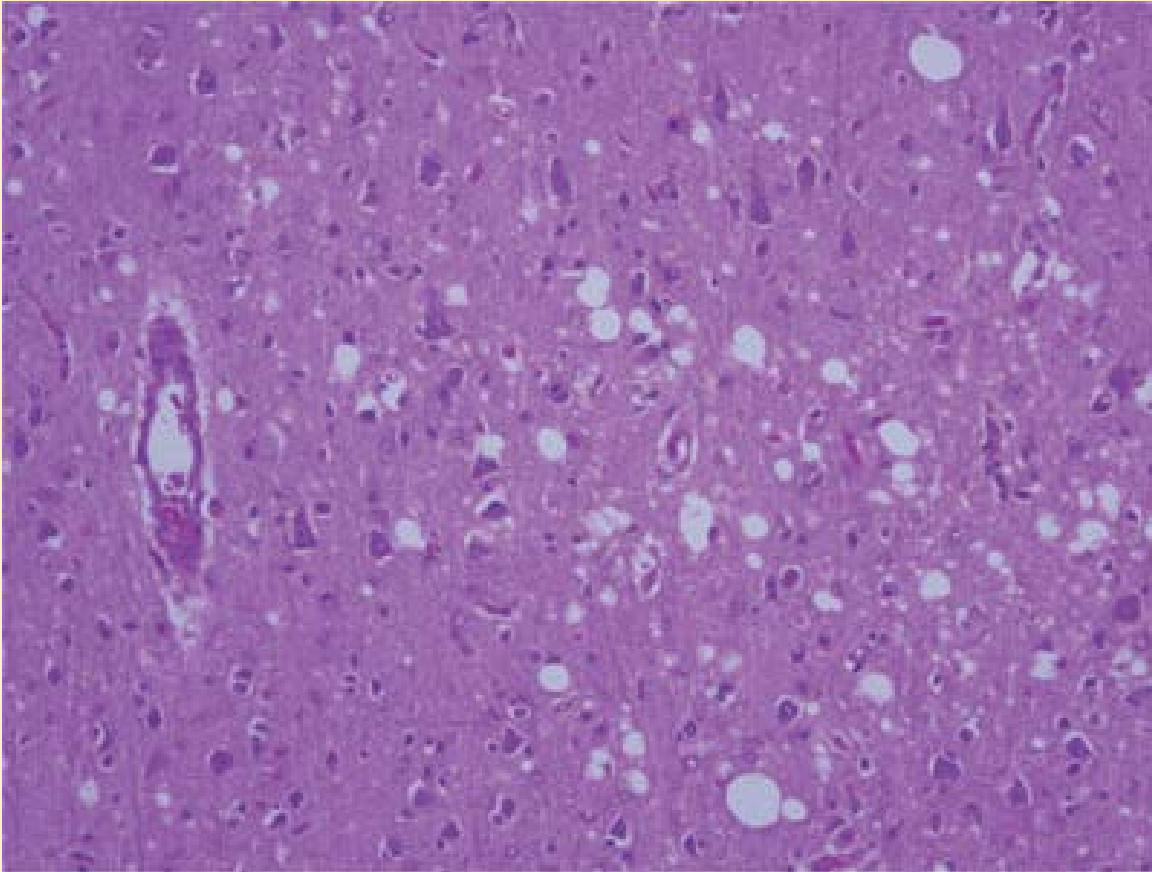


Basis pontis

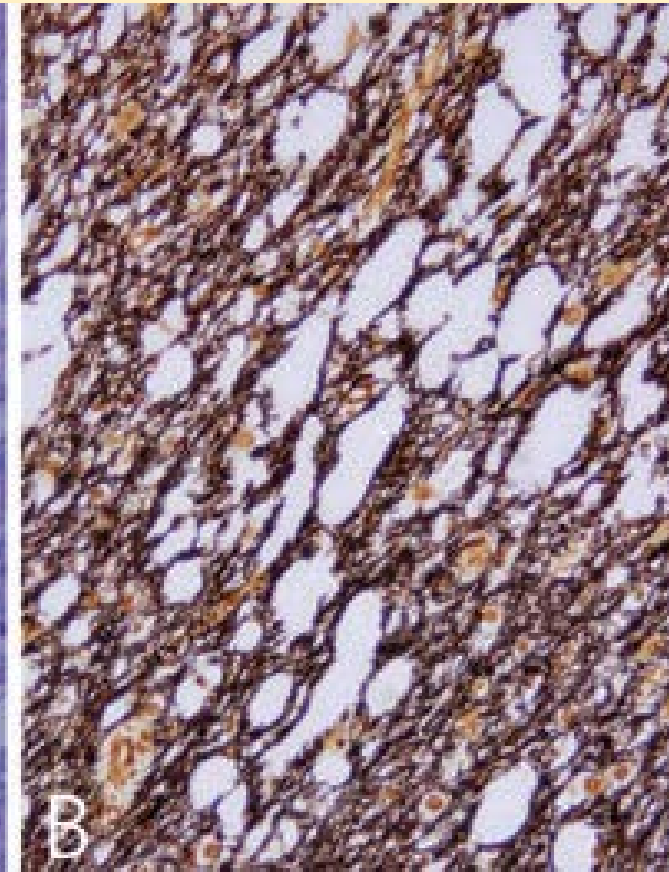
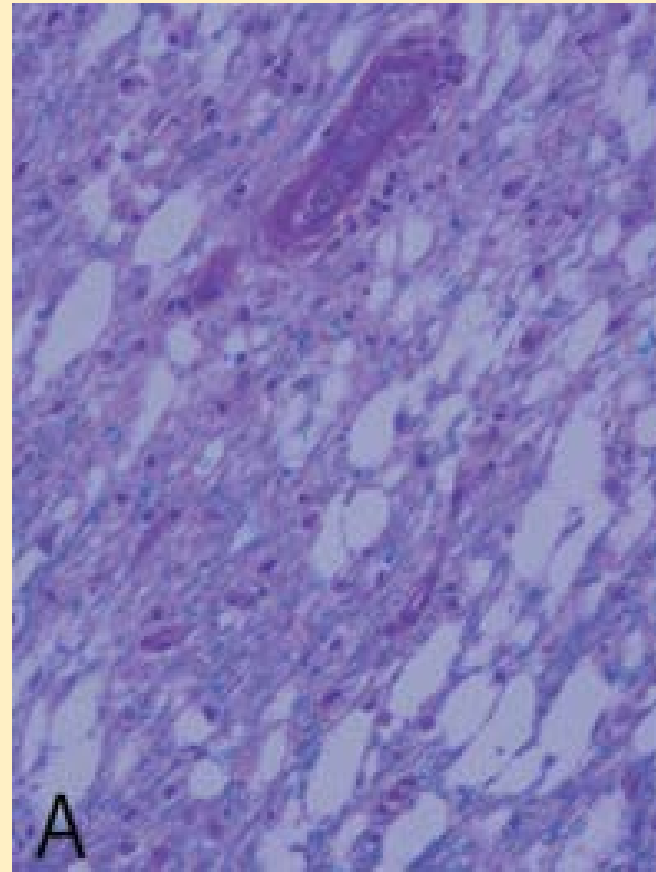


Neuropathology

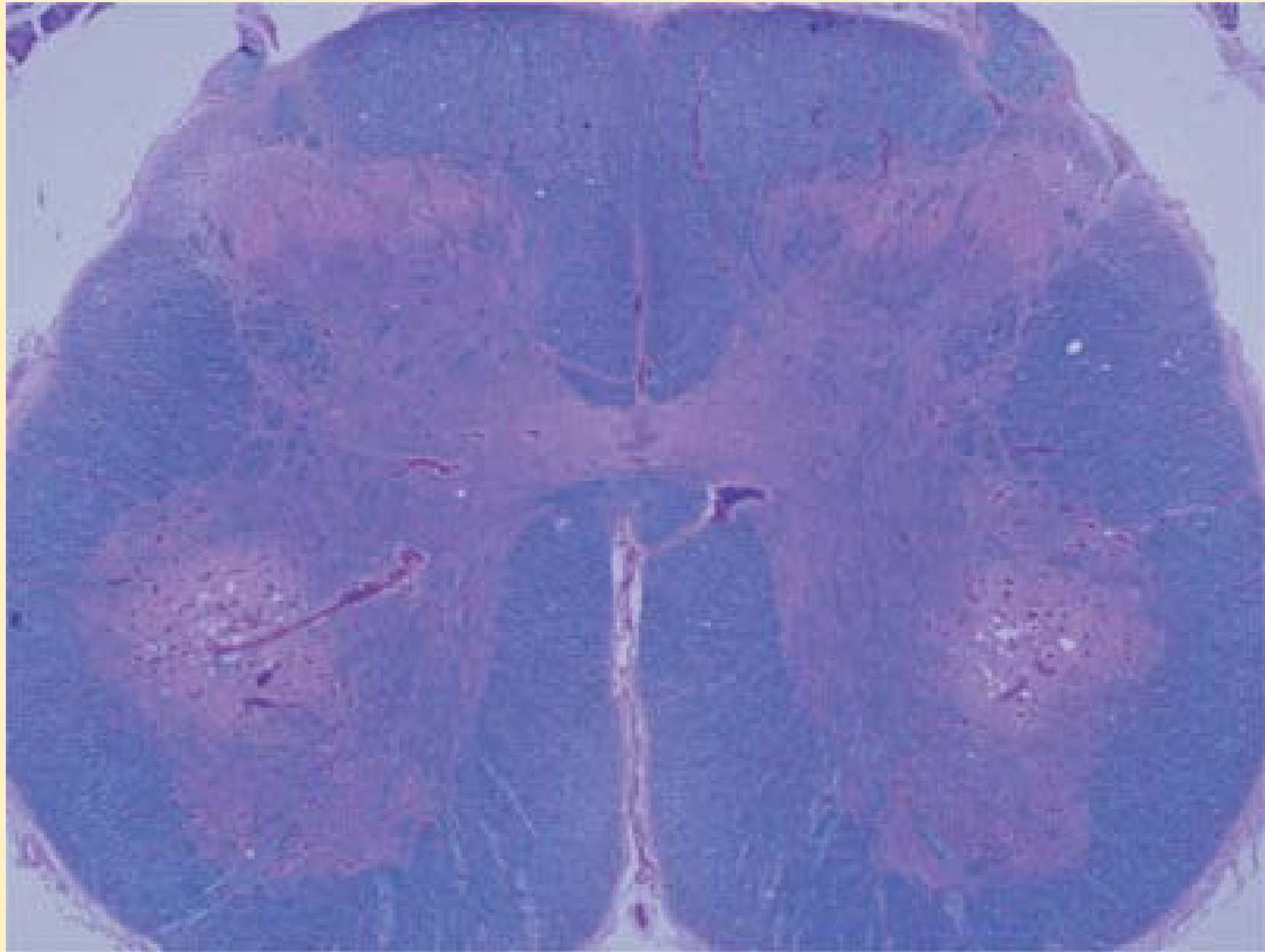
Frontal lobe



Cerebellum



Neuropathology
Lumbar spinal cord



Correlation between PCR in brain and CSF

- HHV-6 levels in CSF before death undetectable by quantitative PCR, positive by nested PCR
- HHV-6 DNA identified in brain, but not all regions
- Hippocampus consistently involved

References

- Seeley et al. Post-transplant acute limbic encephalitis Clinical features and relationship to HHV6. *Neurology*. 2007 Jul 10;69(2):156-65.
- Shintaku et al. Human herpes virus 6 encephalomyelitis after bone marrow transplantation: Report of an autopsy case. *Neuropathology*. 2010 Feb 1;30(1):50-5. doi: 10.1111/j.1440-1789.2009.01020.x. Epub 2009 Apr 26
- Fotheringham et al. Detection of active human herpesvirus-6 infection in the brain: Correlation with polymerase chain reaction detection in cerebrospinal fluid. *J Infect Dis*. 2007 Feb 1;195(3):450-4. Epub 2006 Dec 27
- Drobyski et al. Brief Report: Fatal encephalitis due to variant human herpesvirus-6 infection in a bone marrow-transplant recipient. *Engl J Med*. 1994 May 12;330(19):1356-60.

Thank you!

