



University of Colorado

Boulder | Colorado Springs | Denver | Anschutz Medical Campus

Diagnostic Slide Session 2015

Case 5

Seth Lummus, D.O. and B.K. Kleinschmidt-DeMasters, M.D.
University of Colorado, Department of Pathology, Aurora, CO



Estes Park, CO

Disclosures

I have none

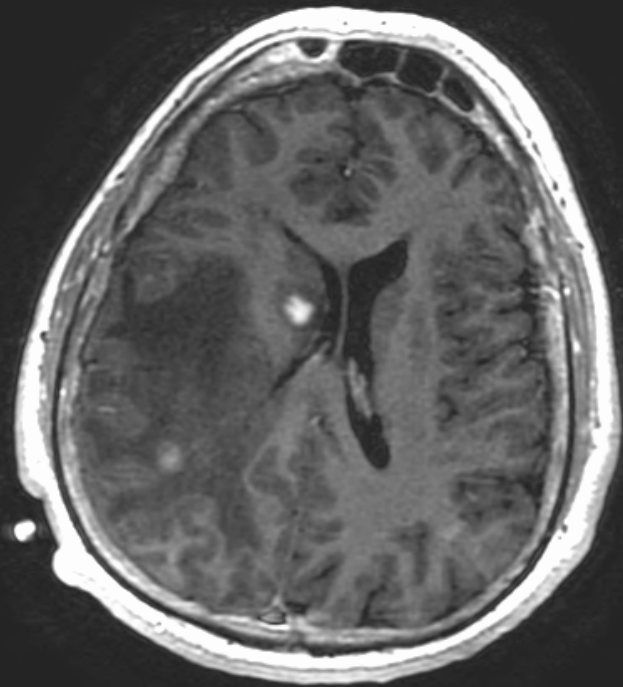
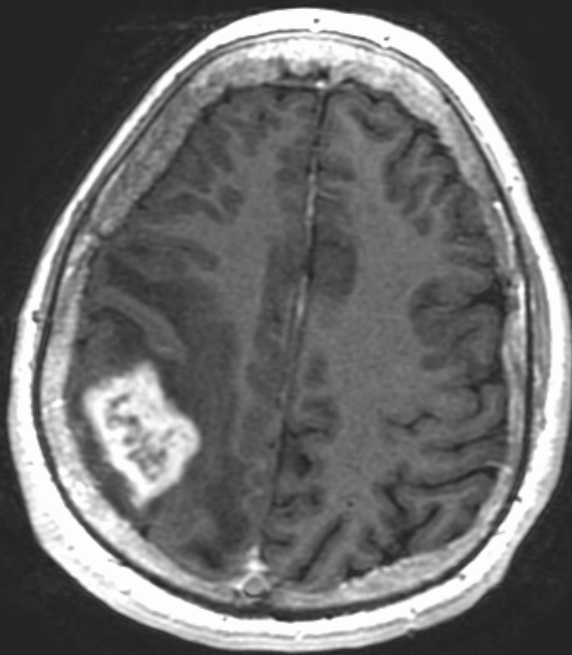


Steamboat Springs, CO

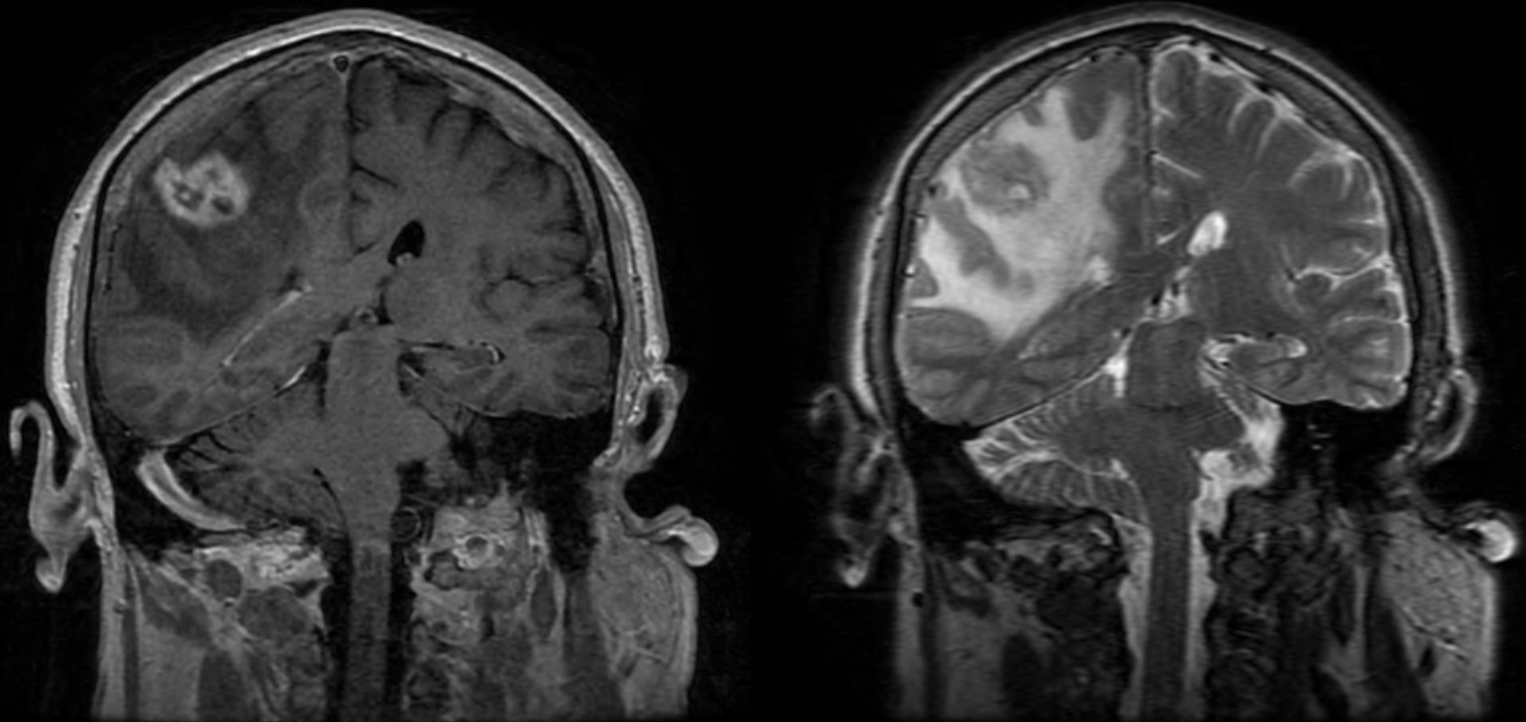
Clinical history

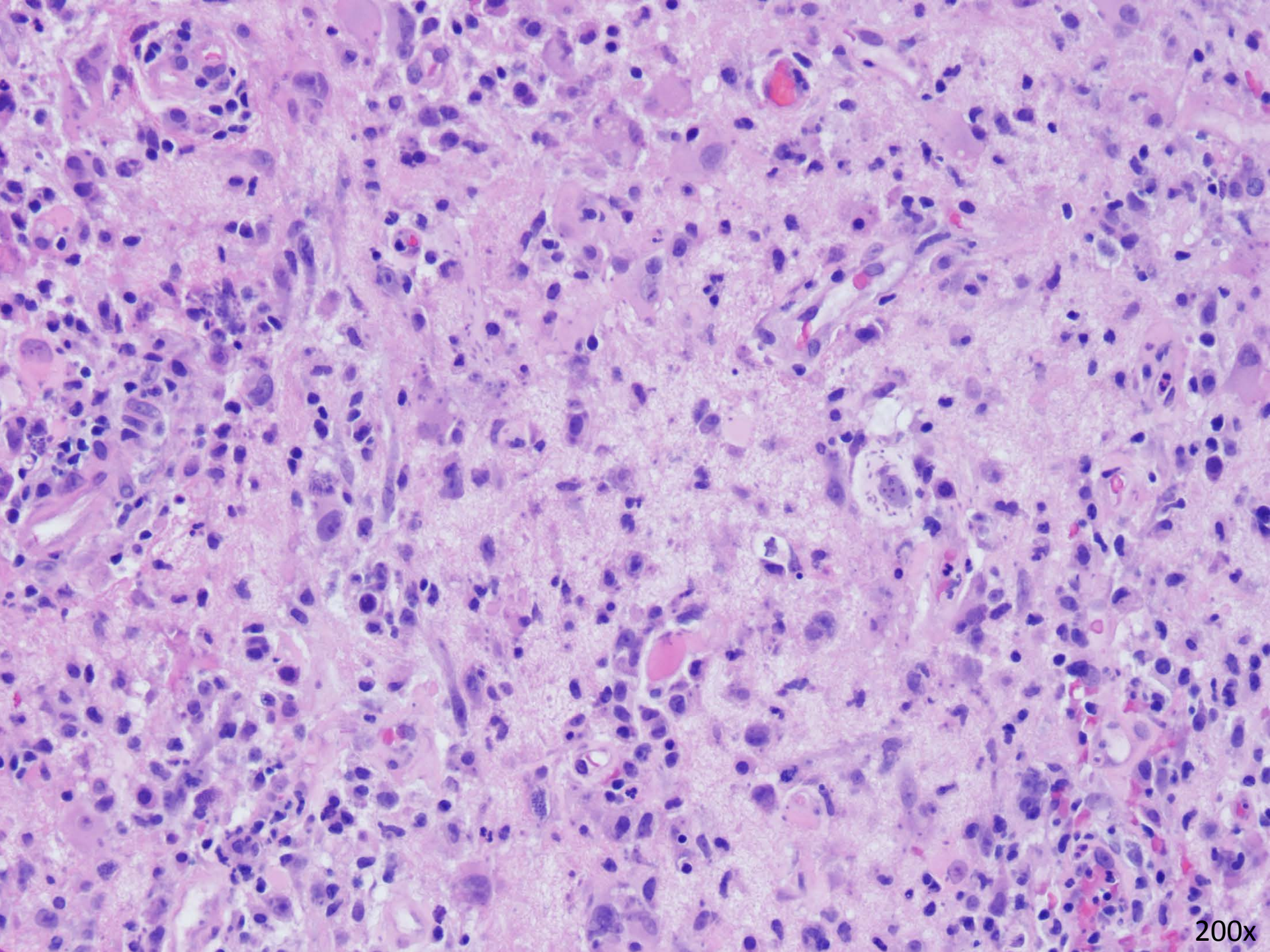
- 54 year-old Caucasian male on chronic immunosuppression (prednisone for 10 years) status post renal transplant for IgA nephropathy
- Develops progressive left sided weakness over 5-6 weeks and severe headaches
- He has no relevant travel history, no exotic pets, and lives in a rural area

T1 FLAIR Axial post gadolinium

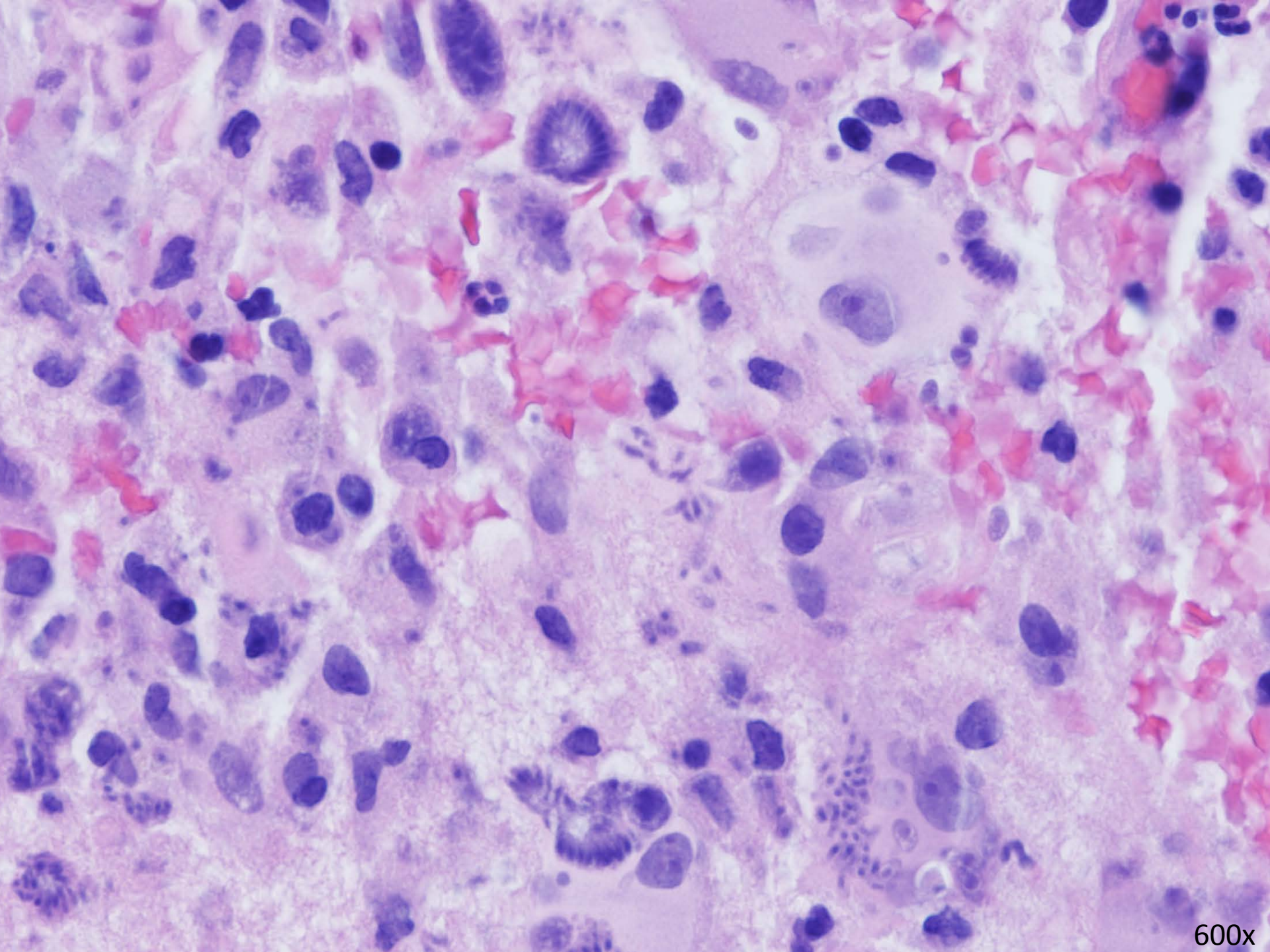


FLAIR Coronal post gadolinium

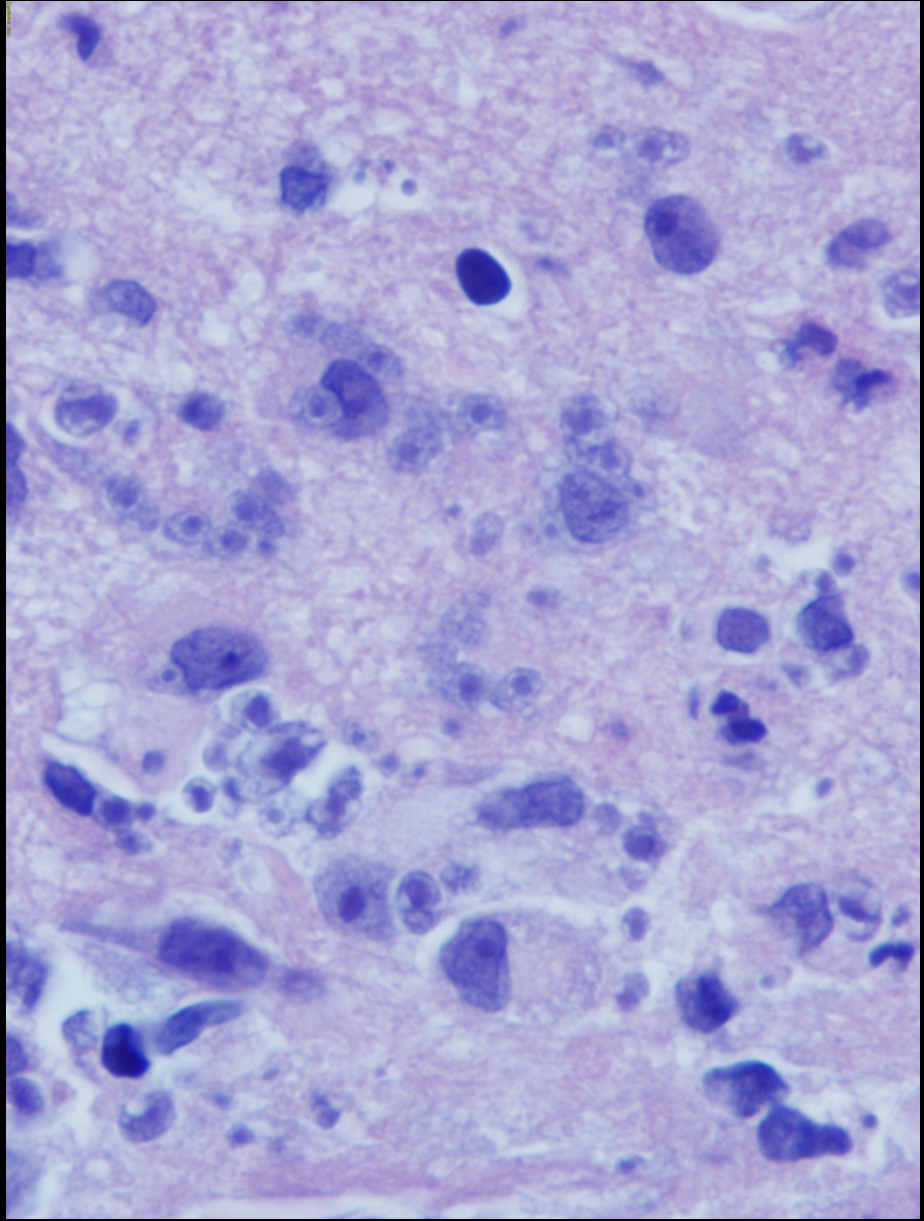
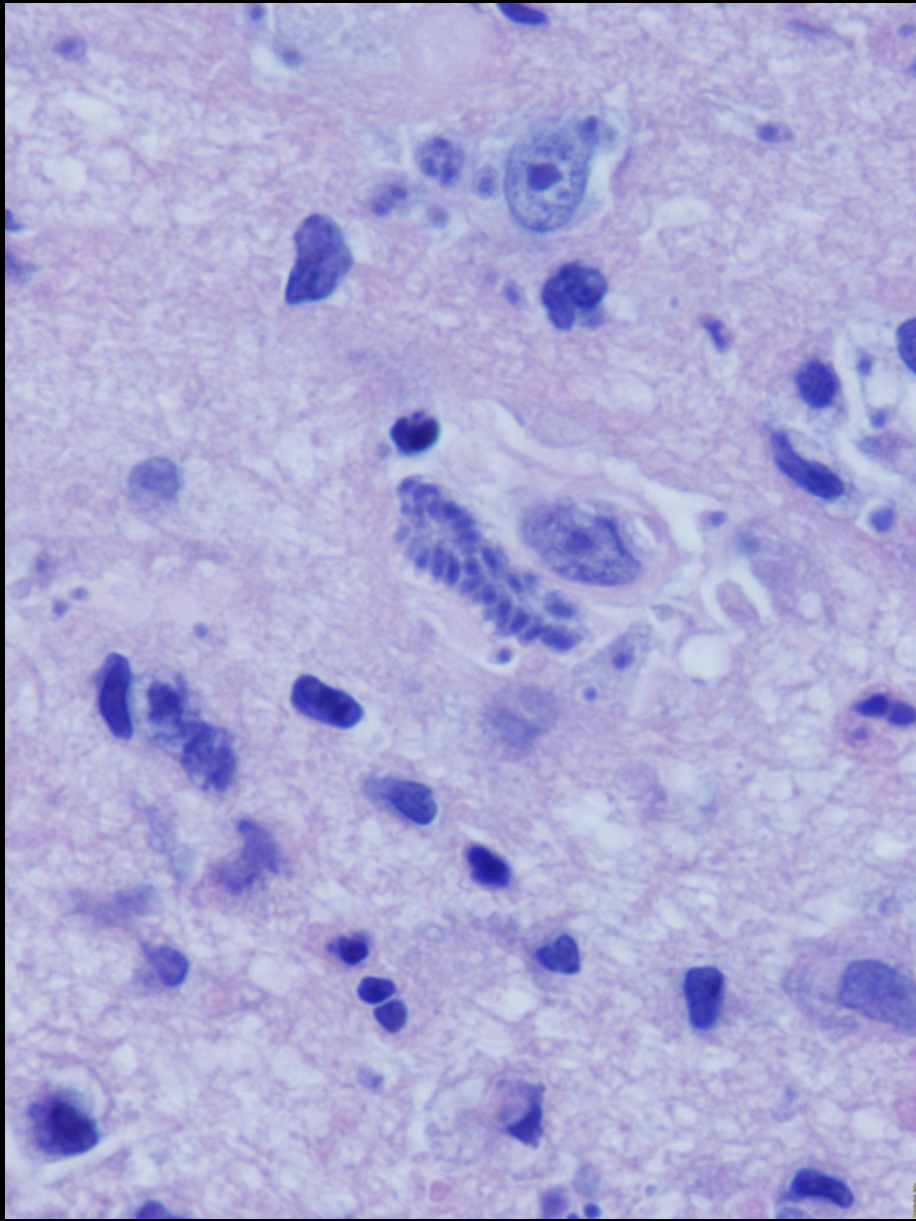




200x



600x



1000x Oil

Key Diagnostic points

- Large and small forms representing oocysts/gametes and parasitic zoites/meronts, respectively
- Crescent shaped forms are 4 x 2 micrometers with small basophilic nuclei
- Fan-like “rosette” formations
- Round forms are 5-7 micrometers in diameter with distinct membranes and central basophilic or magenta nuclei

Differential diagnosis?



Hanging Lake, Glenwood Springs, CO

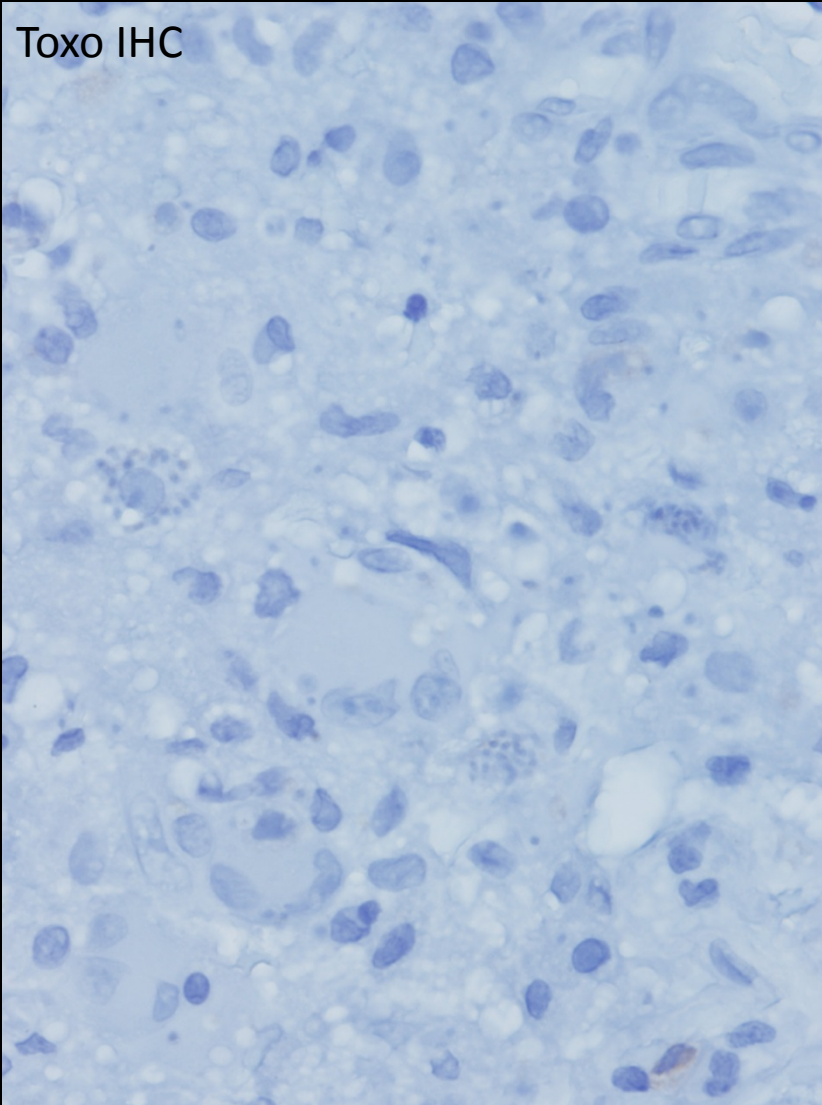
Differential diagnosis?



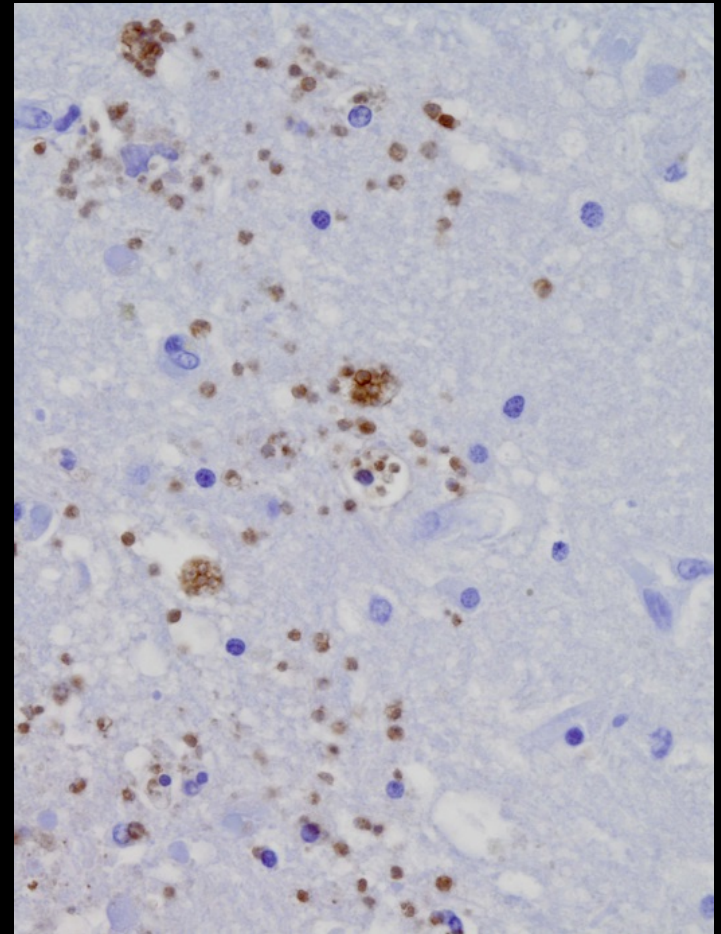
Crater Lake, Rollinsville, CO

Immunohistochemistry

Toxo IHC



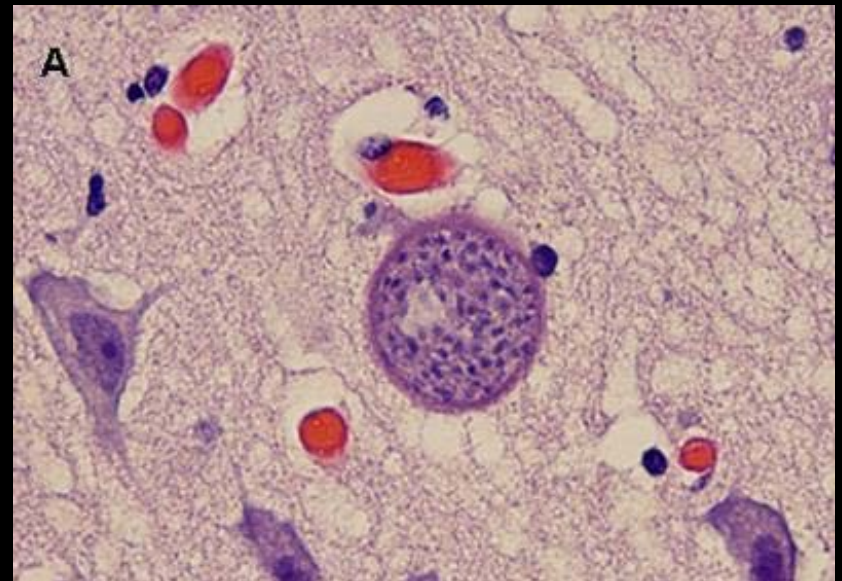
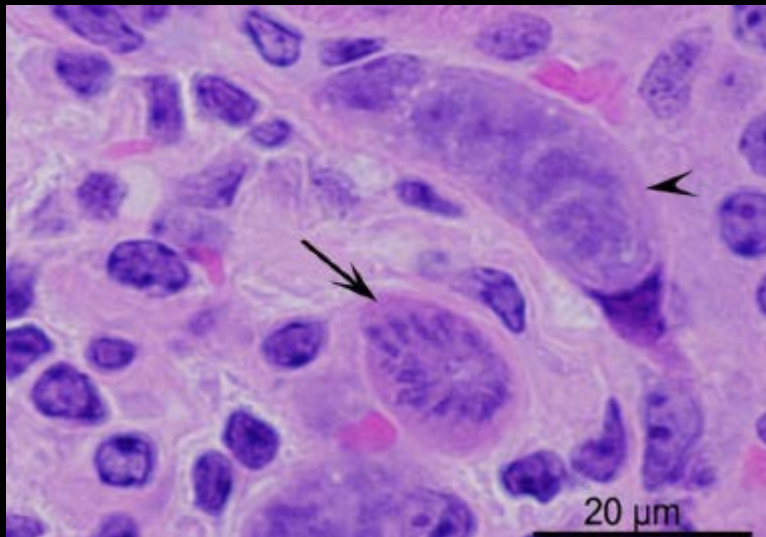
Control toxoplasmosis IHC
For fidelity assurance

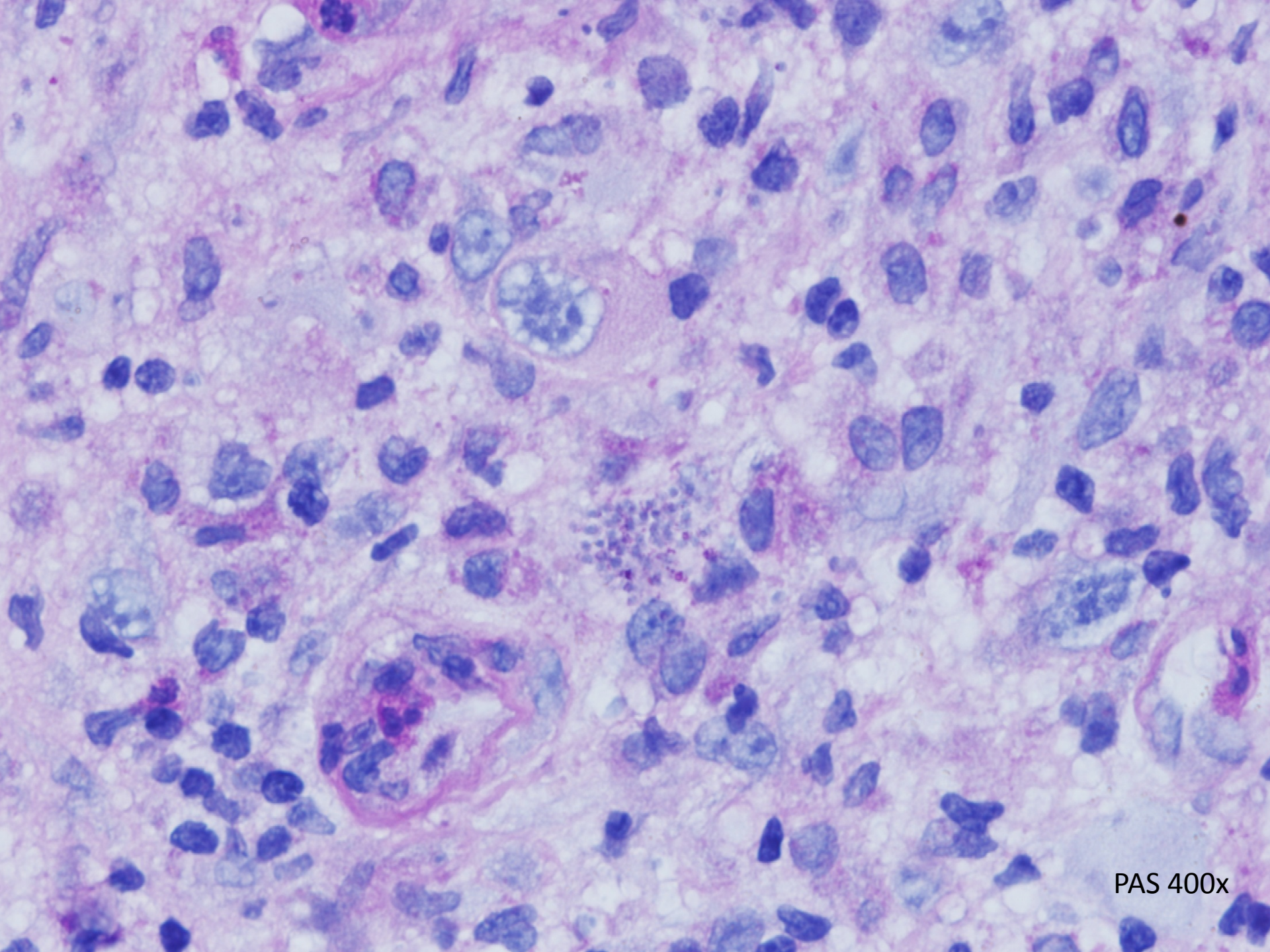


Now...What could it be?

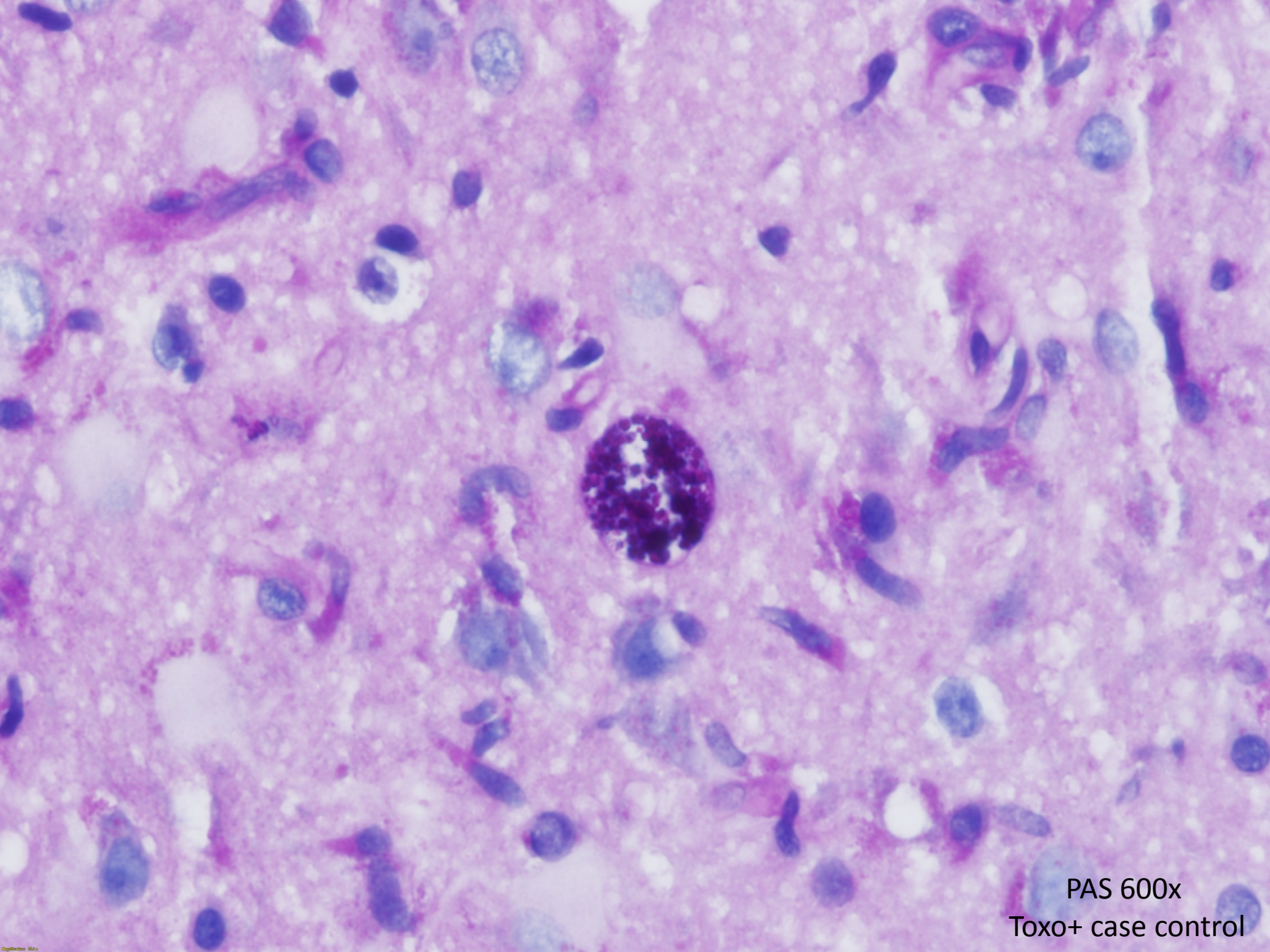
Sarcocystis?

- Larger than Toxo with rounded ends
- Compartmented by septa
- Stores PAS+ material





PAS 400x



PAS 600x
Toxo+ case control

Now what??

- Immunohistochemistry for similar parasitic forms to *Toxoplasmosis gondii* are not available
- Clinicians are interested in determining *which* specific organism we are dealing with because there are drug treatment implications
- Specifically, they feel that infections due to toxoplasmosis, but not sarcocystis, respond to standard drug regimen
- Sarcocystis infections will require different therapeutic agents

Action taken

- Slides and block submitted to the Centers for Disease Control for morphological review and further testing
- They concur that this is not toxoplasmosis and probably not sarcocystis but unsure of specific organism

PCR at the CDC

Negative PCR results for:

- *Encephalitozoon cuniculi*
- *Toxoplasma gondii*
- *Pneumocystis jirovecii*
- Polyfungal



Berthoud Pass, CO

Sequencing at the CDC

- Illumina MiSeq and HiSeq whole genome sequencing revealed sequences consistent with an Apicomplexan parasite
- But...the specific genome did not match any known genus or species through bioinformatic analysis
- Genetic elements similar to *Neospora caninum*, *Toxoplasma gondii*, and *Hammondia heydorni*

Diagnosis

Apicomplexan protozoal encephalitis – specific species unclassifiable by molecular methods



San Juan Mountains, CO

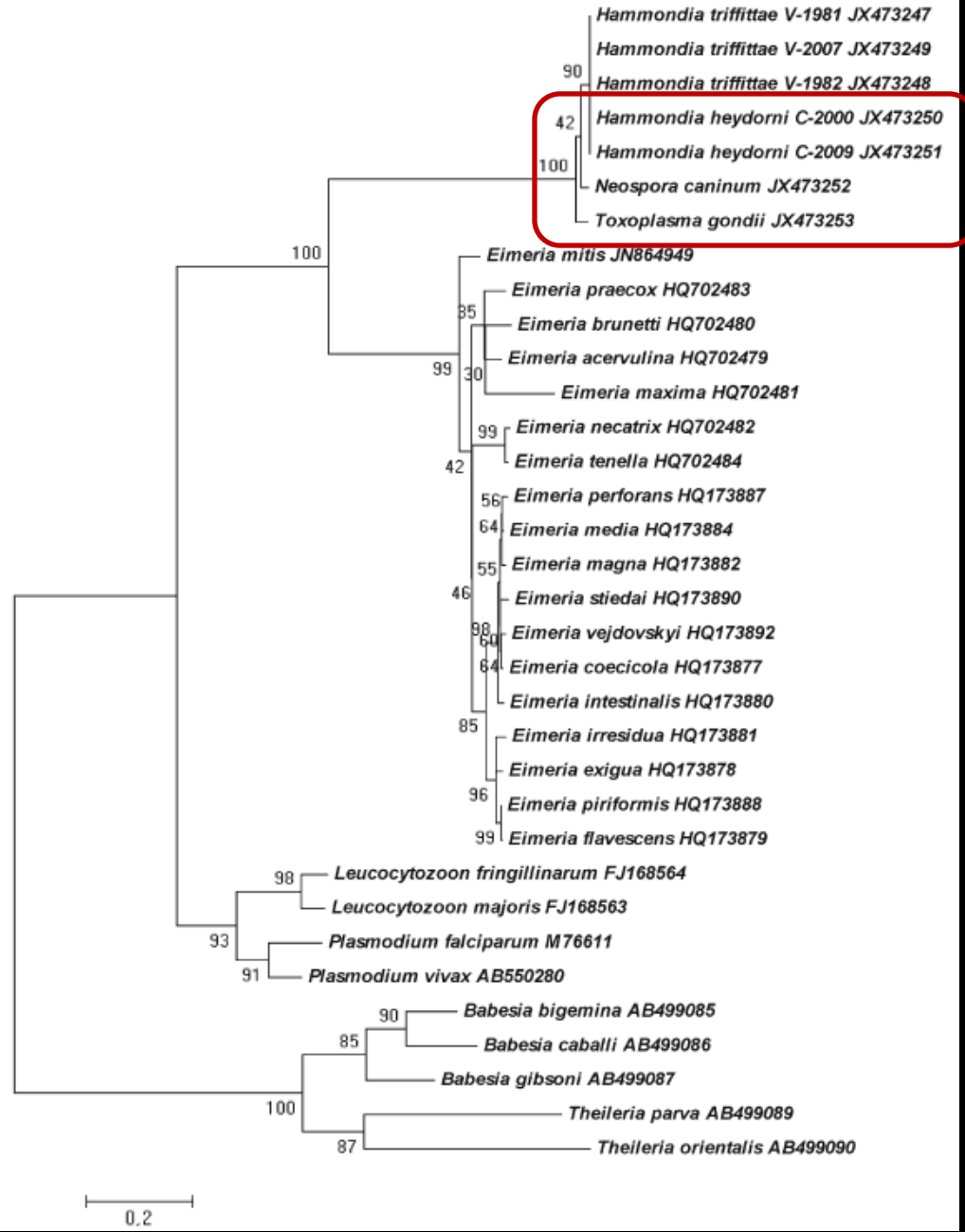
Discussion

Apicomplexan parasites contain an apical set of complex organelles that assist with host invasion.



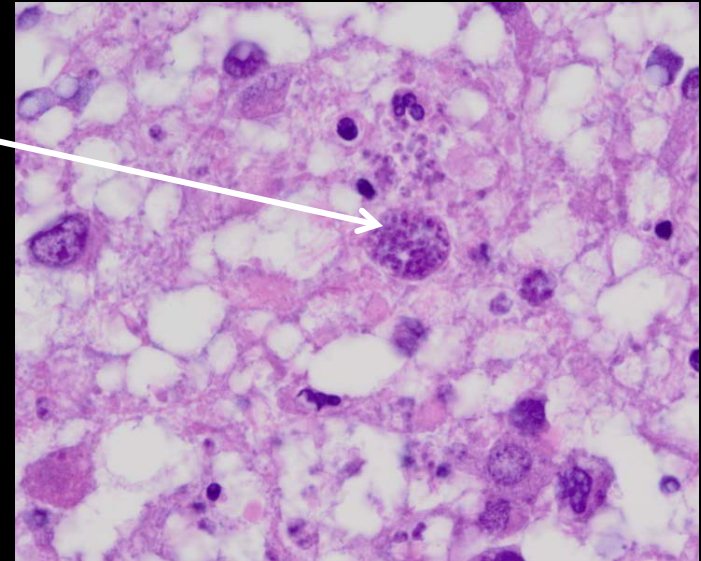
Mount Princeton Summit, Buena Vista, CO

Fig. 2 Phylogenetic relationships among the Toxoplasmatinae and other apicomplexan taxa as inferred from *cytb* sequences using the maximum likelihood method based on the Tamura-Nei (+G) model. The percentage of replicate trees in which the associated taxa clustered together in the bootstrap test (1,000 replicates) is shown next to the branches. The tree is drawn to scale, with branch lengths measured in the number of substitutions per site. The analysis involved 34 nucleotide sequences. All positions containing gaps and missing data were eliminated. There were a total of 1,065 positions in the final data set. The GenBank accession number of each sequence is given behind the taxon name



Why is this *not* Toxo?

- No Bradyzoites
- Toxo IHC has high fidelity
- Toxo oocysts are 10-12 microns, and this case had 5 -7 micron gamete/oocysts*
- Tachyzoites are crescent and about 4 x 2 microns*
- Toxo is strongly PAS positive*

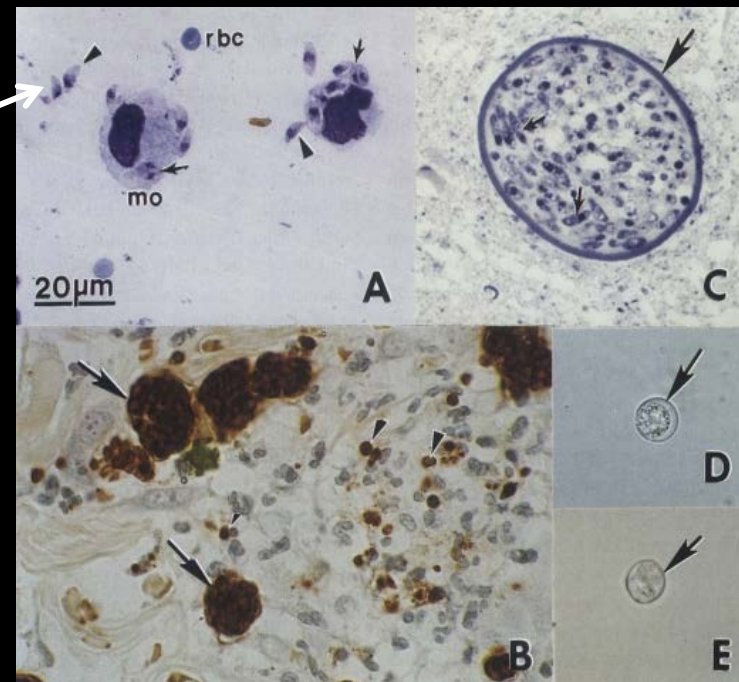
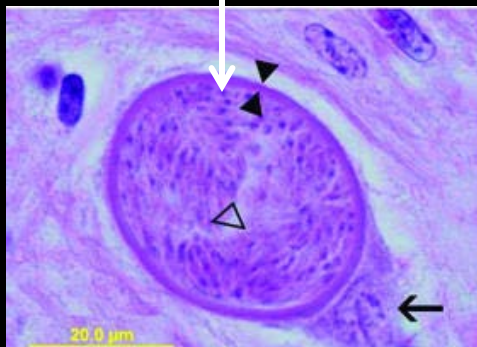


Neospora

Neospora caninum is a major cause of disease in cattle and dogs worldwide, and a cohort of over 3,000 high-risk patients in England showed NO evidence of human exposure¹

Tachyzoites are approximately $6 \times 2 \mu\text{m}$

Tissue cysts are up to $107 \mu\text{m}$




¹Emerging Infectious Diseases. 14 (6), June 2008. www.cdc.gov/eid

²Review of Neospora caninum. Korean J Parasitol. 41(1) March 2003

Hammondia

Hammondia heydorni infects dog-like mammals
Not known to infect humans



Unstained *Hammondia heydorni* tissue cyst in a naturally infected dog

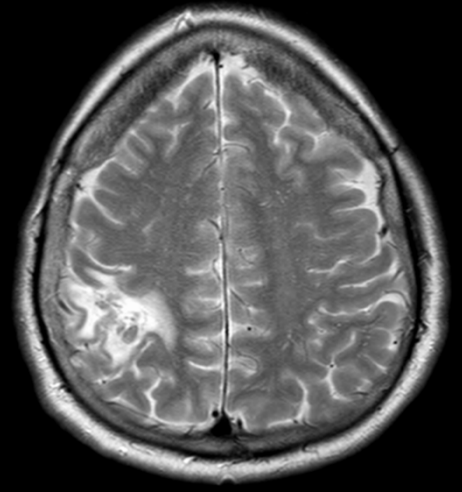
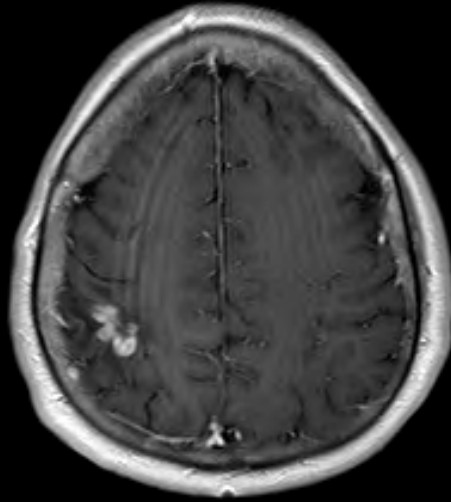
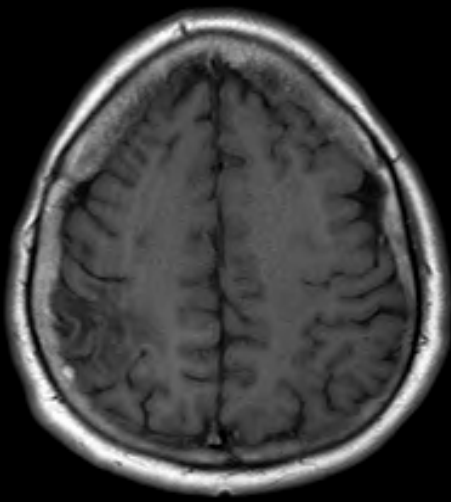
Discussion

- *Neospora caninum*, *Toxoplasma gondii*, and *Hammondia heydorni* are ALL covered with leucovorin, pyrimethamine and sulfadiazine (the “toxoplasma regimen”)
- Sarcocystis infected humans will need amprolium, albendazole, metronidazole and/or cotrimoxazole because the usual “toxoplasma regimen” is not known to work

Follow-up

- The patient was treated with Toxoplasma regimen and sent home with oral leucovorin, pyrimethamine and sulfadiazine one day after the biopsy.
- He has been doing very well with a completely normal neurological exam less than 10 months later

8 month follow-up



Acknowledgments

Drs. Drew, Goldsmith, Muehlenbachs, Ritter, Shieh, and Zaki at the CDC for expert consultation and molecular analysis

Thank you! — and *welcome to Colorado!*



San Juan Mountains, CO



Berthoud Pass, CO