

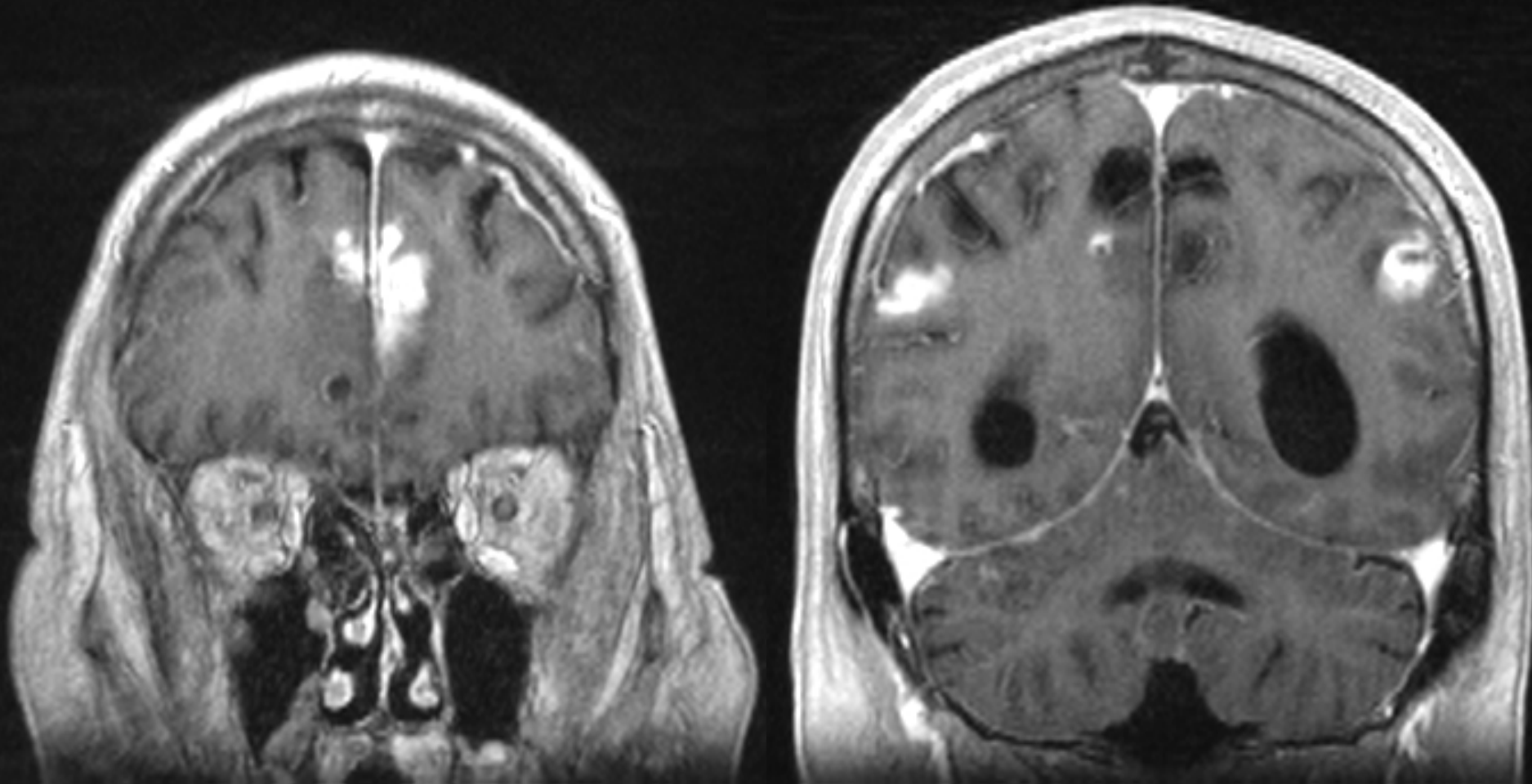
**Case 10**  
**Diagnostic Slide Session, 2015**  
**American Association of Neuropathologists**

Amanda O. Fisher-Hubbard, M.D., Sandra Camelo-Piragua, M.D.,  
Paul McKeever, M.D., Ph.D.

# Clinical History

- 62-year-old man with CAD and HTN presented with 2 week history of decreased appetite, neck/back pain, nausea, vomiting
- Admitted to an outside hospital 1/8/2014
- Suffered tonic-clonic seizure, intubated

**MRI, Outside Hospital**  
**T1-weighted, post-contrast**



# Laboratory Work-up

- **Lumbar puncture**

Protein: 539 mg/dL  
normal = 15–45 mg/dL  
Gram stain/culture:  
Negative

- **Urine Histoplasma Ag**

– Positive  
– Negative on repeat

- **ACE, CSF**

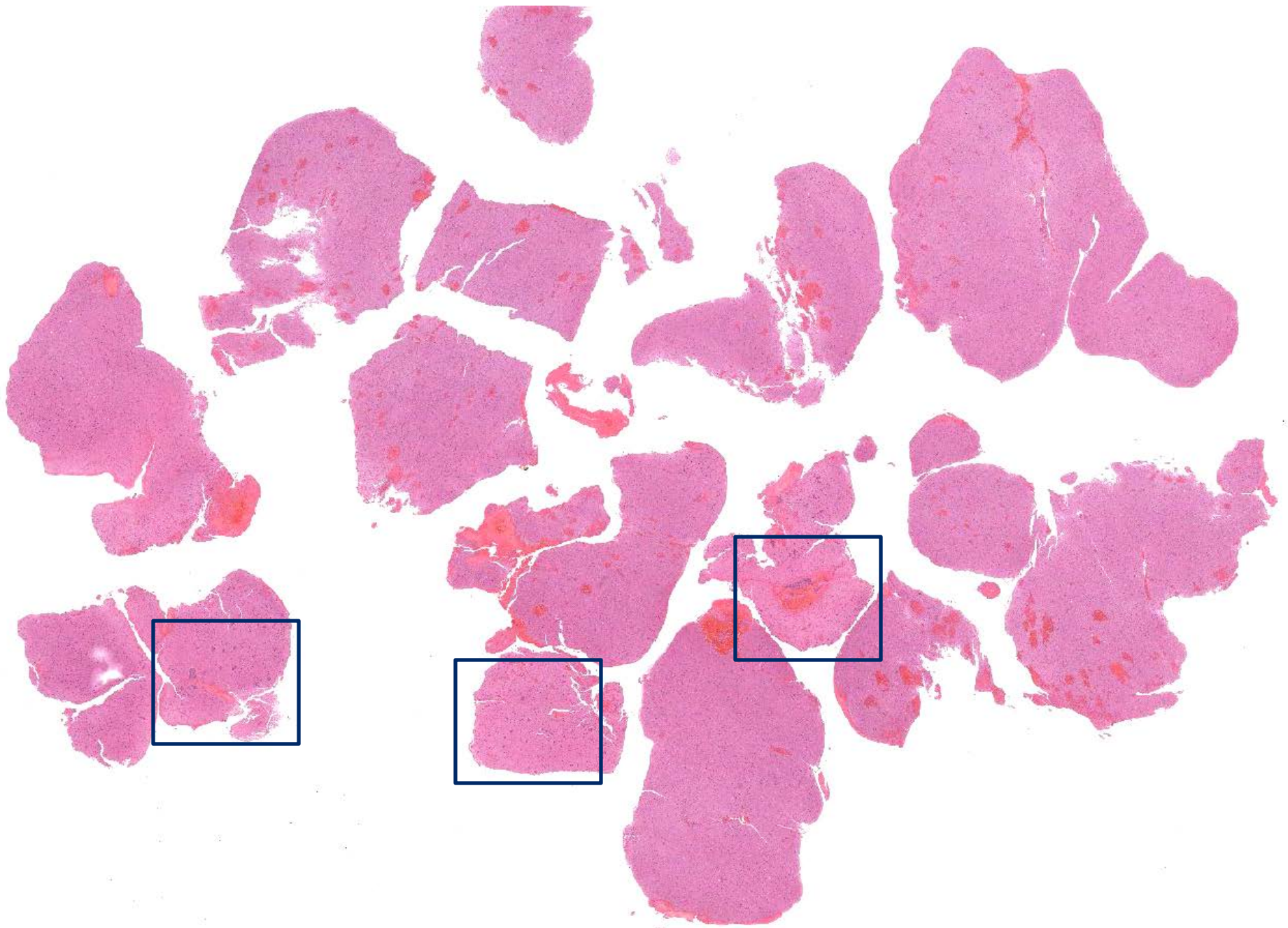
6.4 U/L  
normal = 0.0 – 2.5 U/L

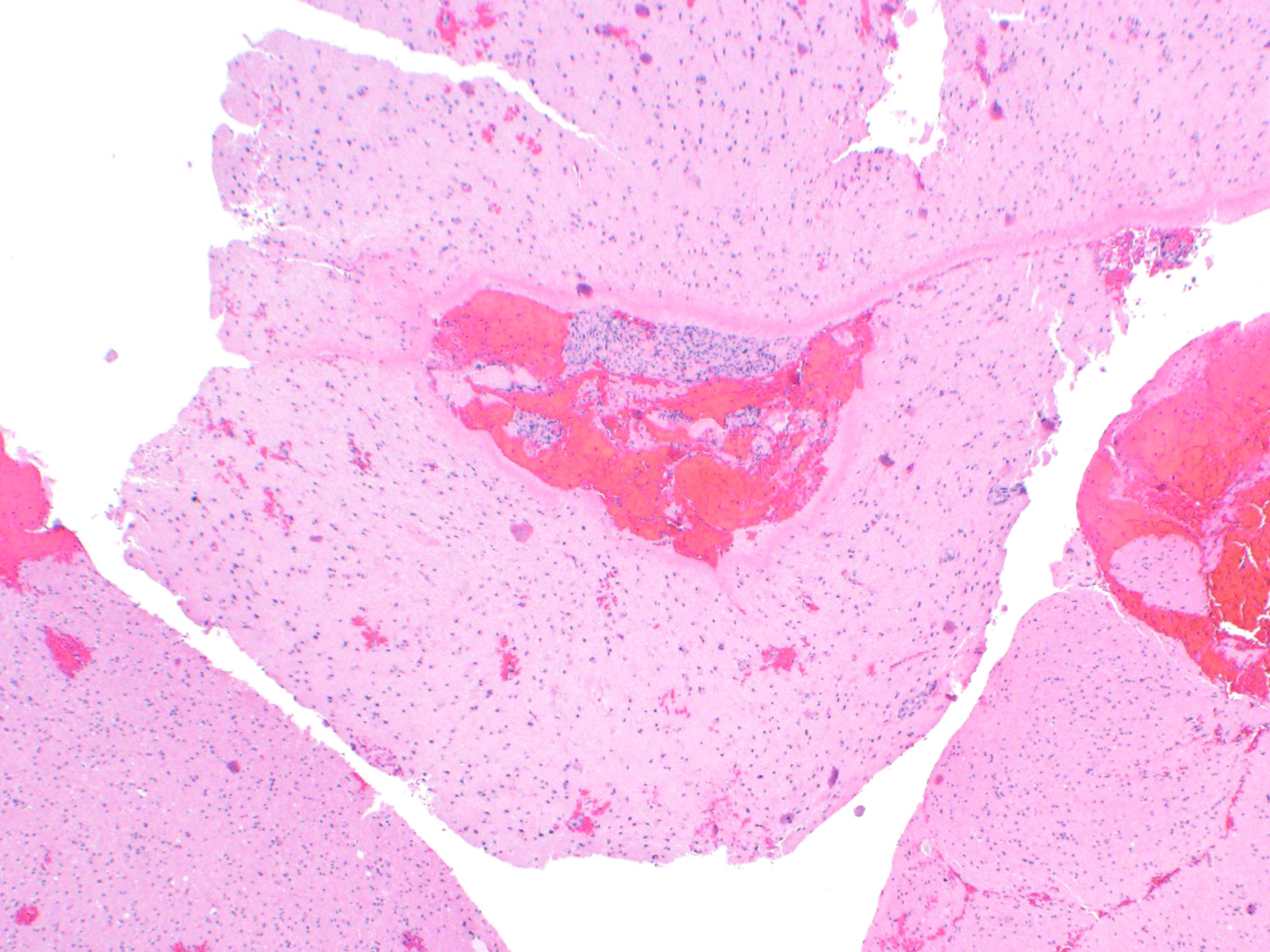
- **Negative tests**

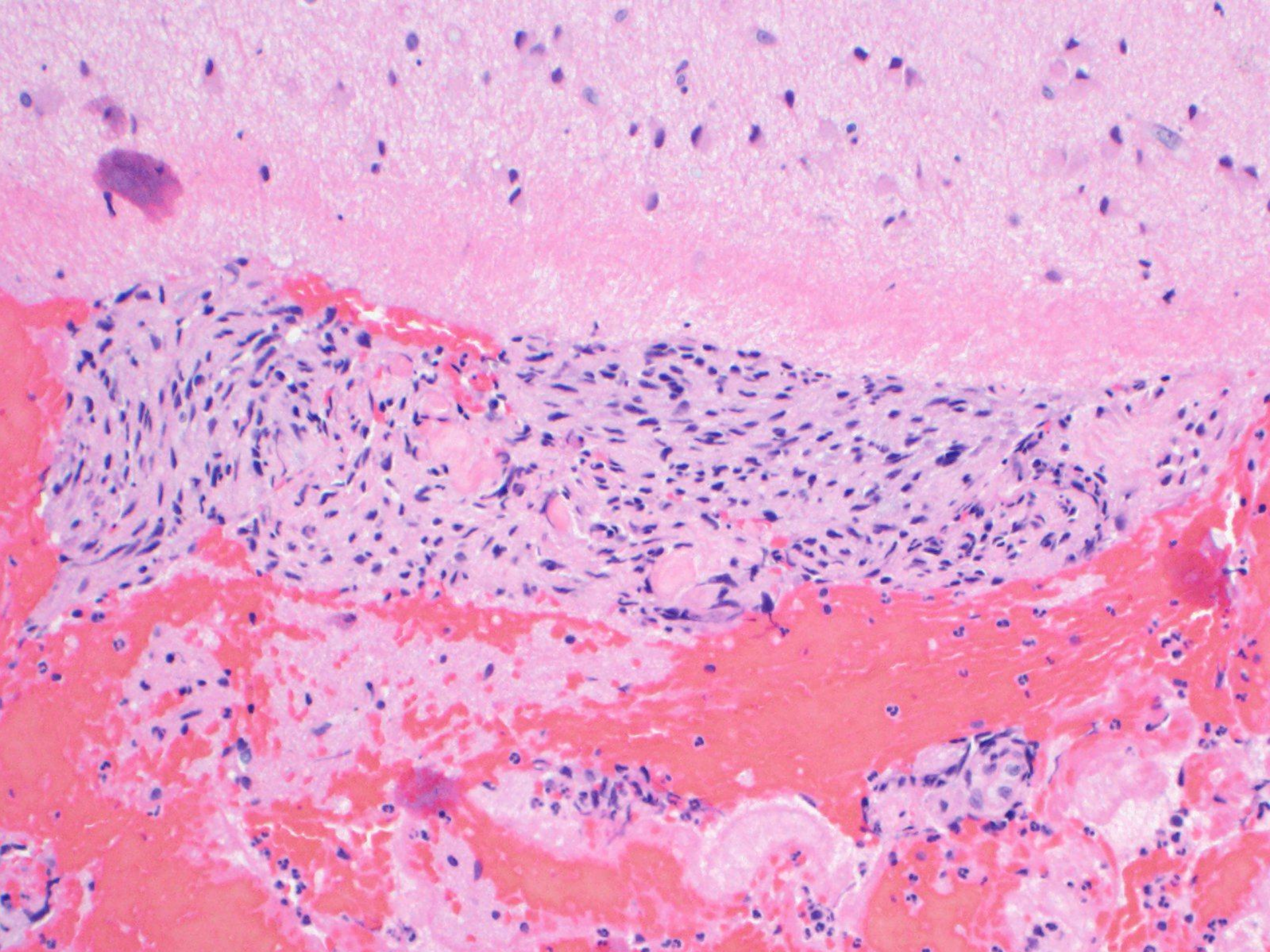
Blastomyces Ag (CSF)  
Brucella Ab  
CMV, EBV, JCV, VZV PCR (CSF)  
Enterovirus PCR (CSF)  
Fungal serology (CSF)  
HIV-1 PCR  
Leptospira Ab  
Lyme (CSF serology)  
Q Fever  
Mycobacterium TB PCR (CSF)  
VDRL (CSF)  
Paraneoplastic autoAb (CSF)

# **Biopsy**

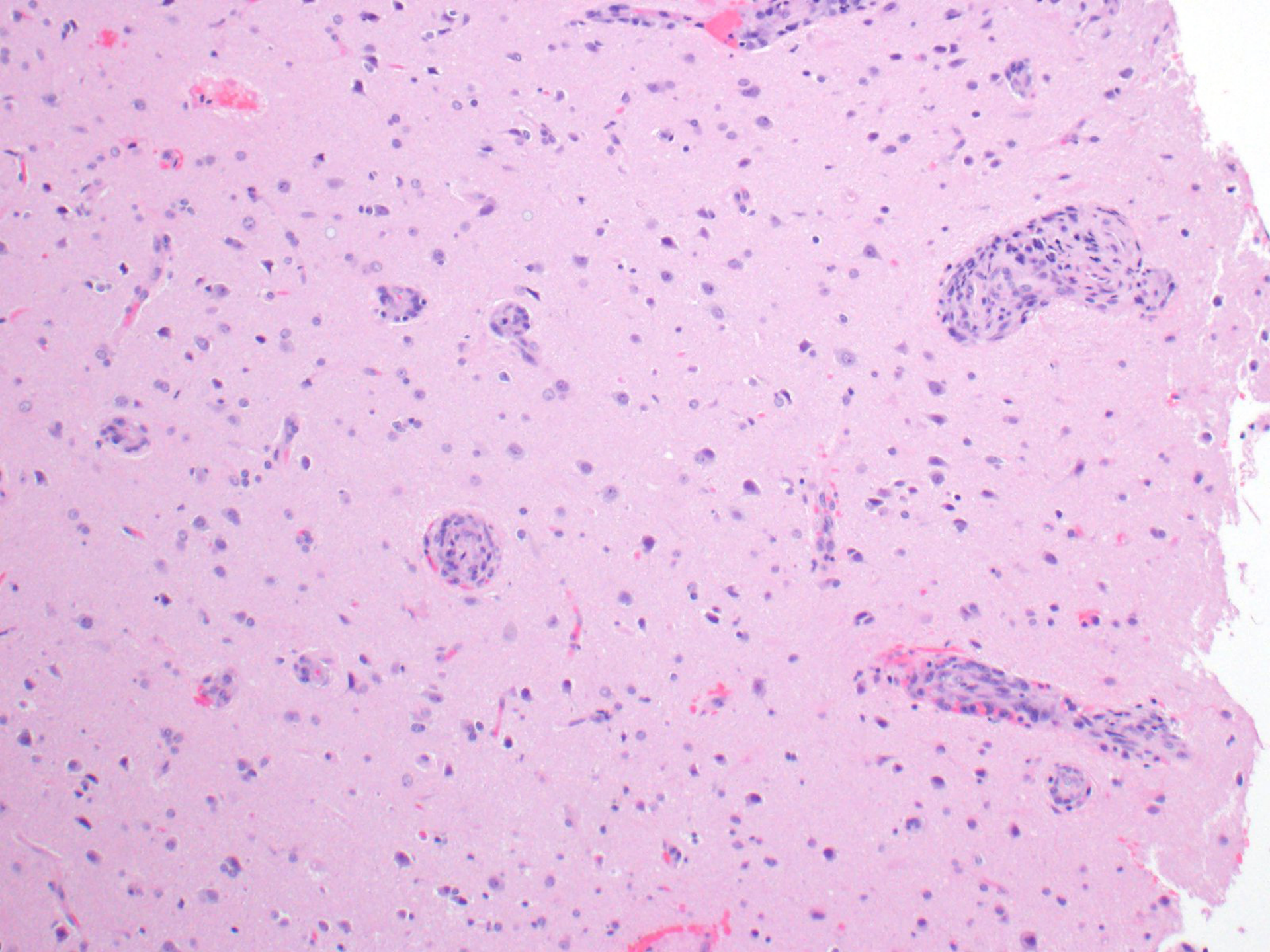
2/11/2014

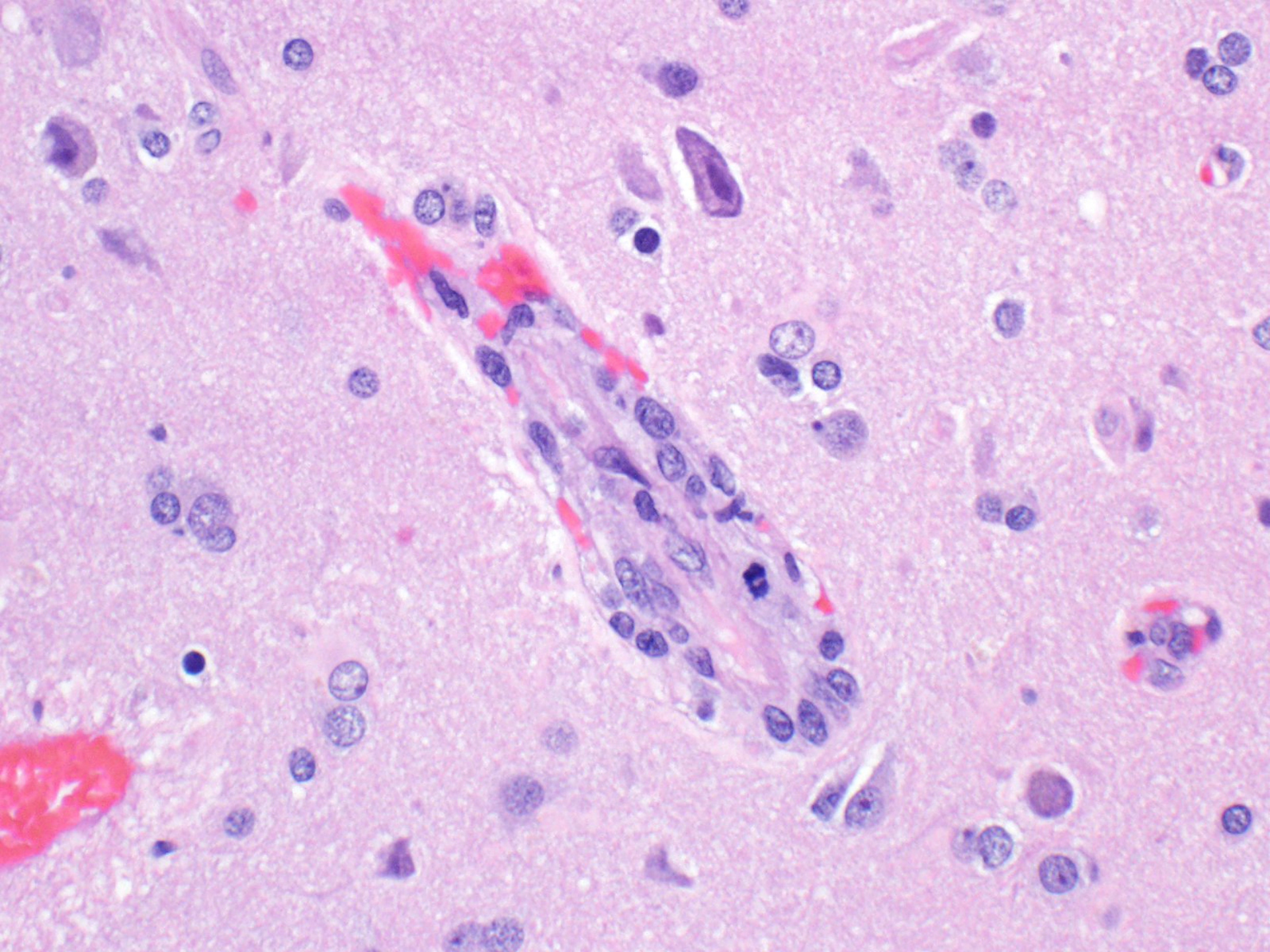


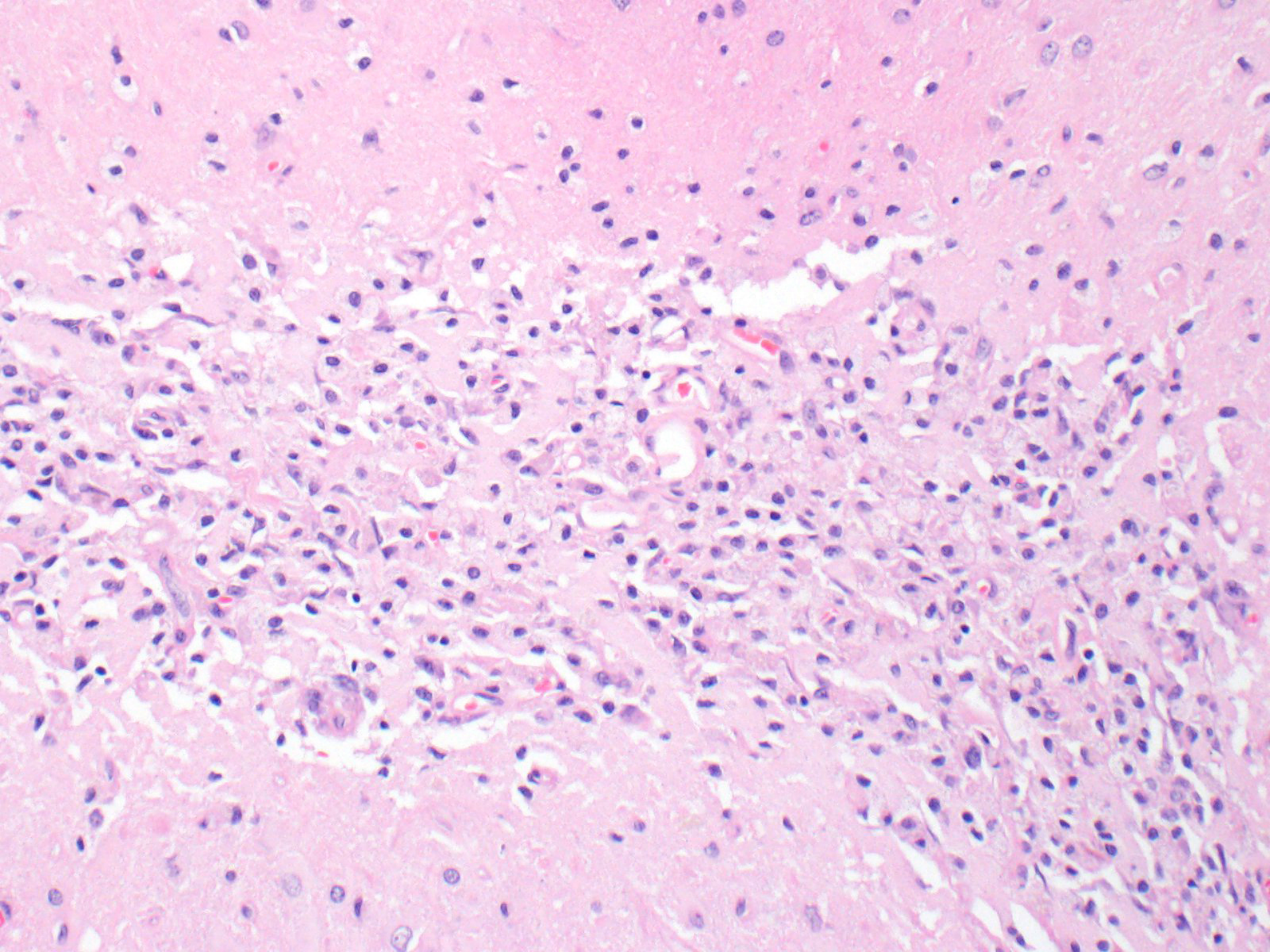












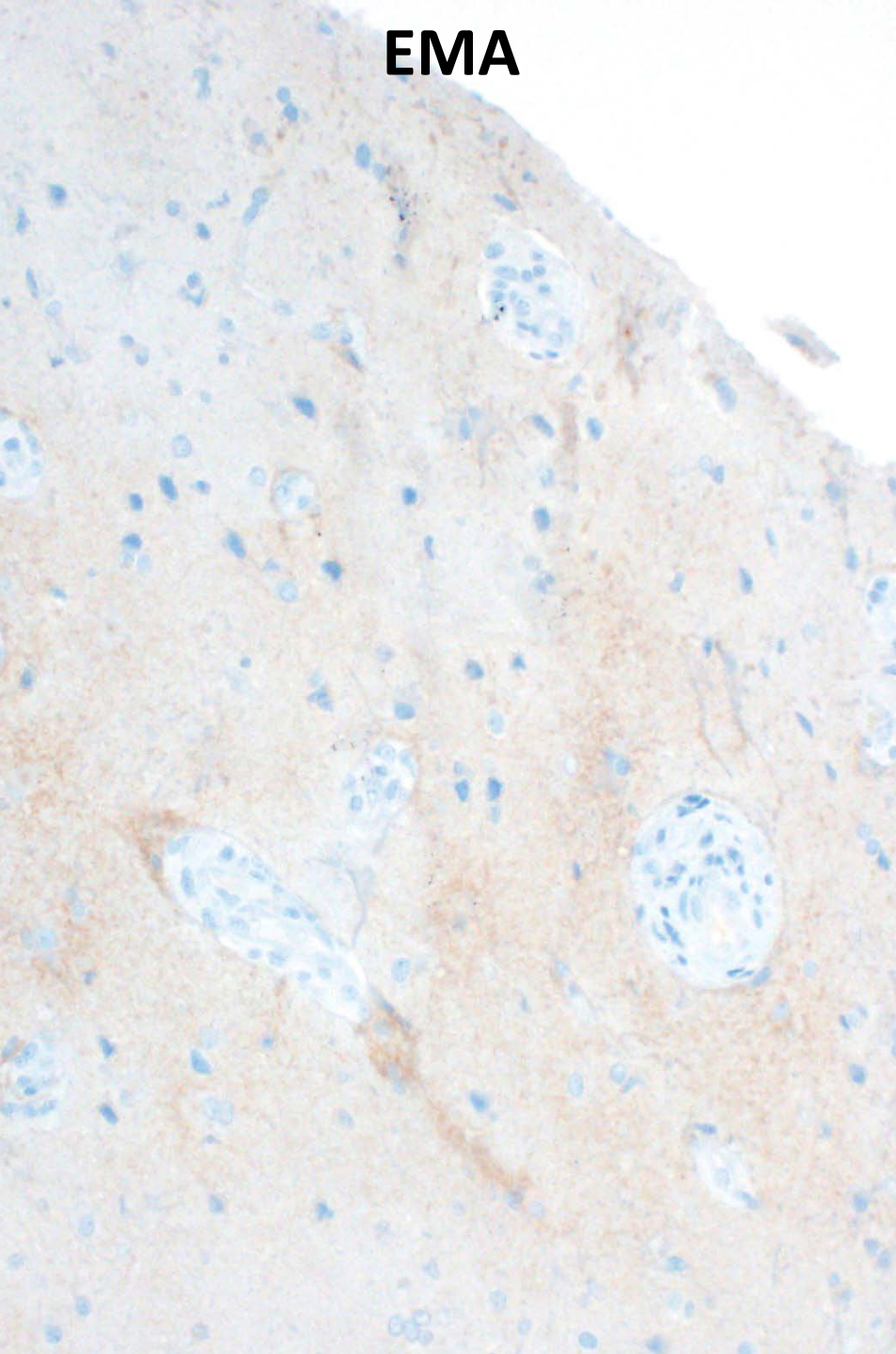
# Biopsy Discussion

- Differential diagnosis?
- Stains?

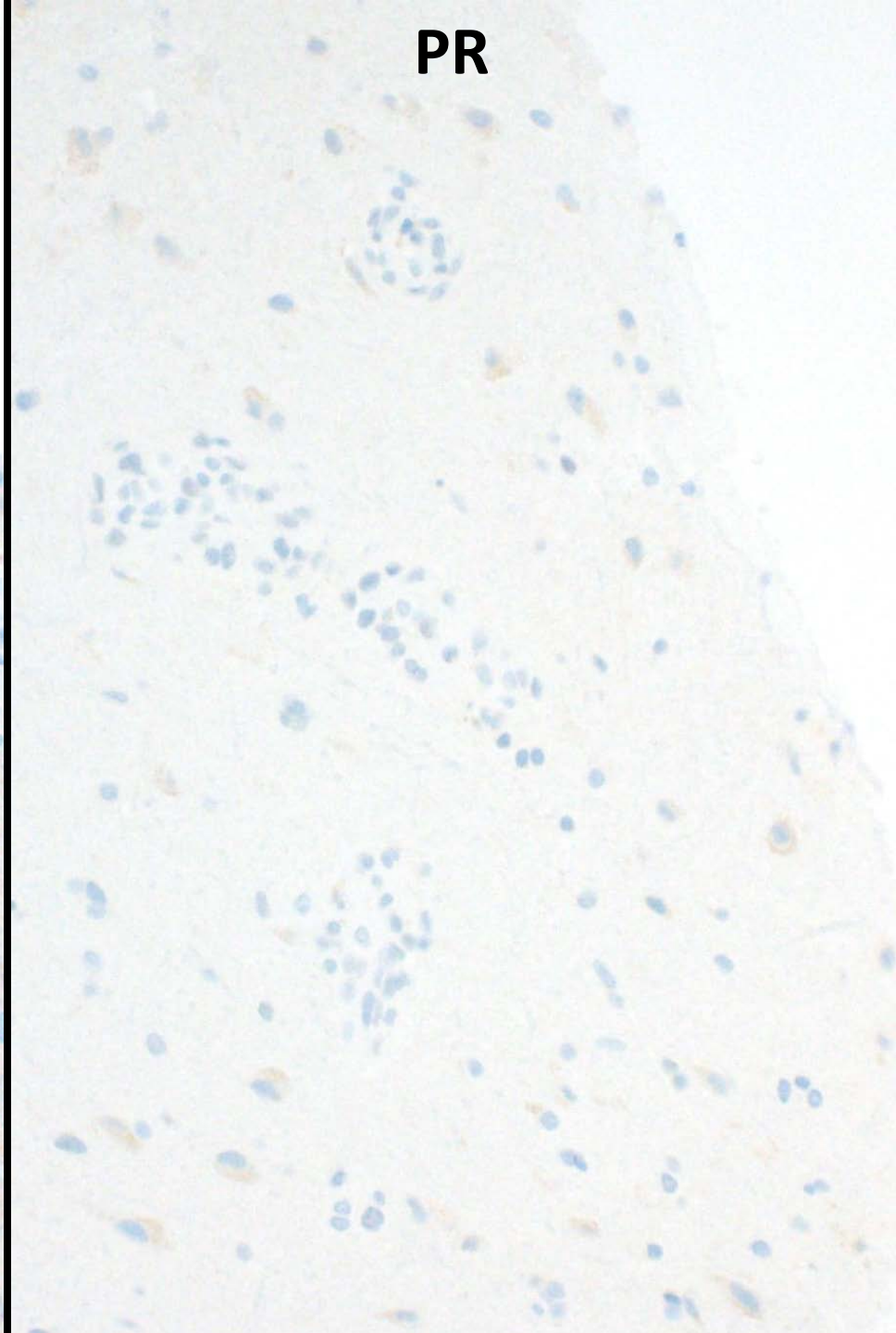
# Differential Diagnosis

- Meningioangiomatosis
- Vasocentric/perivascular process
  - Neoplastic
  - Non-neoplastic

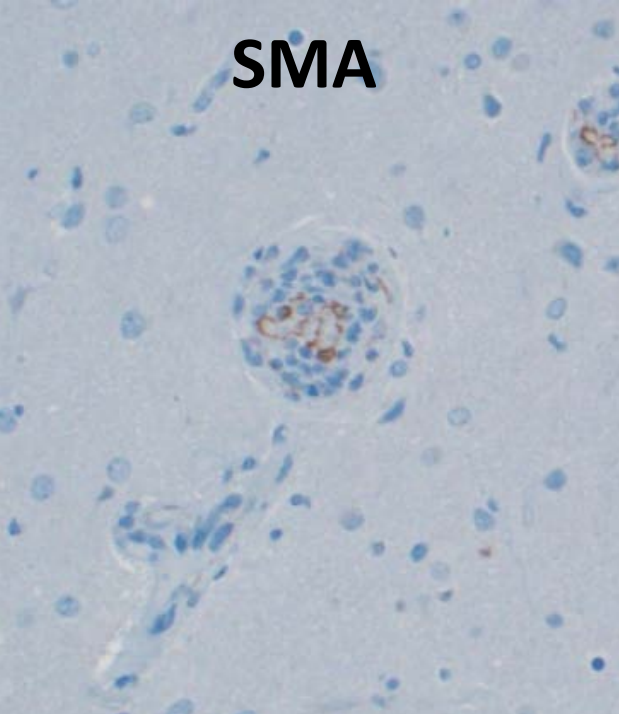
**EMA**



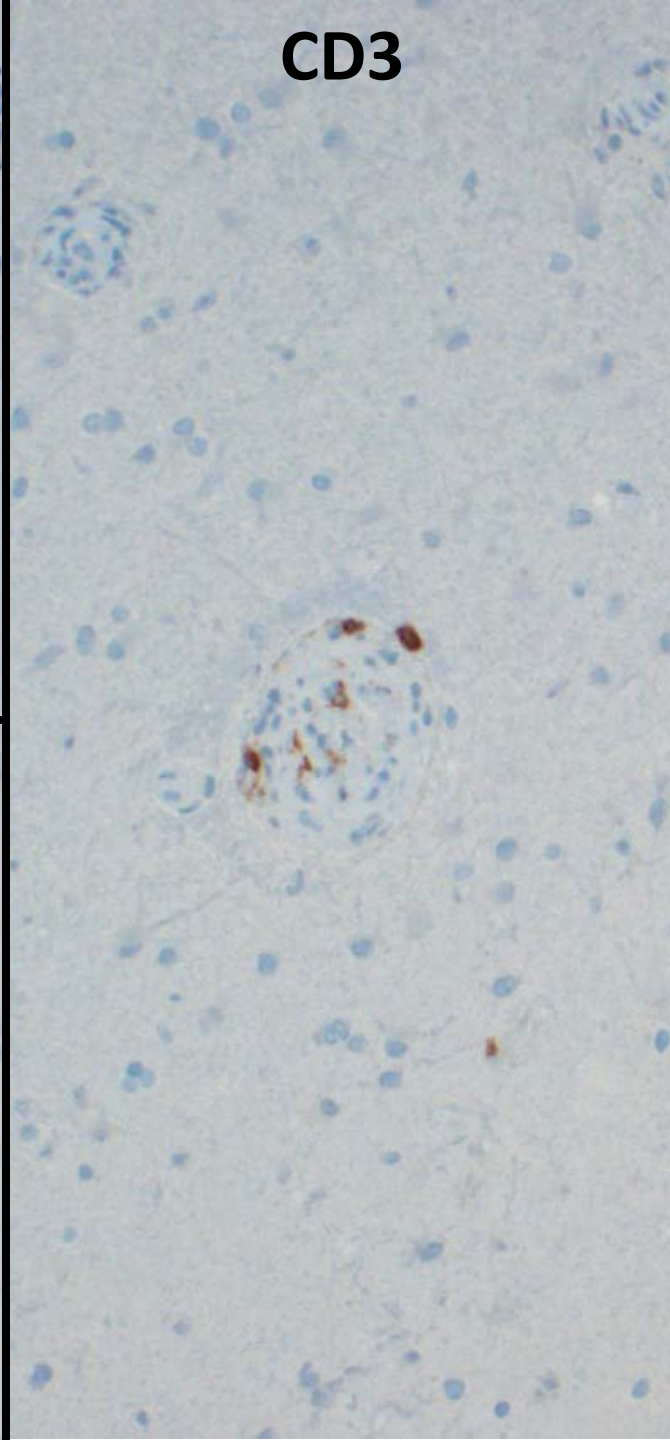
**PR**



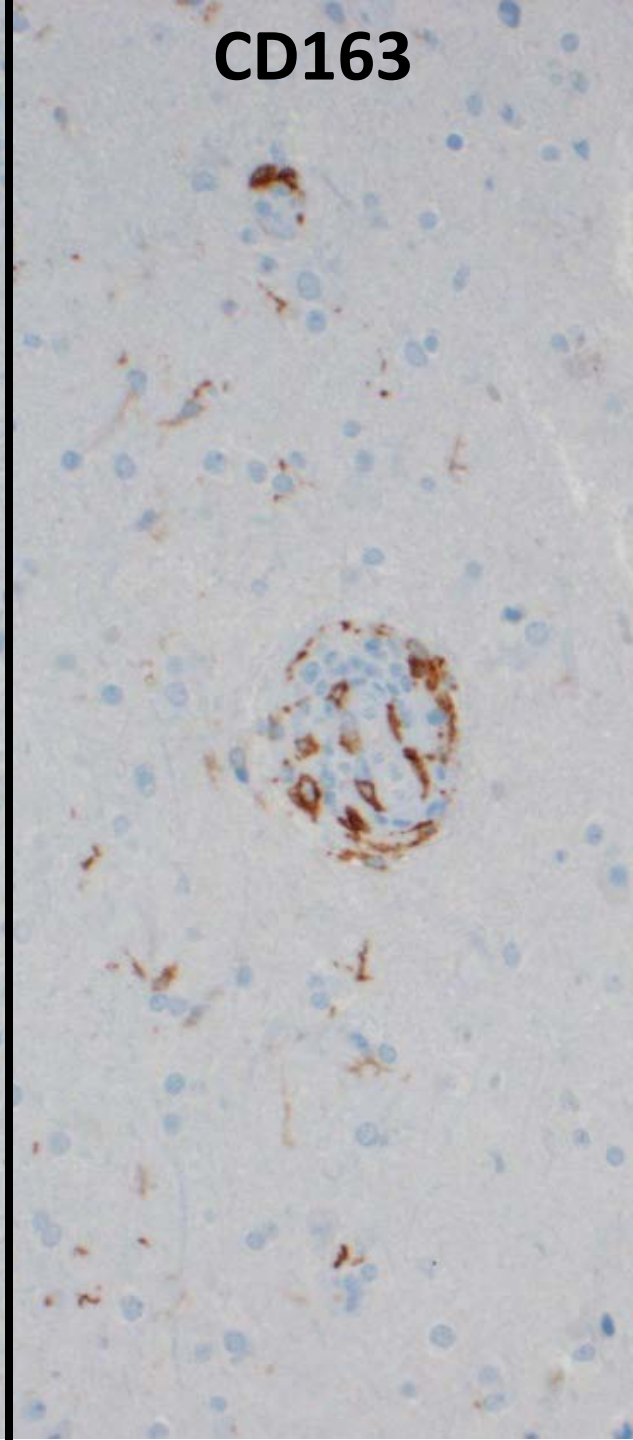
**SMA**



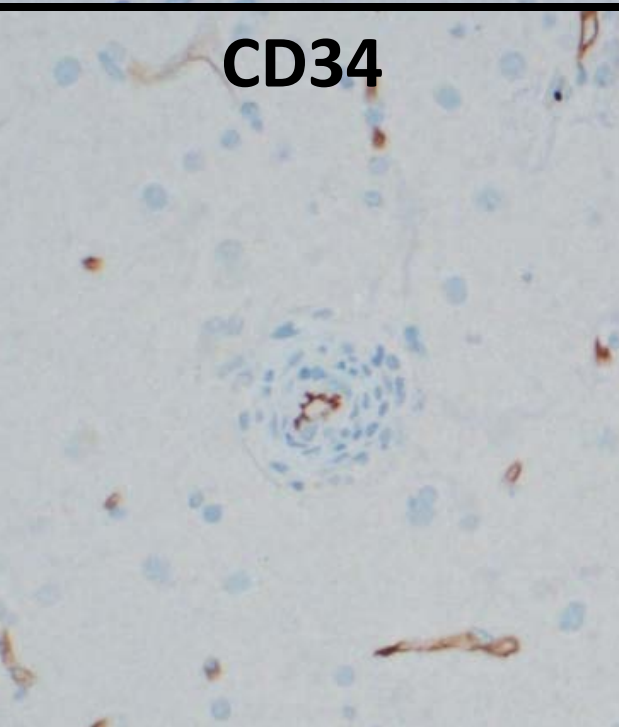
**CD3**



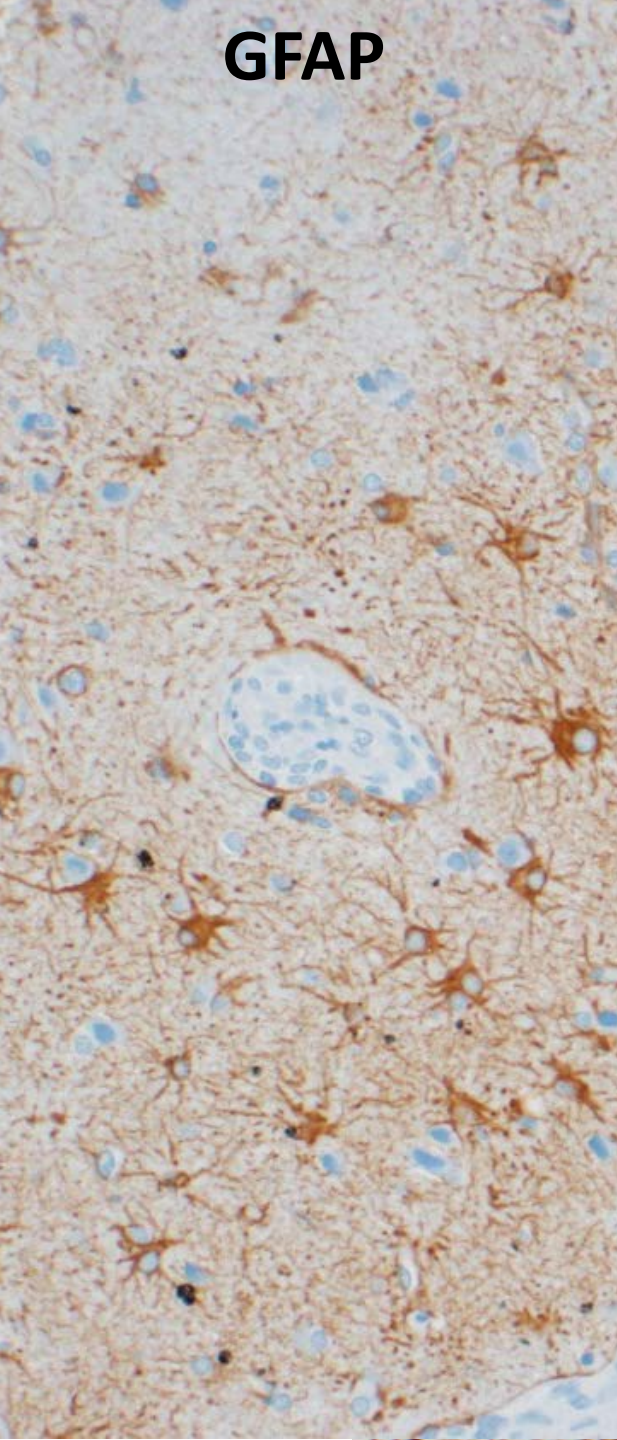
**CD163**



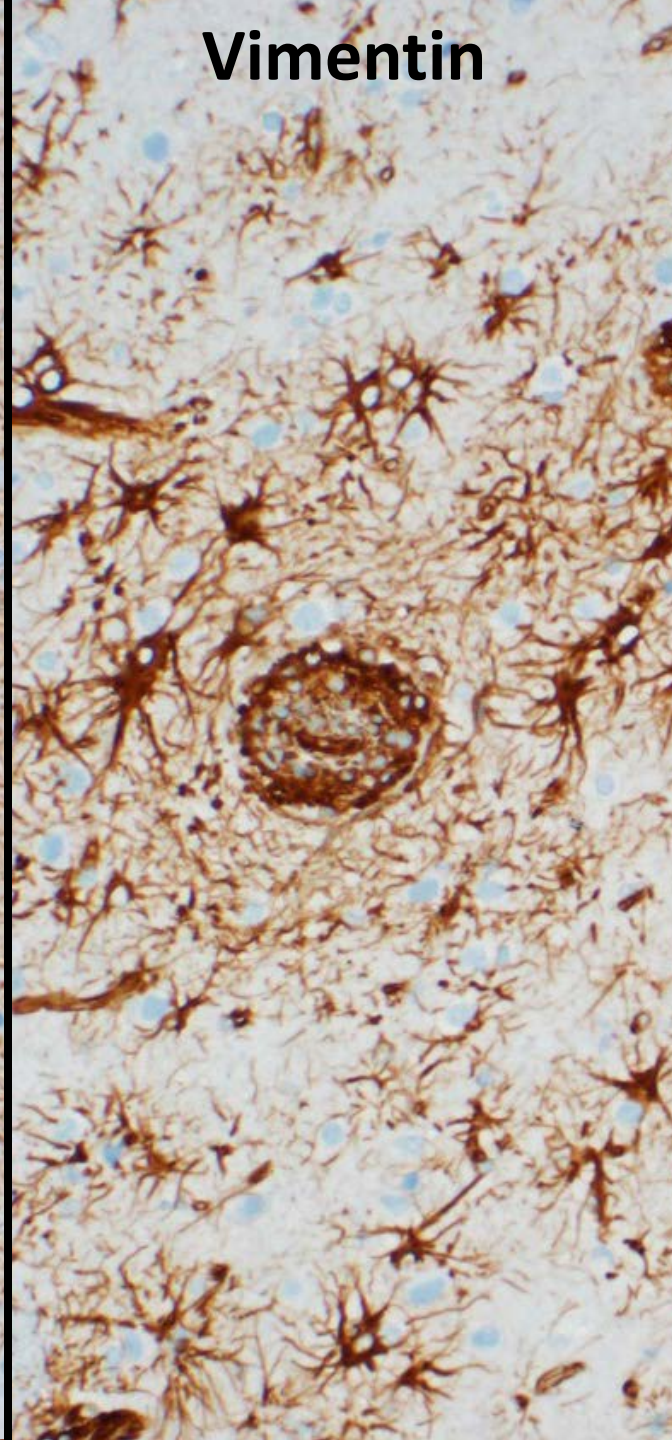
**CD34**



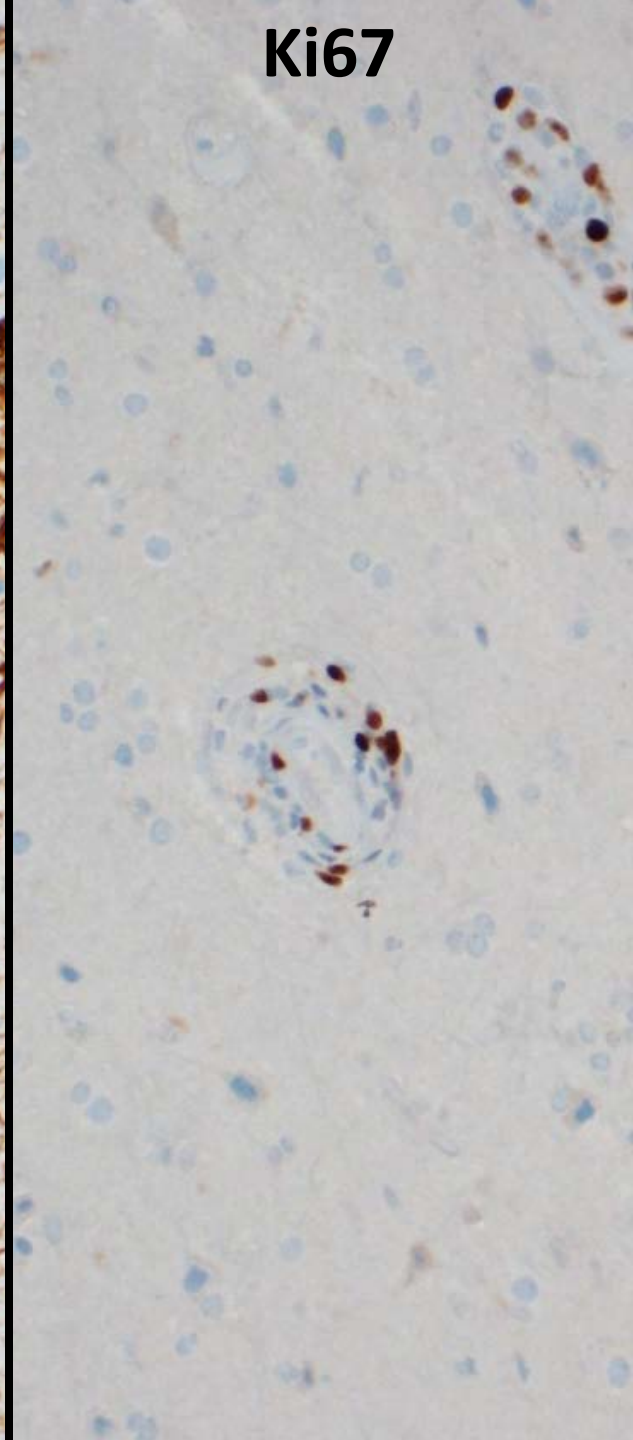
**GFAP**



**Vimentin**

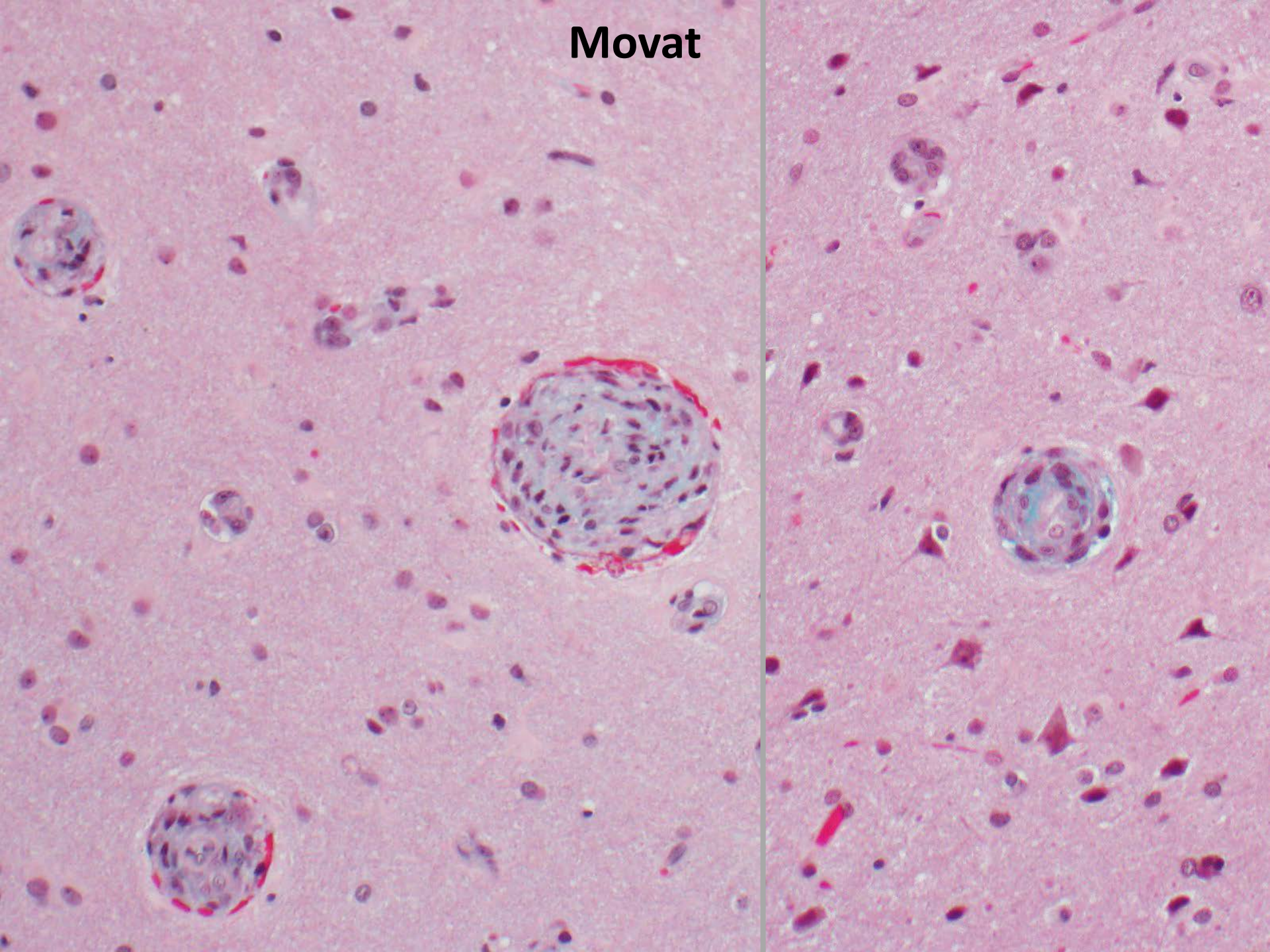


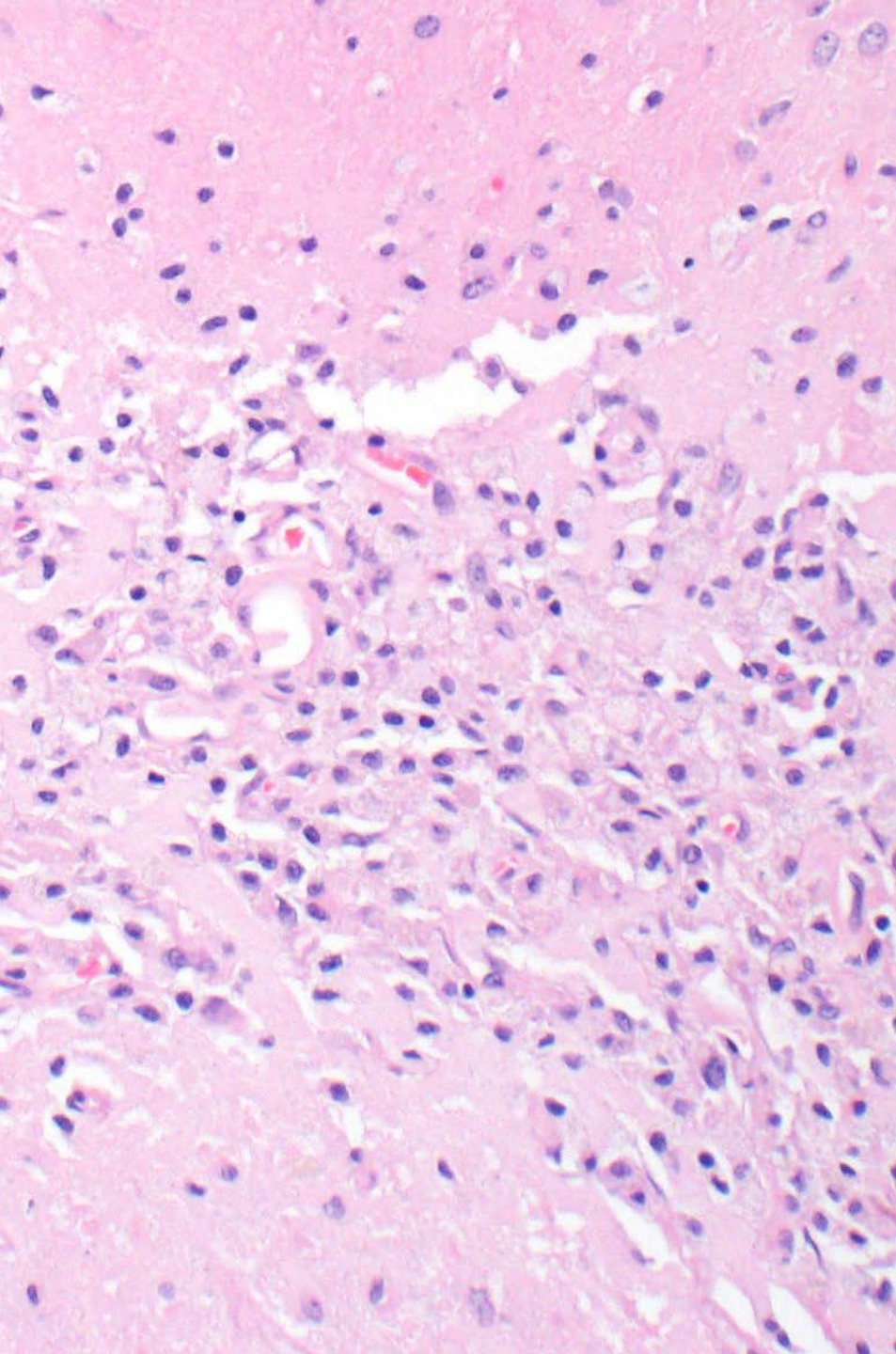
**Ki67**



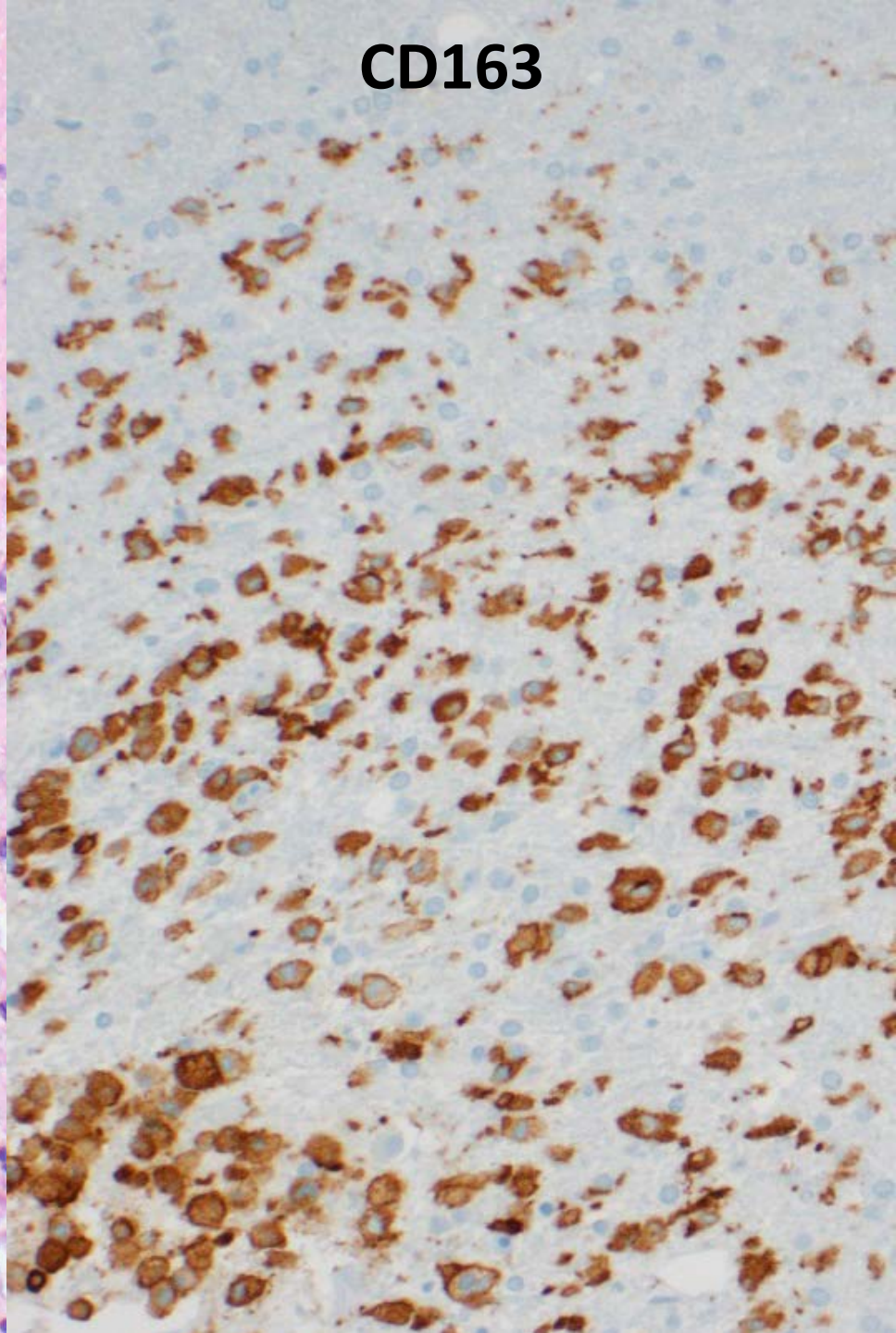


**Movat**





**CD163**



# Other Stains

- **Negative**

CD20

CD1a

S100

Iron

Tissue Gram stain

GMS

Fite

Spirochete

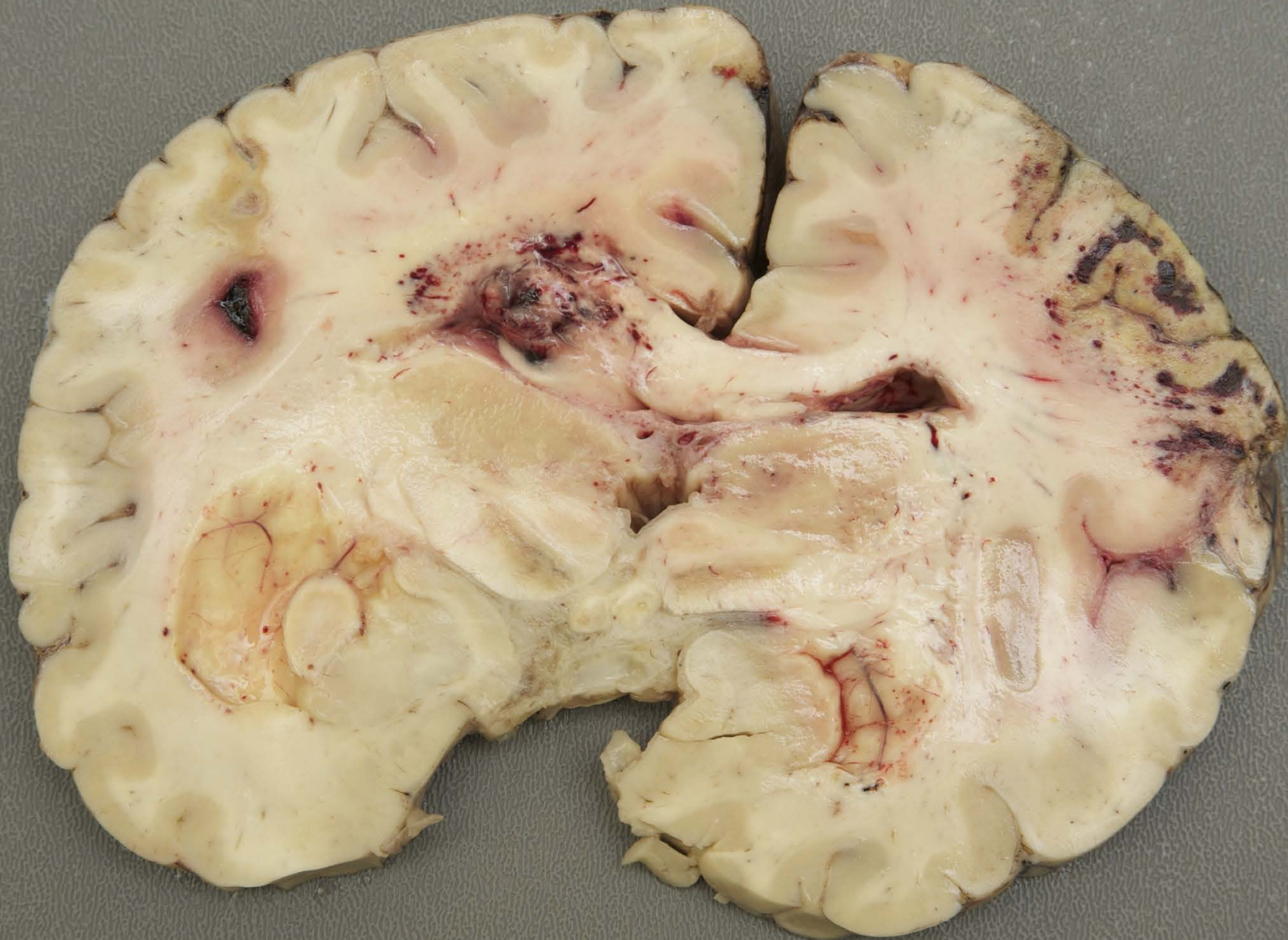
# Biopsy Diagnosis

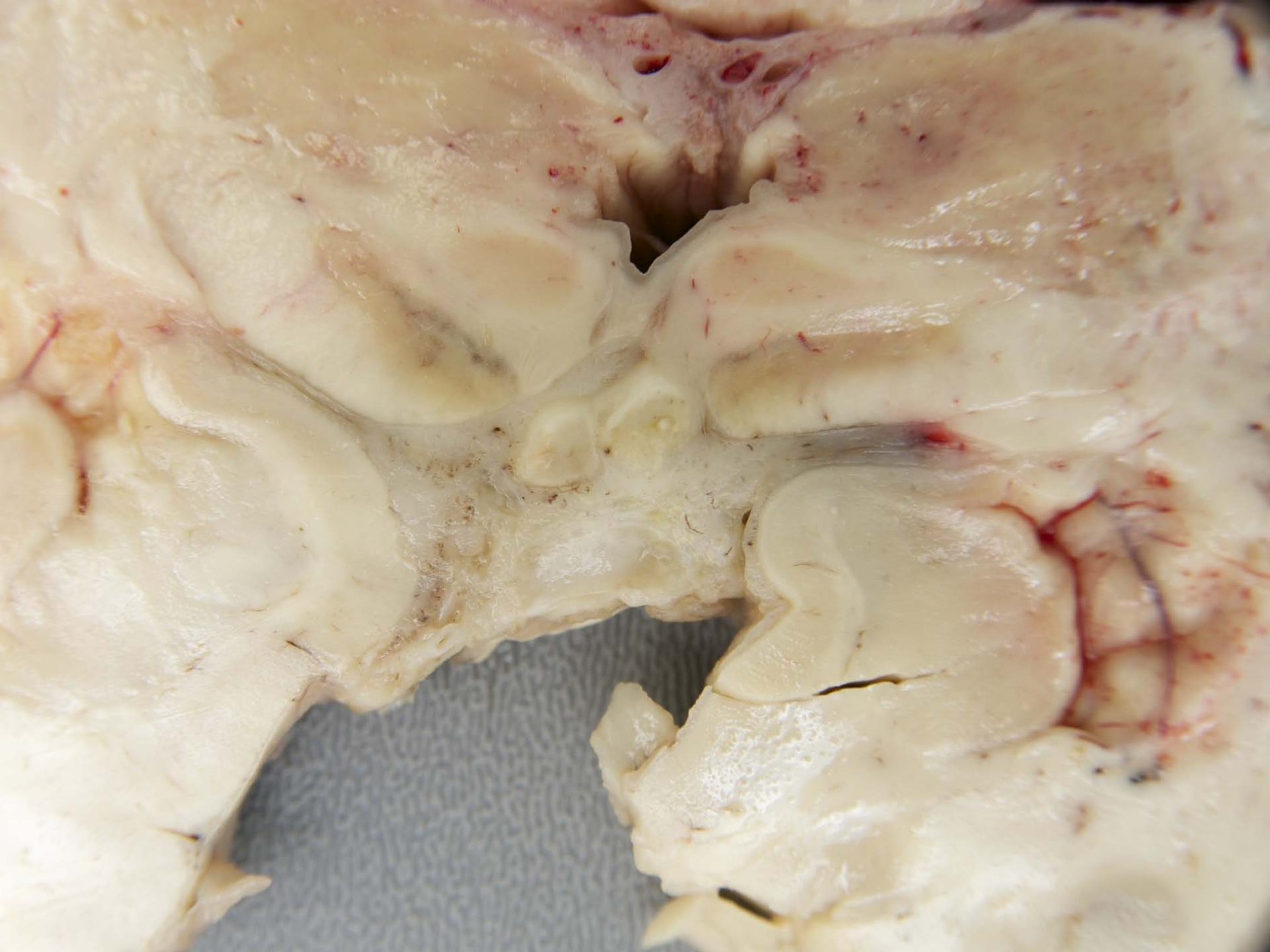
Obliterative microvascular disease with small necrotic foci within brain parenchyma.

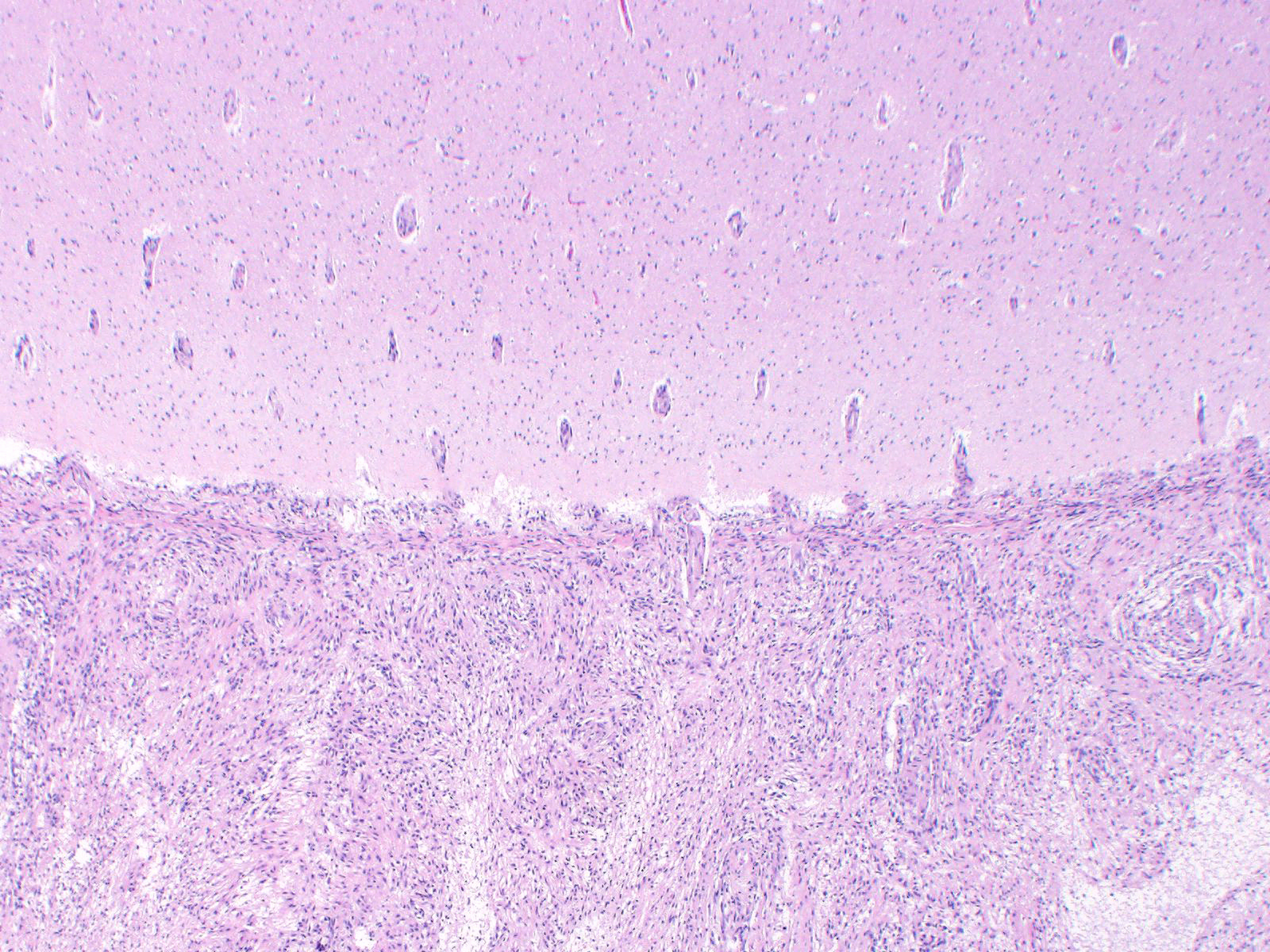
Tissue was sent for universal polymerase chain reaction analysis for bacteria, fungi, and mycobacteria (nontuberculous and tuberculosis); all testing was negative.

# **Autopsy**

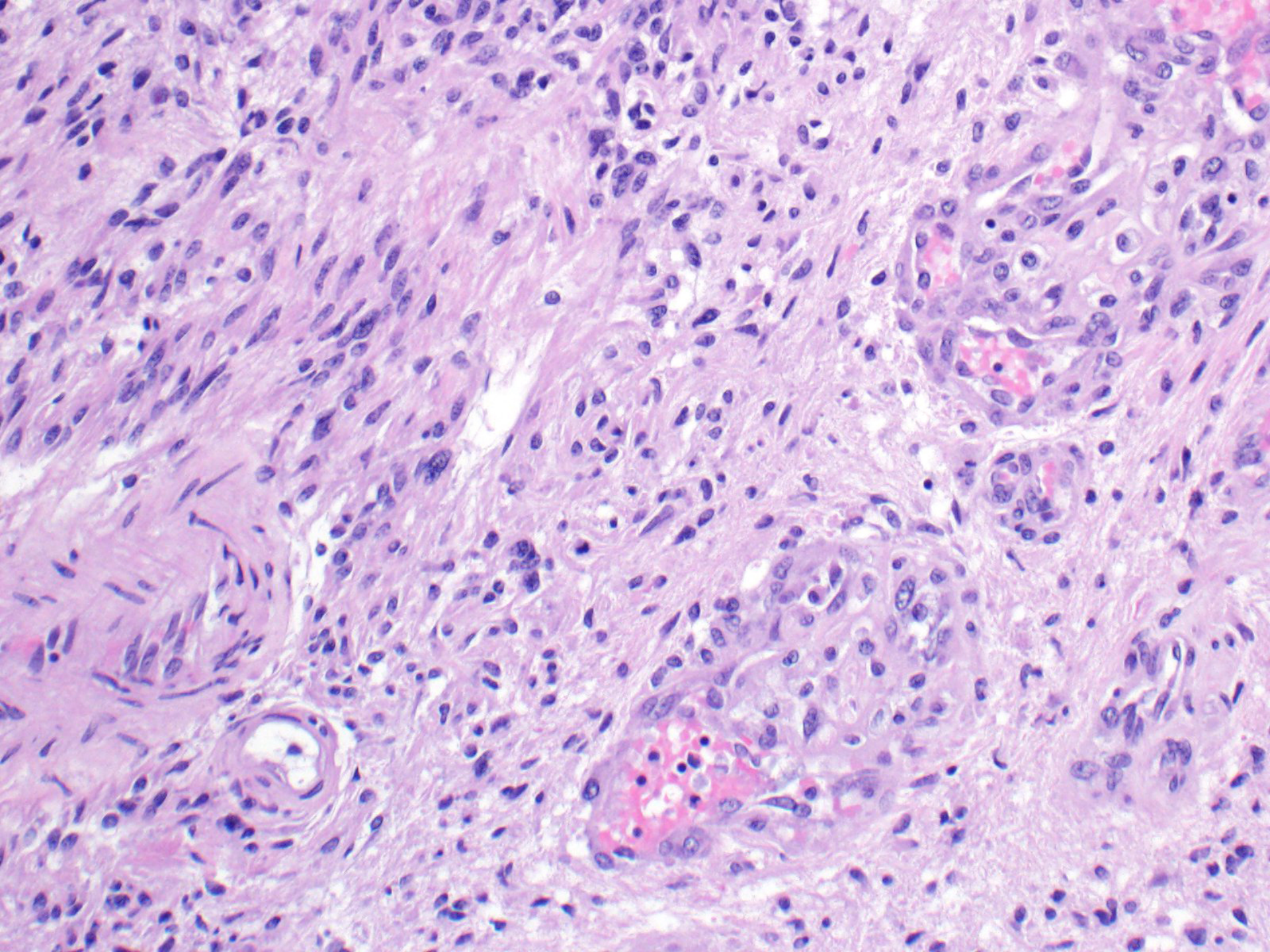
**3/3/2014**







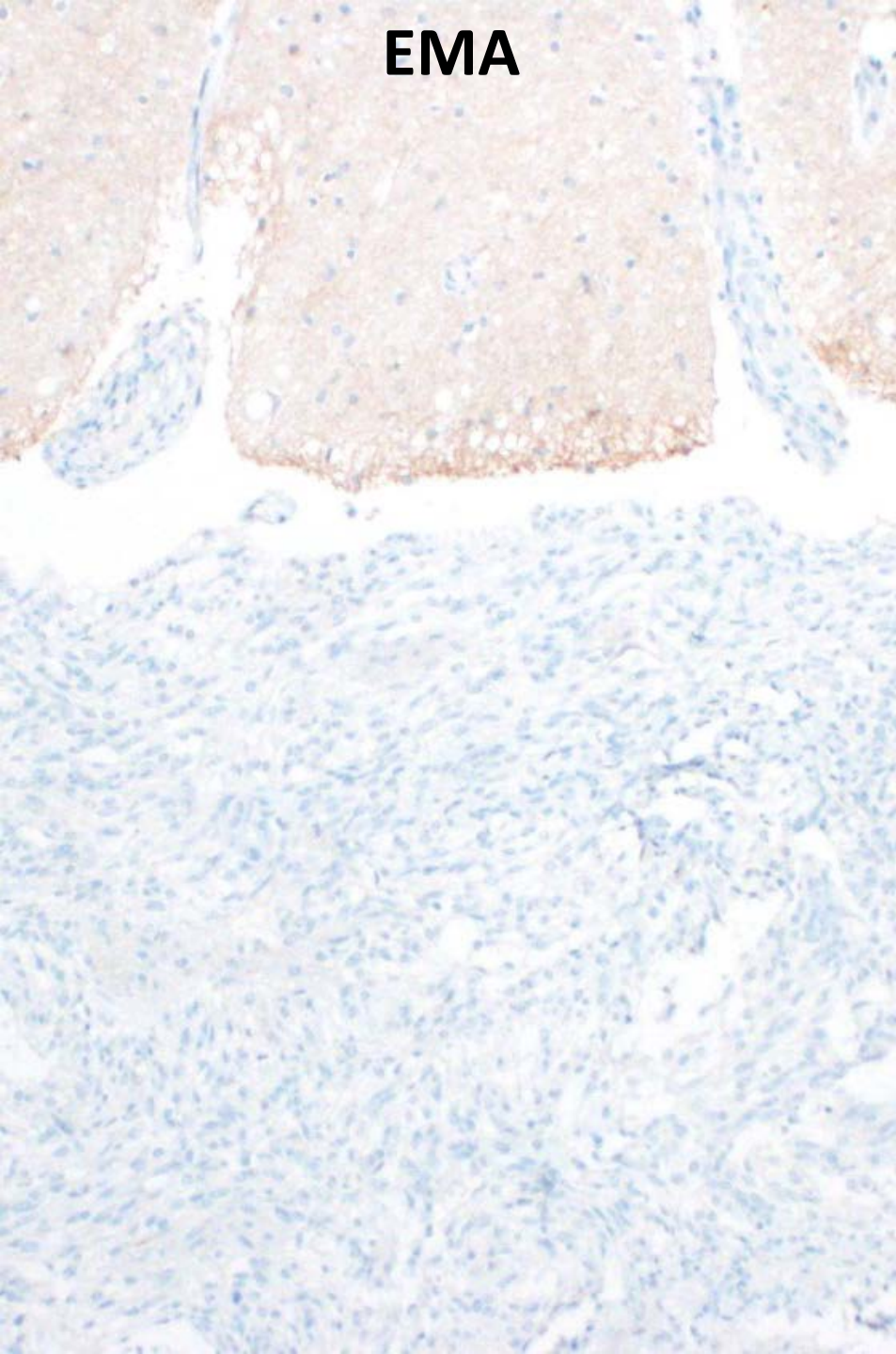




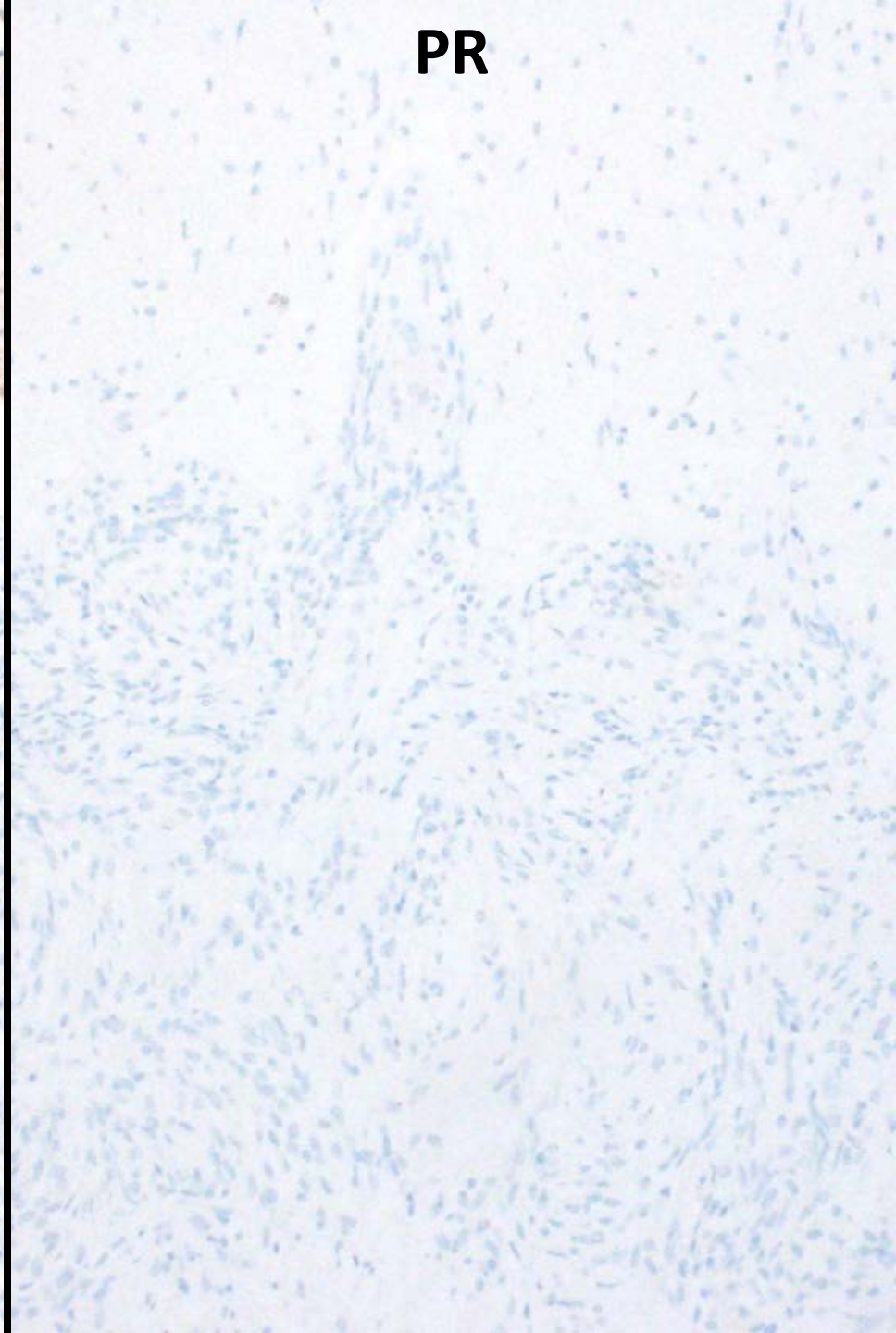
# Our Differential Diagnosis

- Meningioangiomatosis
- Rheumatoid meningitis
- Sarcoidosis
- IgG4-related meningeal disease

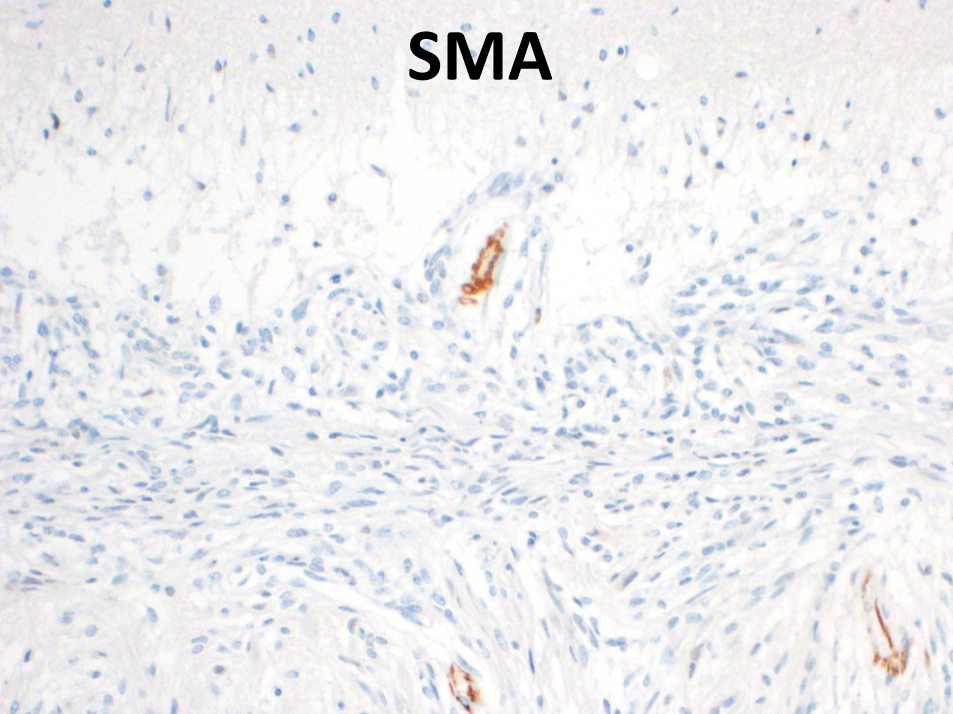
**EMA**



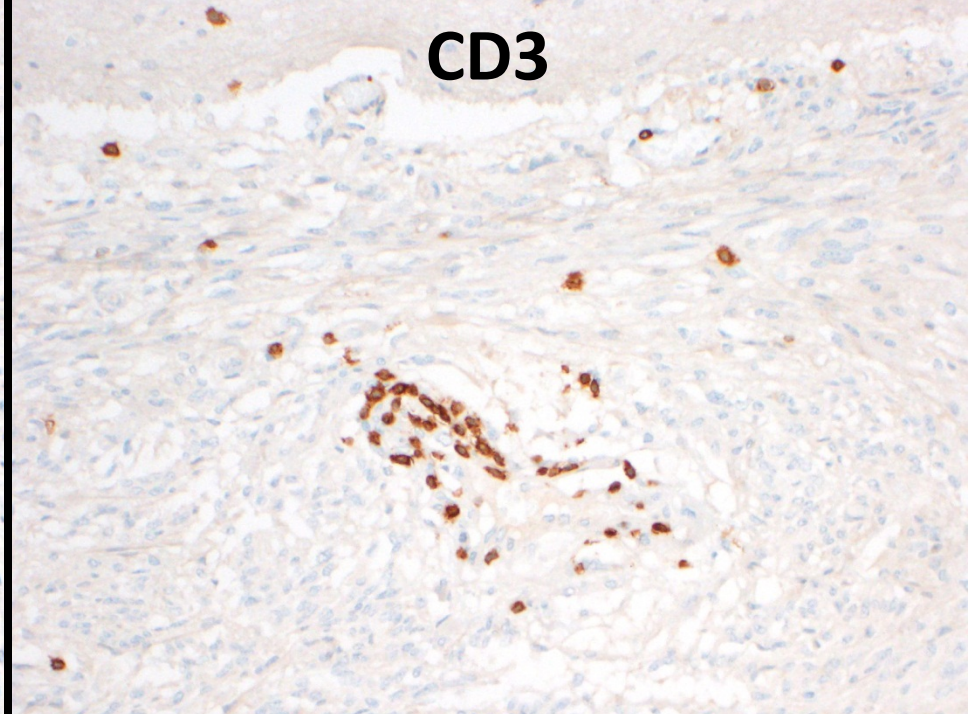
**PR**



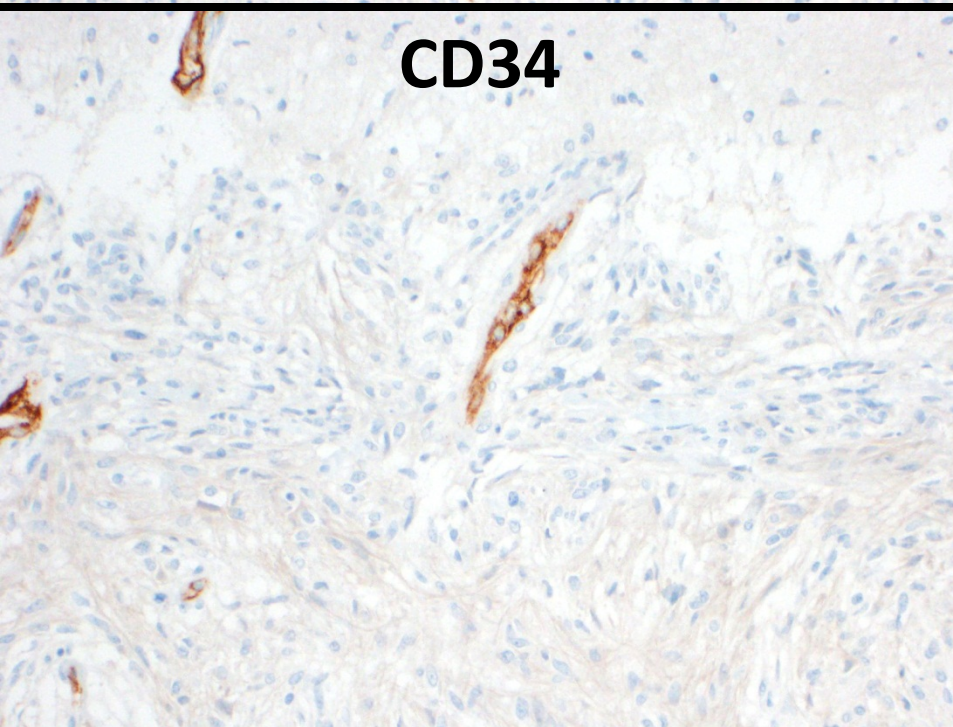
**SMA**



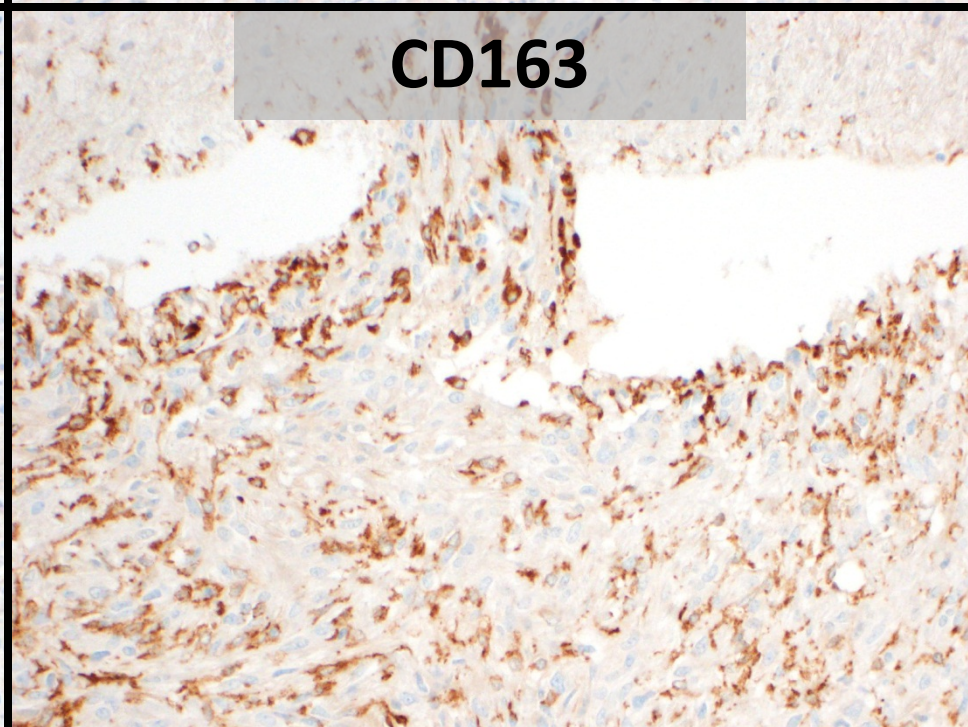
**CD3**



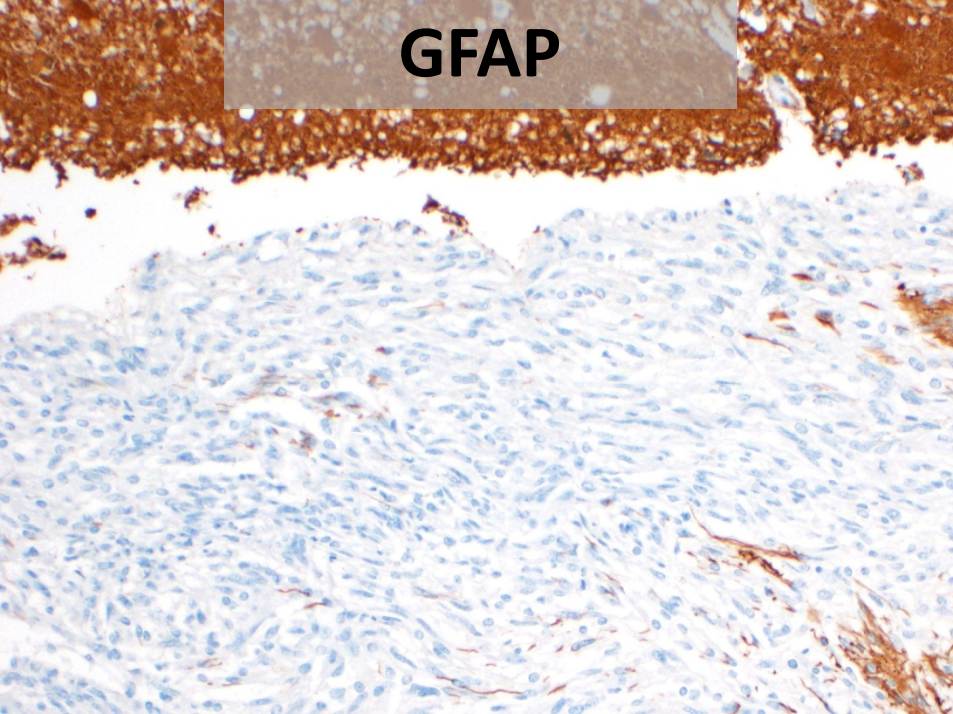
**CD34**



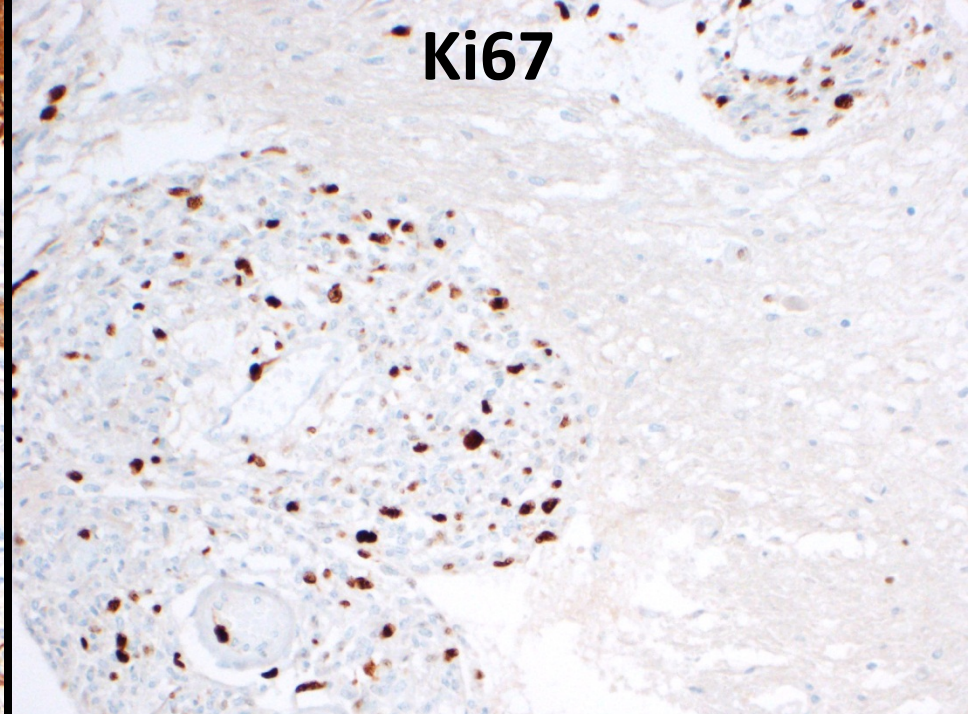
**CD163**



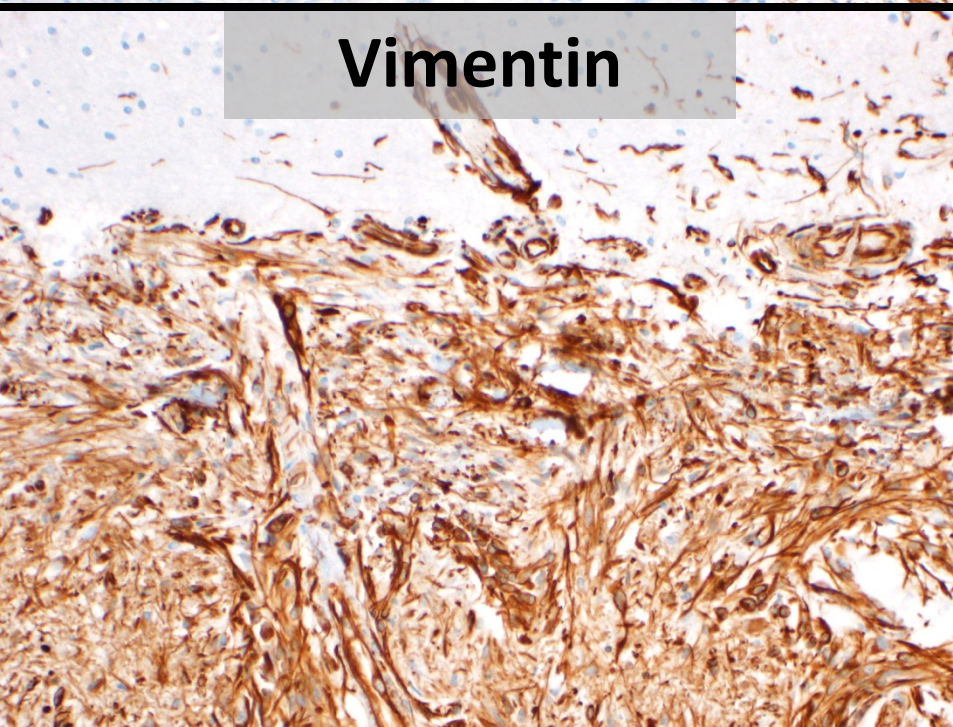
**GFAP**



**Ki67**



**Vimentin**



**Negative:**

CD20

CD1a

IgG, IgG4

S100

Desmin

Tyrosinase

Tissue Gram stain

GMS

Fite

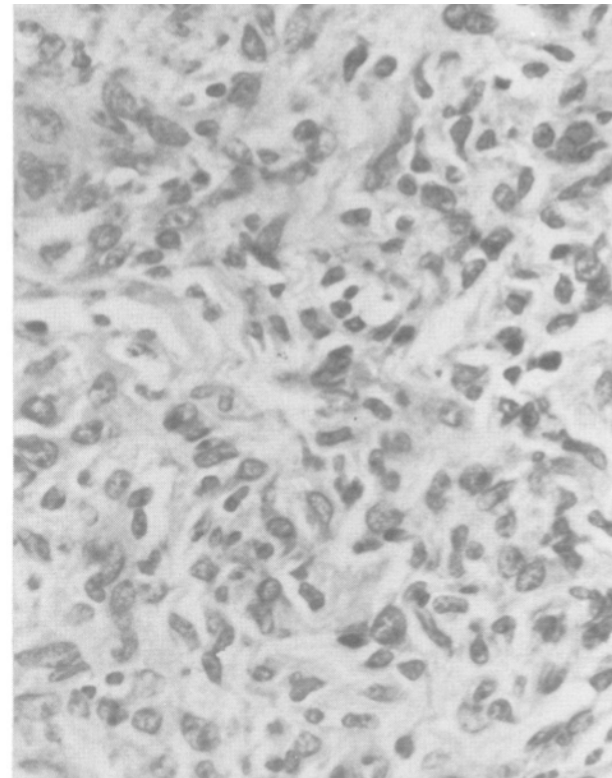
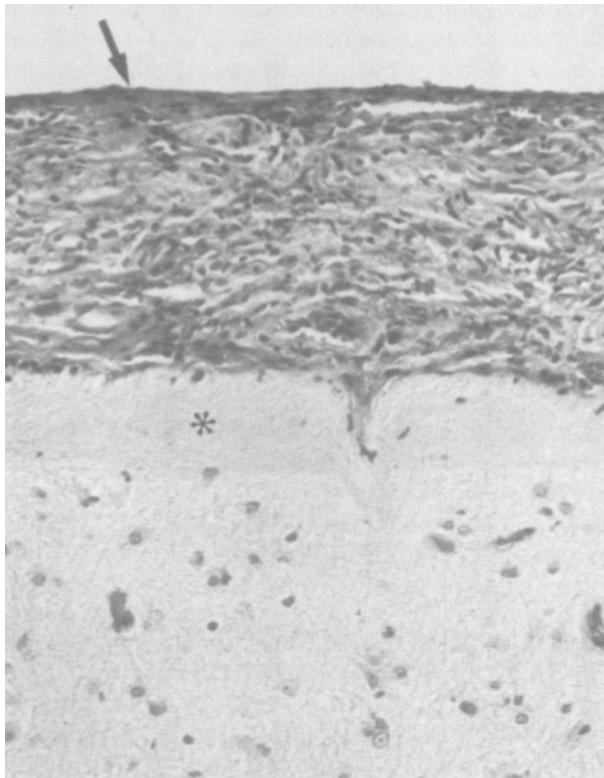
Spirochete

# Our Differential Diagnosis

- Meningioangiomatosis
- Rheumatoid meningitis
- Sarcoidosis
- IgG4-related meningeal disease
- **Progressive leptomeningeal fibrosis**

# Progressive Leptomeningeal Fibrosis

- Case report (Chalif D *et al.*, *JNN Psych*, 1983)  
41-year-old woman with 20 years of facial pain  
Presented with signs/symptoms of increased ICP  
Craniotomy: thick, fibrous leptomeninges



# Autopsy Diagnosis

The gross and histological findings are consistent with a **chronic-active proliferative process**. This process is felt to be **neither infectious nor neoplastic**.

The histologic pattern is **nonspecific**, but is suggestive of **progressive leptomeningeal fibrosis**.



# Summary

- Sampling
- We are open to suggestions!

# References

Chalif D, Duchen LW, Marshall J, Hayward R. Progressive leptomenigeal fibrosis: a clinico-pathological case report. *J Neurol Neurosurg Psychiatry*. 1983 Mar;46(3):261-5.

Jamil O, Ramkissoon S, Folkerth R, Smith E. Multifocal meningioangiomas in a 3-year-old patient. *J Neurosurg Pediatr*. 2012 Dec;10(6):486-9.

Kato T, Hoshi K, Sekijima Y, Matsuda M, Hashimoto T, Otani M, Suzuki A, Ikeda S. Rheumatoid meningitis: an autopsy report and review of the literature. *Clin Rheumatol*. 2003 Dec;22(6):475-80.

Li P, Cui G, Wang Y, Geng M1, Wang Z. Multicystic meningioangiomas. *BMC Neurol*. 2014 Feb 20;14:32.

Lu L, Della-Torre E, Stone JH, Clark SW. IgG4-related hypertrophic pachymeningitis: clinical features, diagnostic criteria, and treatment. *JAMA Neurol*. 2014 Jun;71(6):785-93.

Nowak DA, Widenka DC. Neurosarcoidosis: a review of its intracranial manifestation. *J Neurol*. 2001 May;248(5):363-72.

Zajicek JP, Scolding NJ, Foster O, Rovaris M, Evanson J, Moseley IF, Scadding JW, Thompson EJ, Chamoun V, Miller DH, McDonald WI, Mitchell D. Central nervous system sarcoidosis – diagnosis and management. *QJM*. 1999 Feb;92(2):103-17.