

57th ANNUAL DIAGNOSTIC SLIDE SESSION 2016

CASE 2016-4

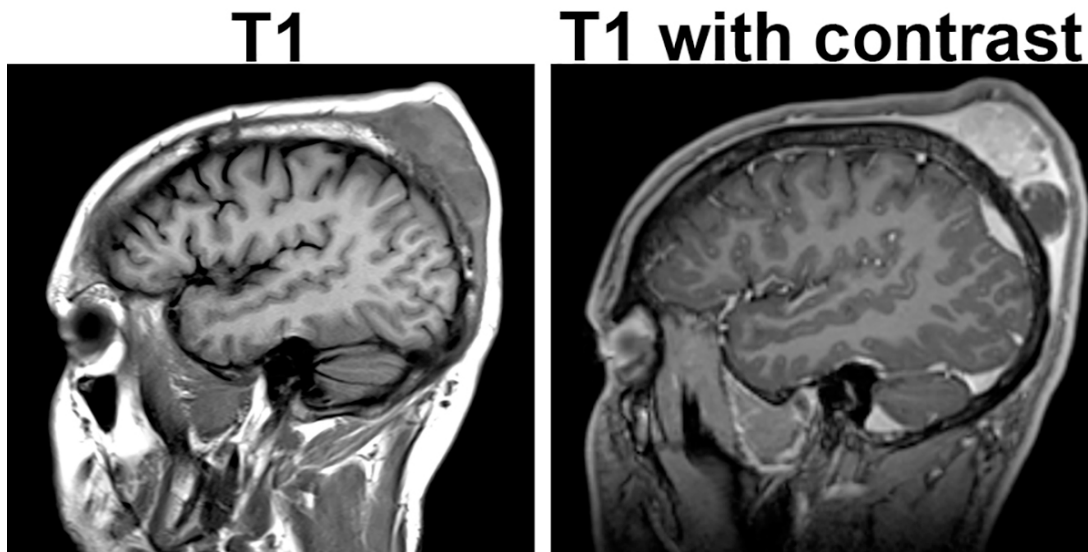
Submitted by:

Craig Horbinski, Benjamin Liu, Christina Appin, and Qinwen Mao

Northwestern University, Tarry 2-705, 300 East Superior Street, Chicago IL 60611

Clinical History:

The patient was a 24-year-old man, with no significant PMH, who noticed a small mass on his head that grew rapidly over the next several weeks. He did not seek medical care until one month after he first noticed the mass, when he had a generalized tonic-clonic seizure. An MRI demonstrated a 7.7 x 5.4 x 1.8 cm subgaleal soft tissue mass in the posterior superior aspect (see separate MRI images). There was also an intracranial component of the mass that measured 2.1 x 0.7 cm. The tumor was resected.



Intraoperatively, the mass was rather firm, invading bone and dura.

The lesion received in surgical pathology was a 5.3 x 3.4 x 1.6 cm yellow and white-tan lobulated, rubbery mass. Dura was attached.

Material submitted:

1 H&E-stained slide

Points for discussion:

1. Differential diagnosis and additional stains
2. Final diagnosis and optimal therapy