

2017 Diagnostic Slide Session

Case 3

Andrew Gao, MD

Lili-Naz Hazrati, MD, PhD

Cynthia Hawkins, MD, PhD

Hospital for Sick Children and University of Toronto, Toronto, Canada



UNIVERSITY OF
TORONTO

Disclosures: none

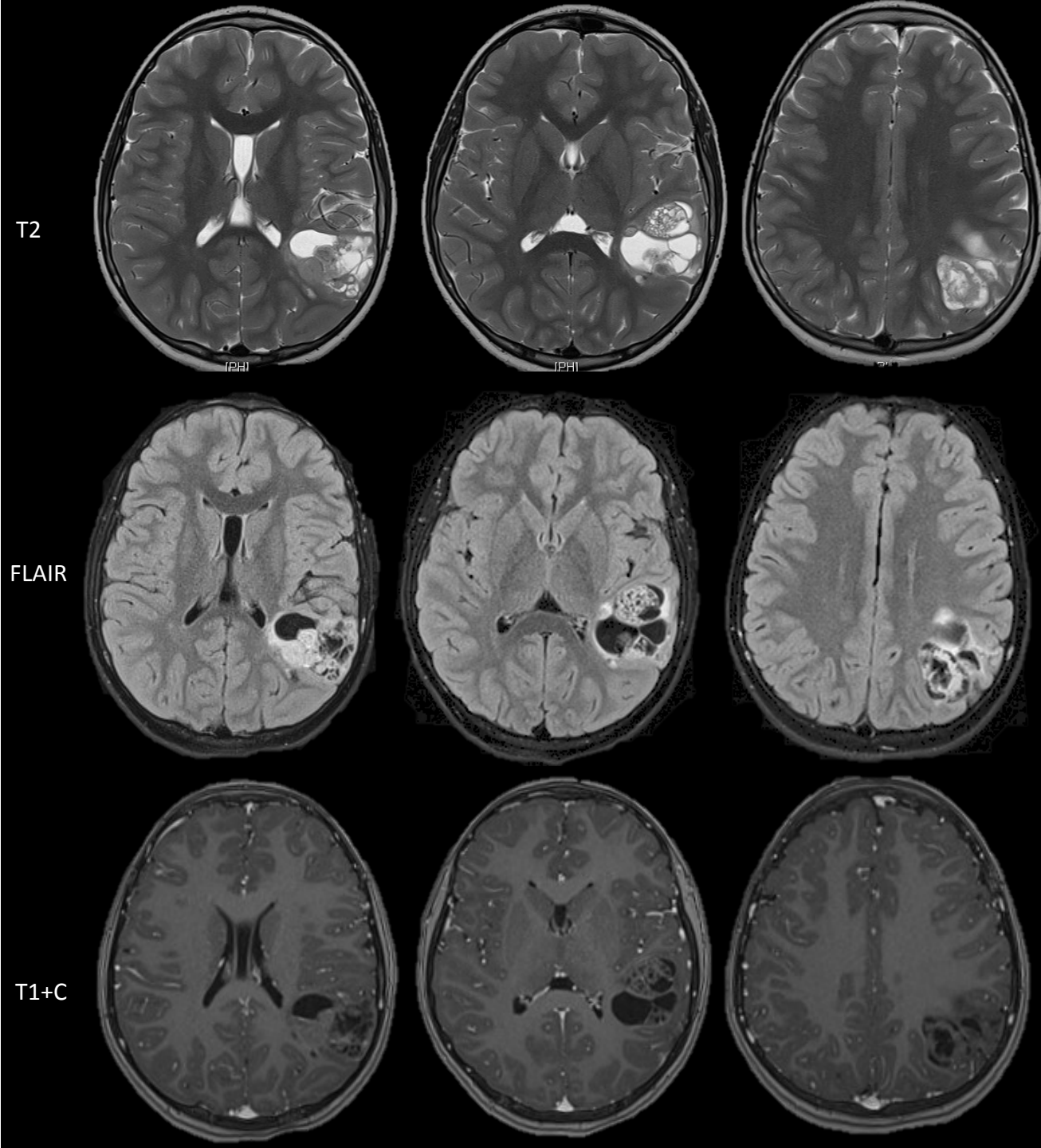
Clinical History

9-year-old girl from El Salvador with longstanding history of partial seizures and occasional headaches

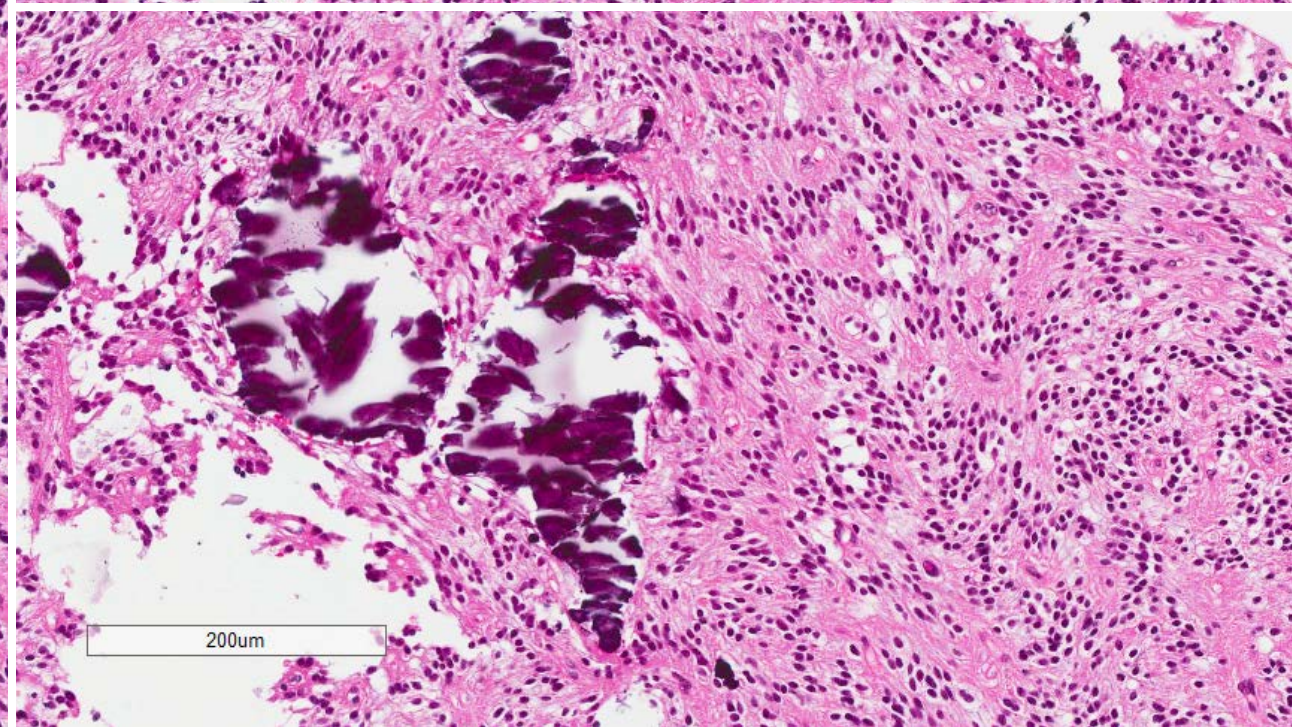
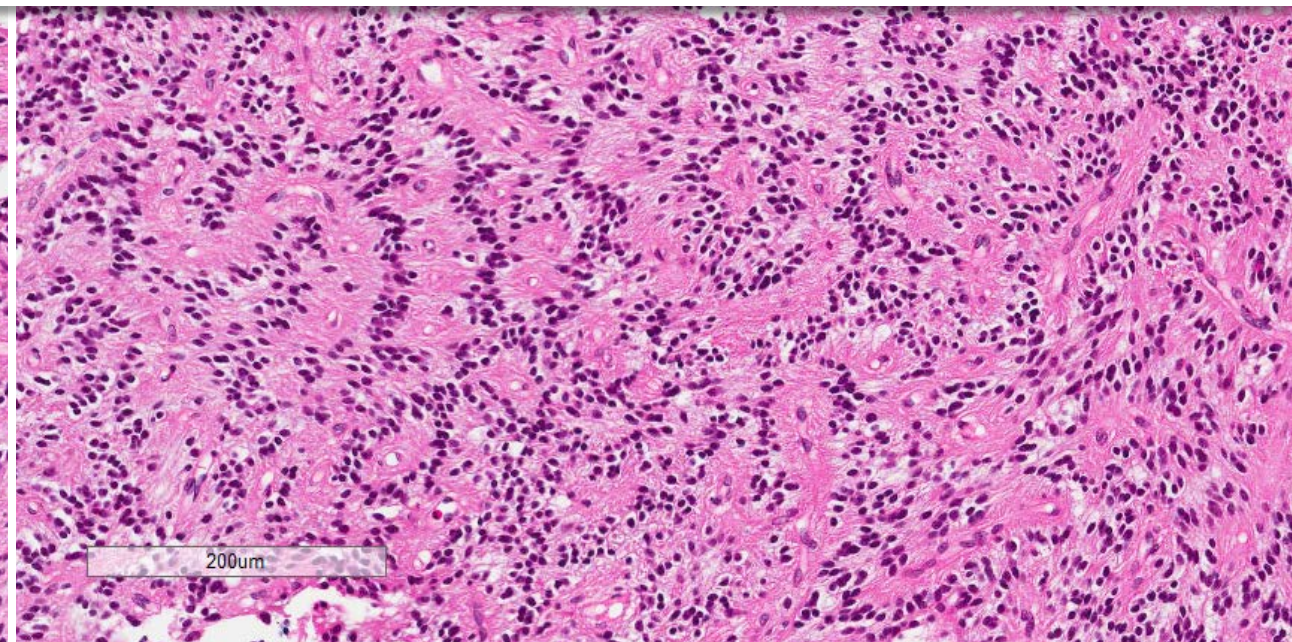
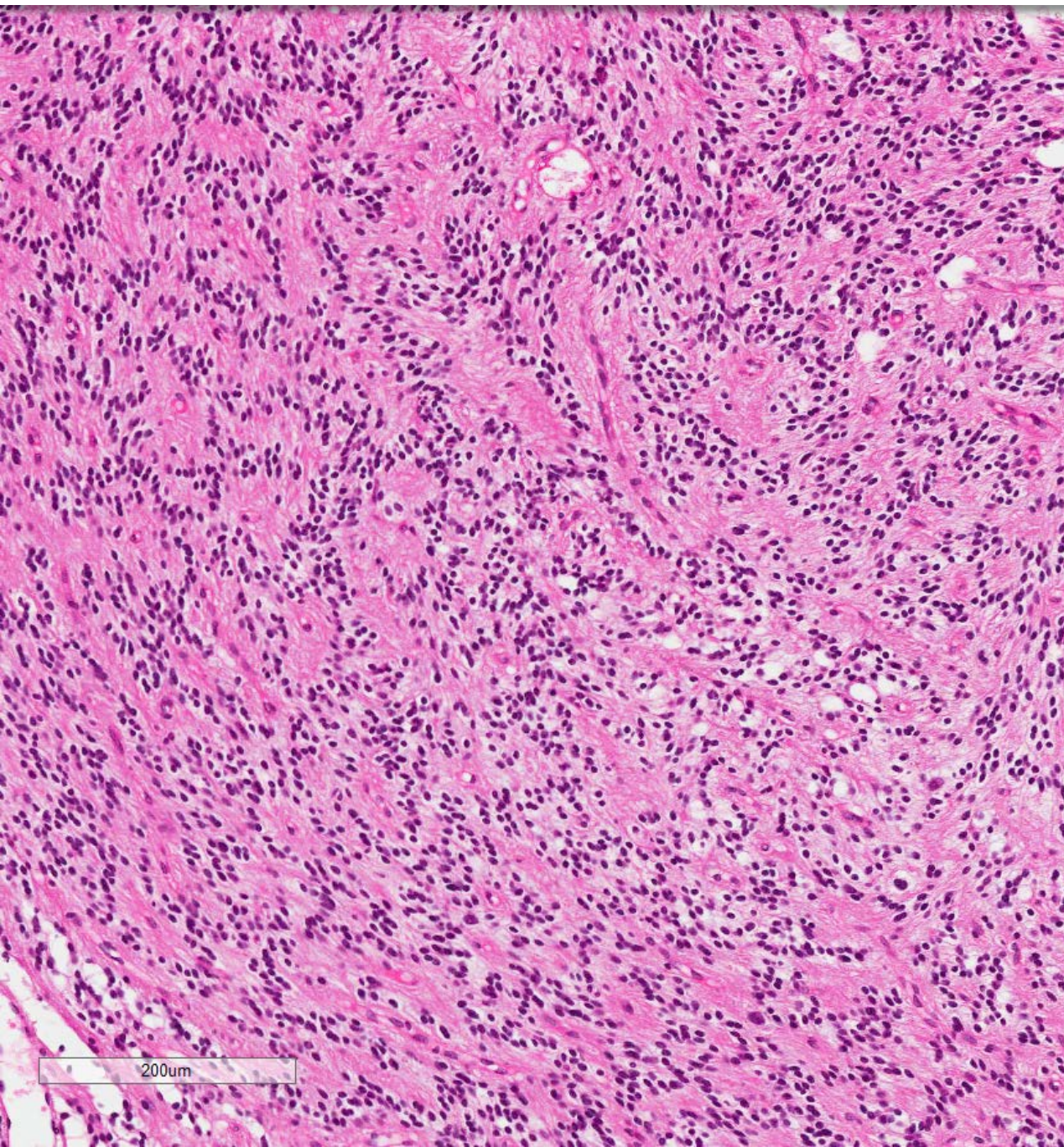
Complex solid-cystic
cortical/subcortical mass
within the left superior
temporal and parieto-
occipital lobes

7.1 x 4.2 x 3.6 cm

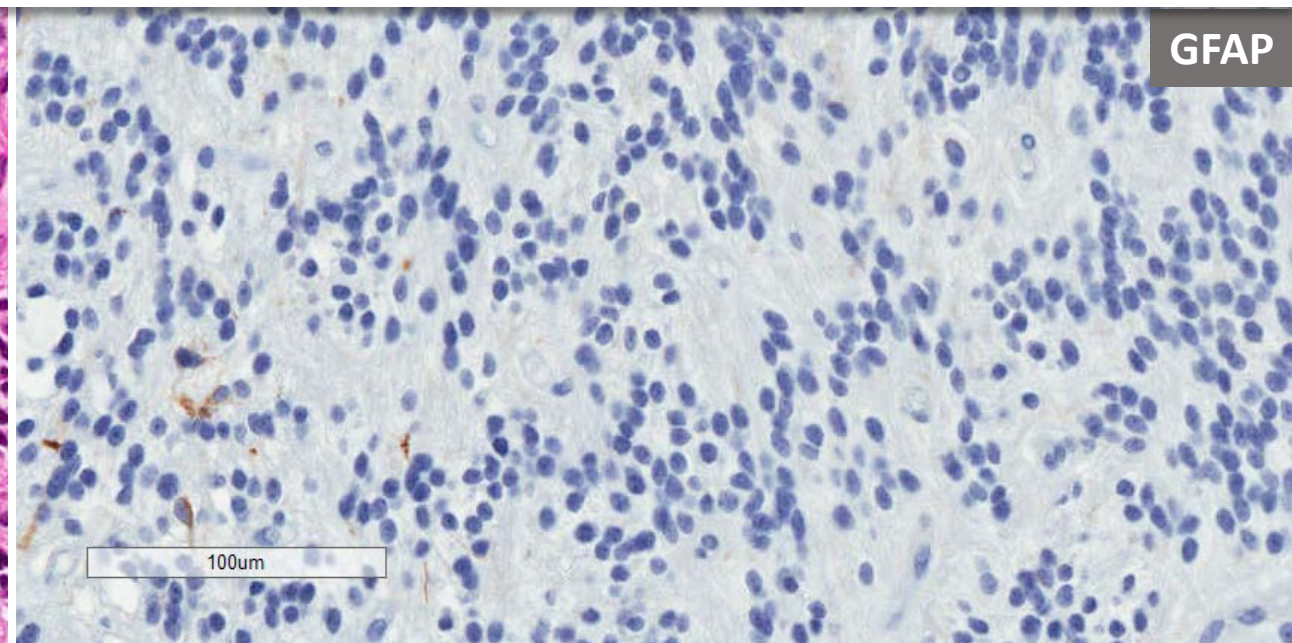
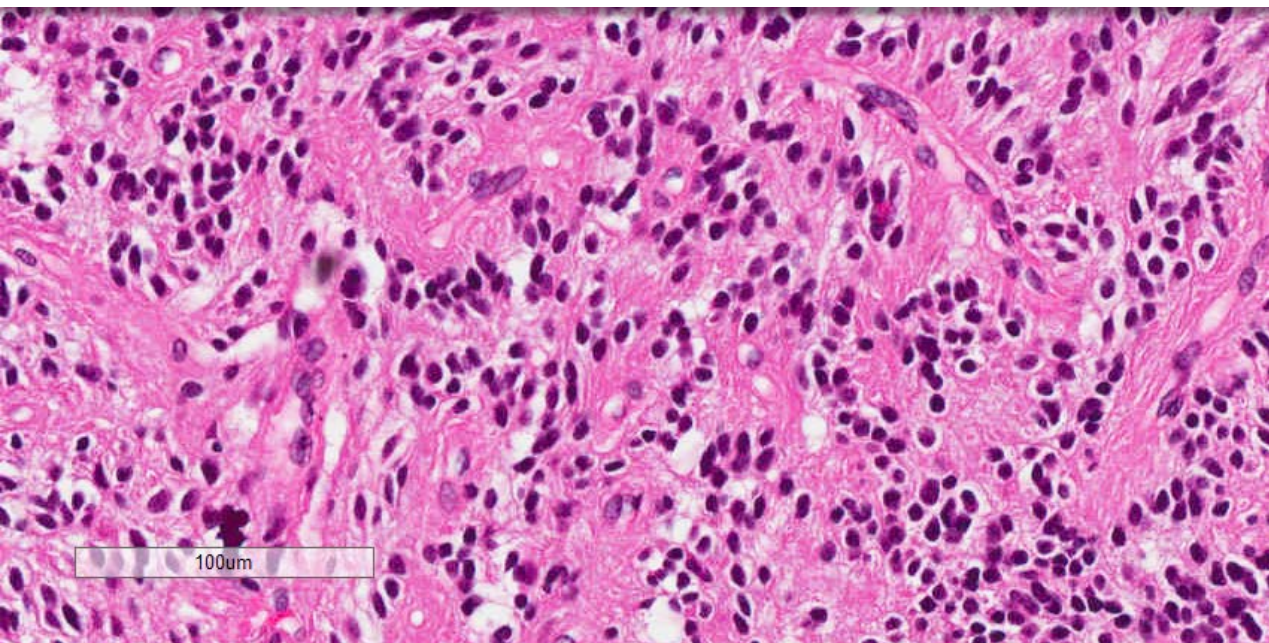
Biopsy (El Salvador): Slide #1



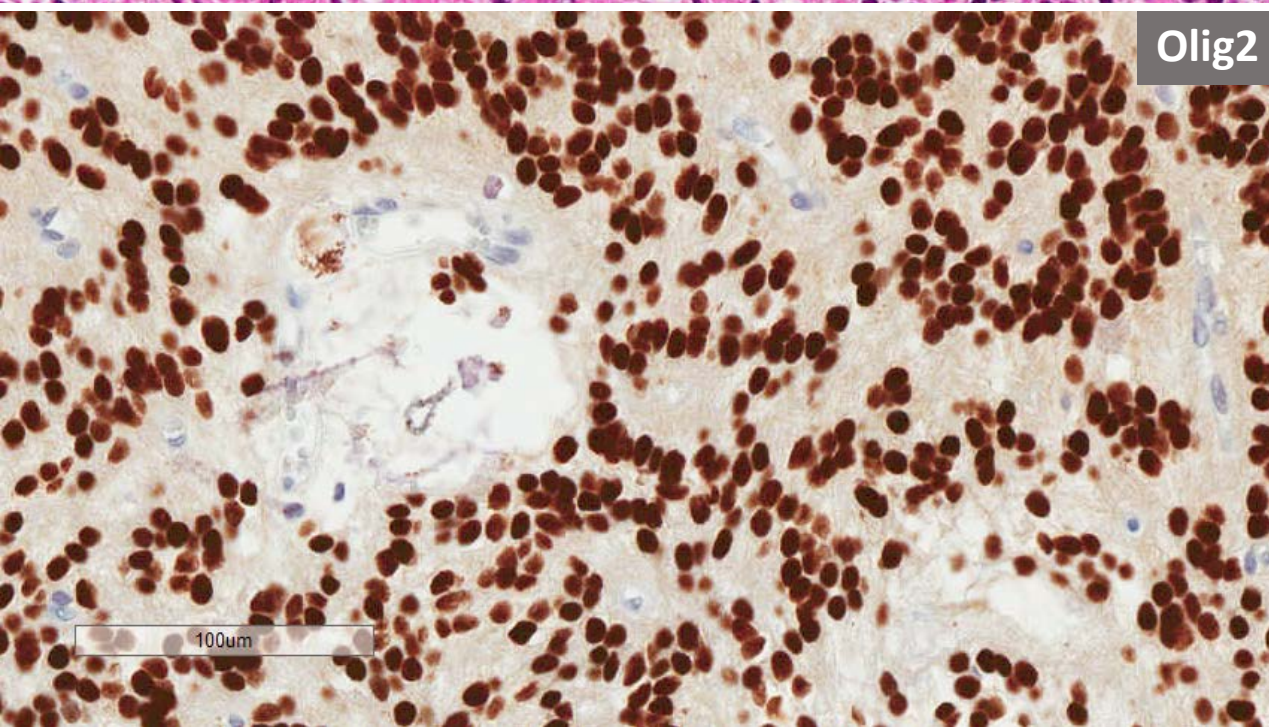
Biopsy (El Salvador): Slide #1



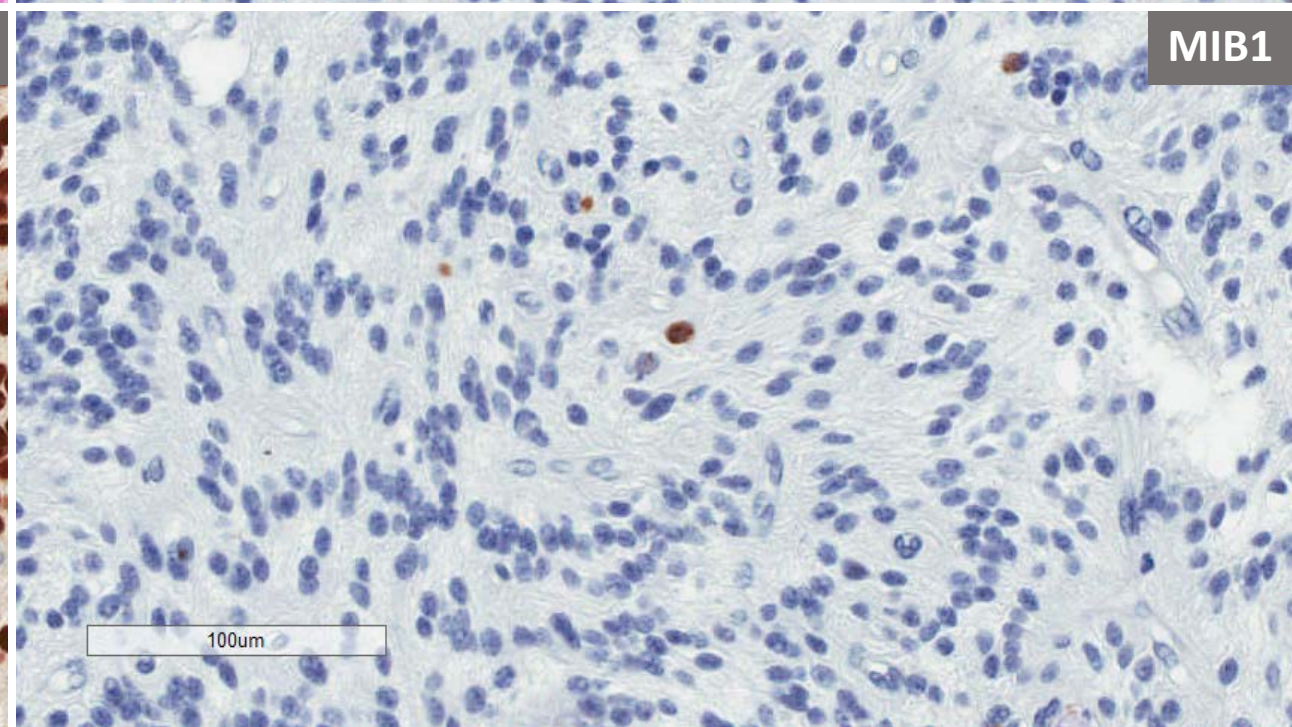
Biopsy (El Salvador): Slide #1



GFAP



Olig2

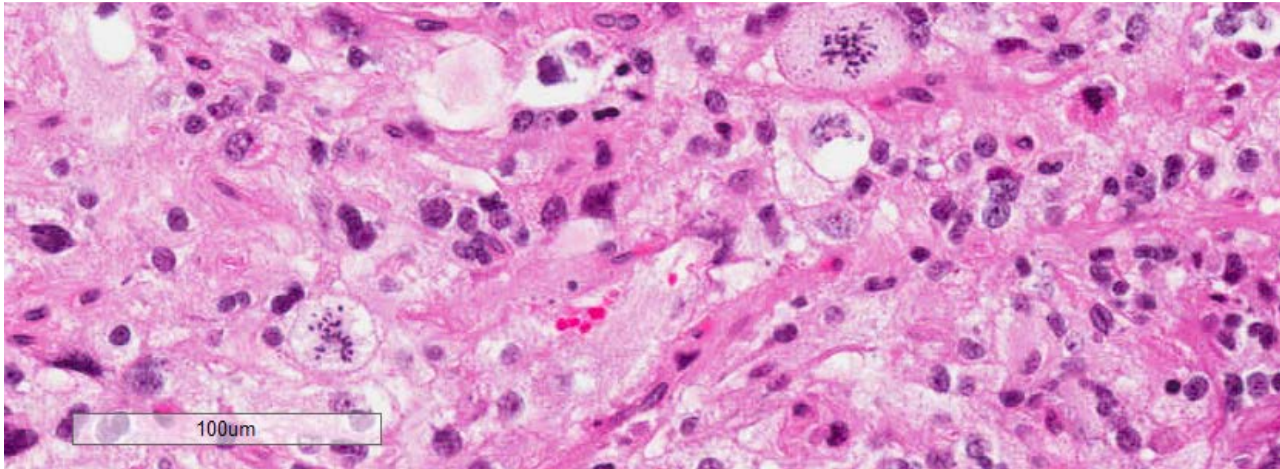
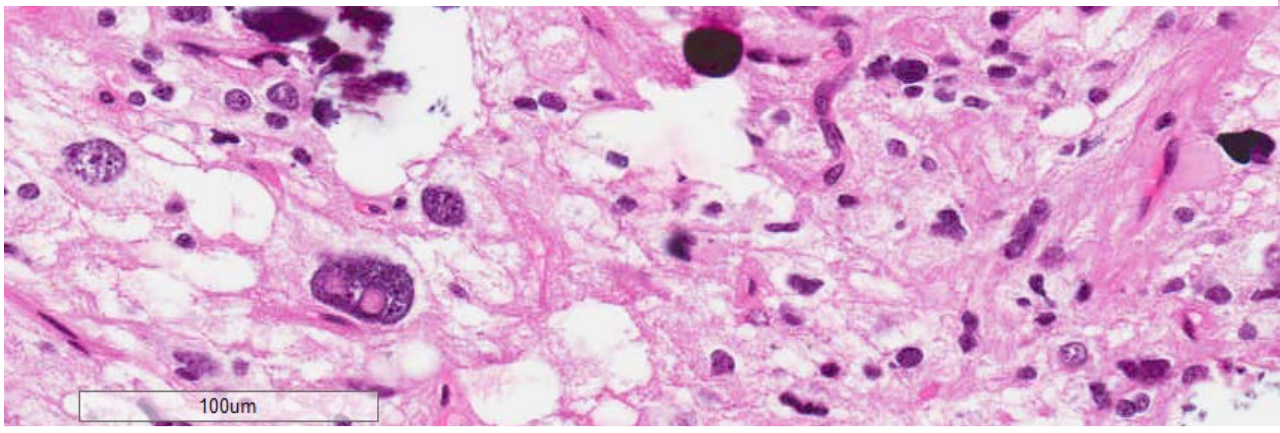
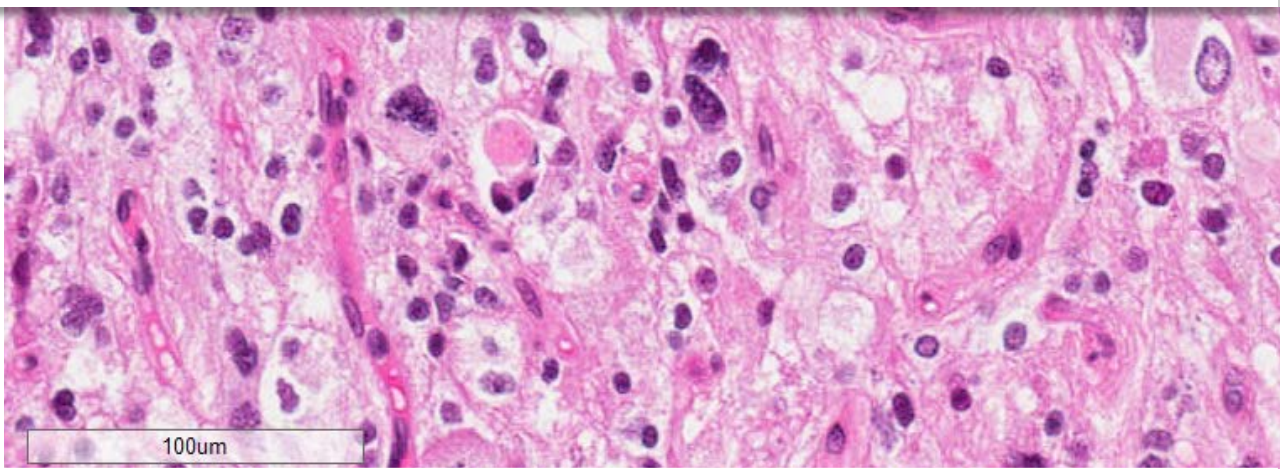
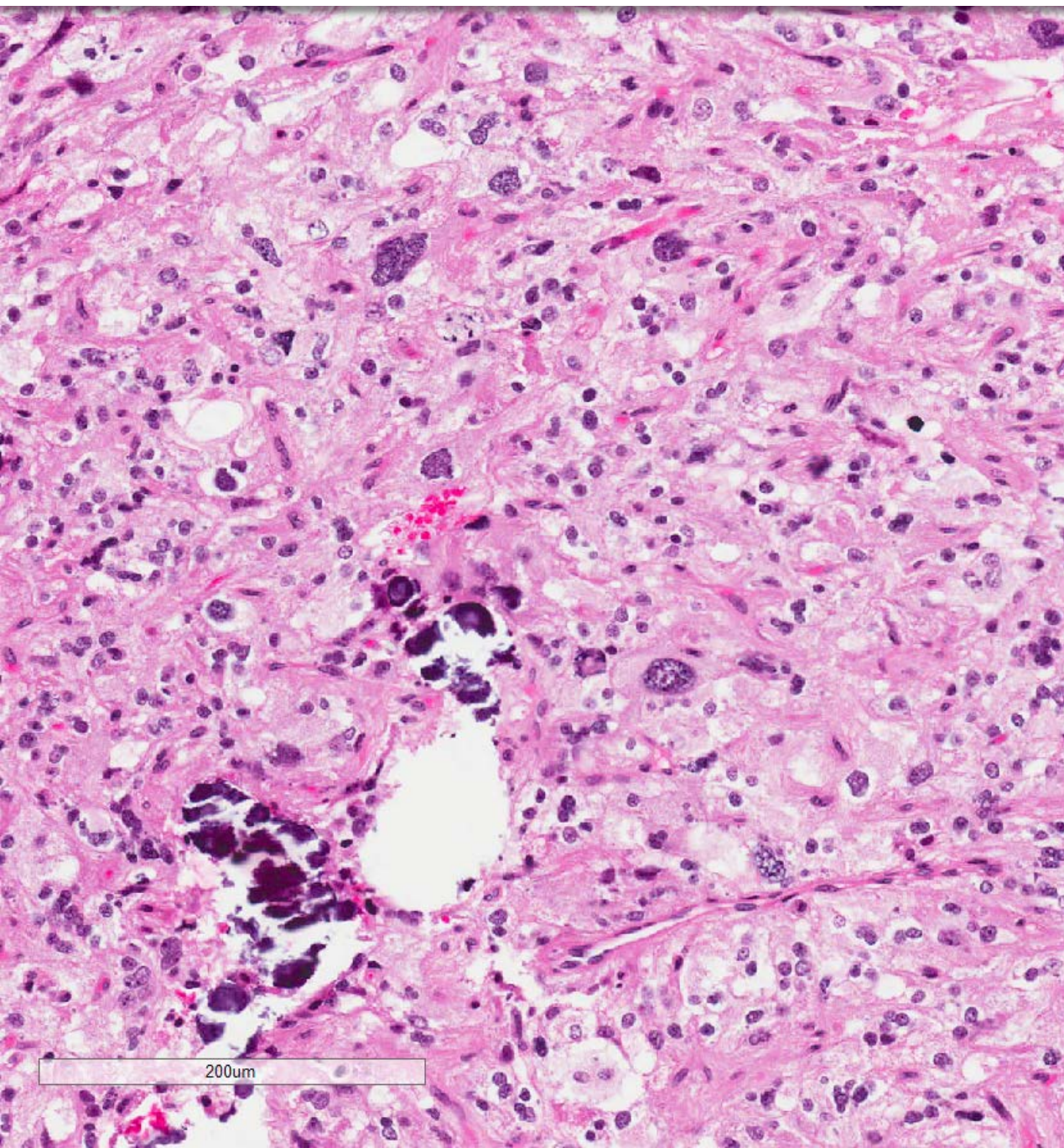


MIB1

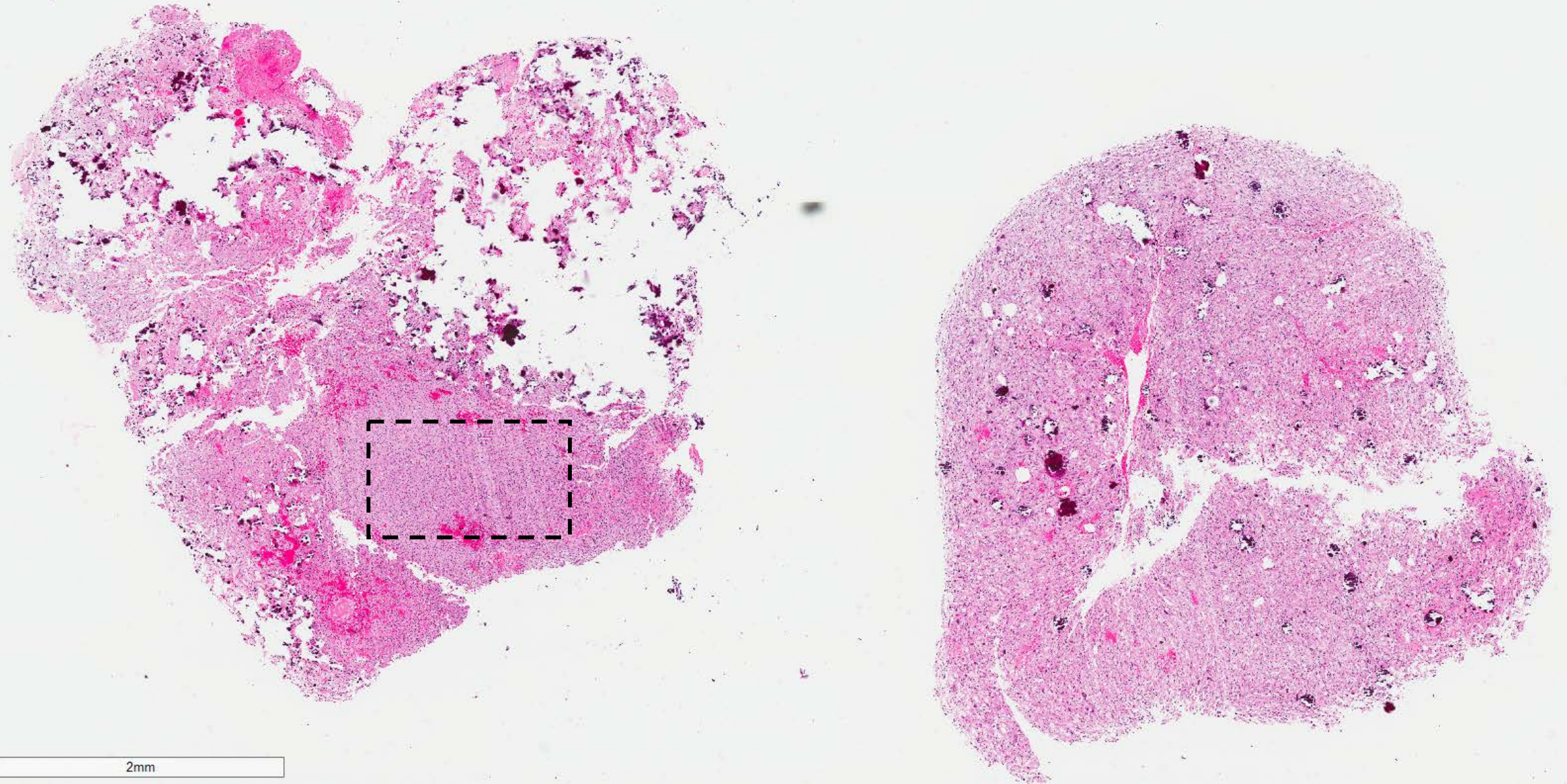
Biopsy (El Salvador) Slide #1: "Oligodendroglioma"

Resection, 6 months later (Sick Kids): Slide #2

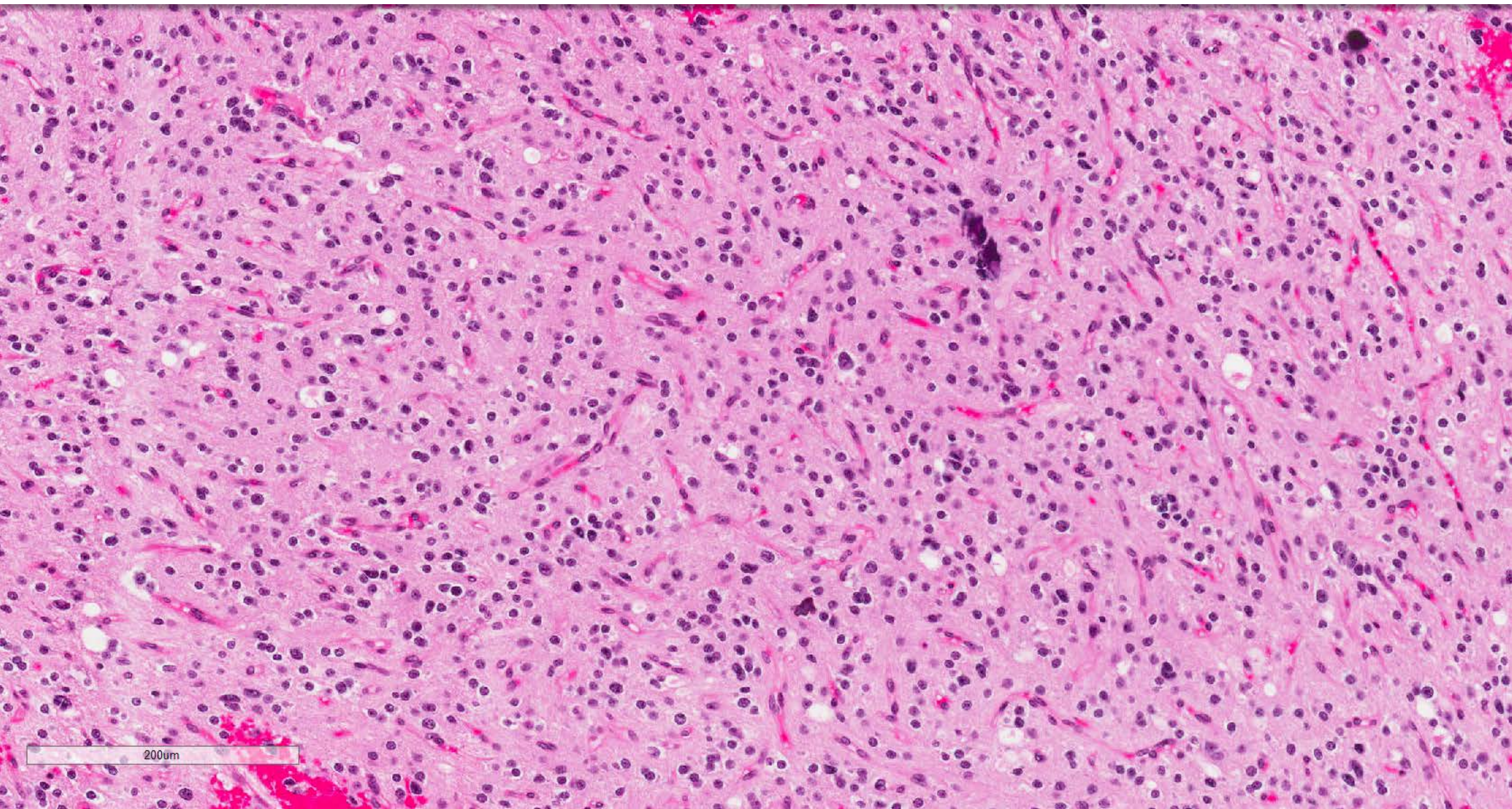
Resection (Sick Kids): Slide #2



Resection (Sick Kids): Another block

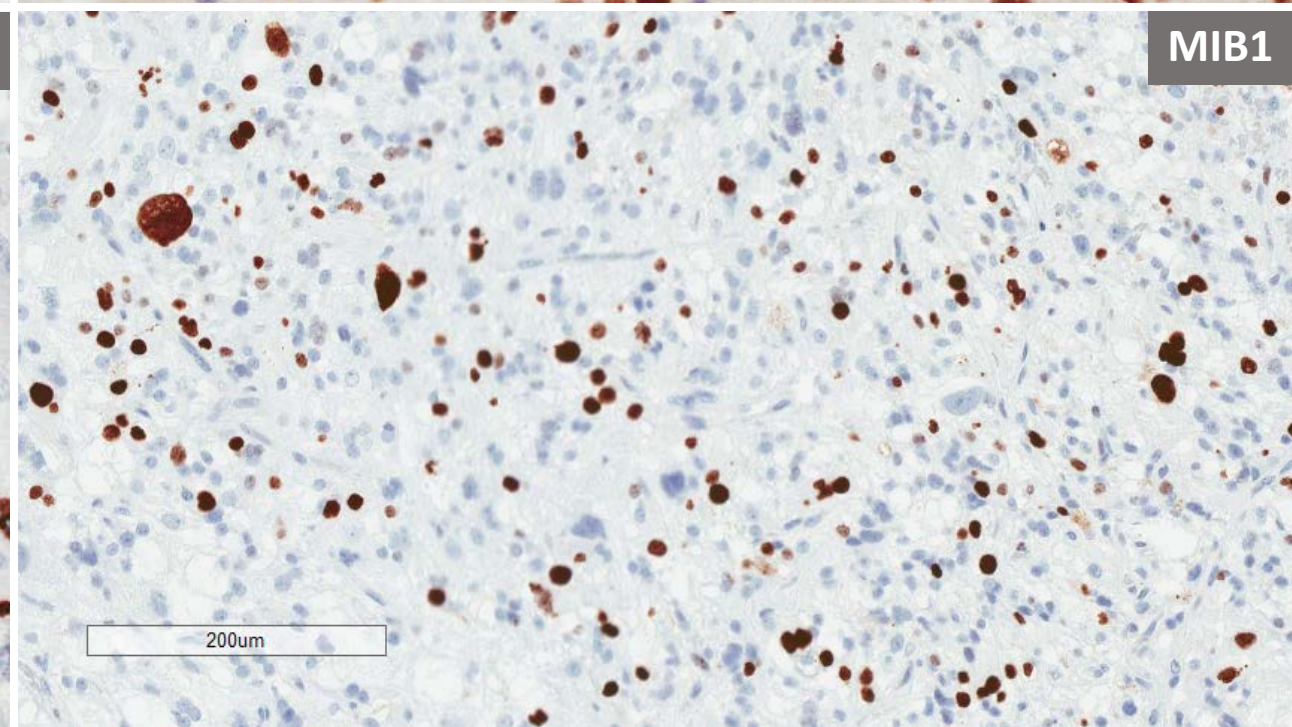
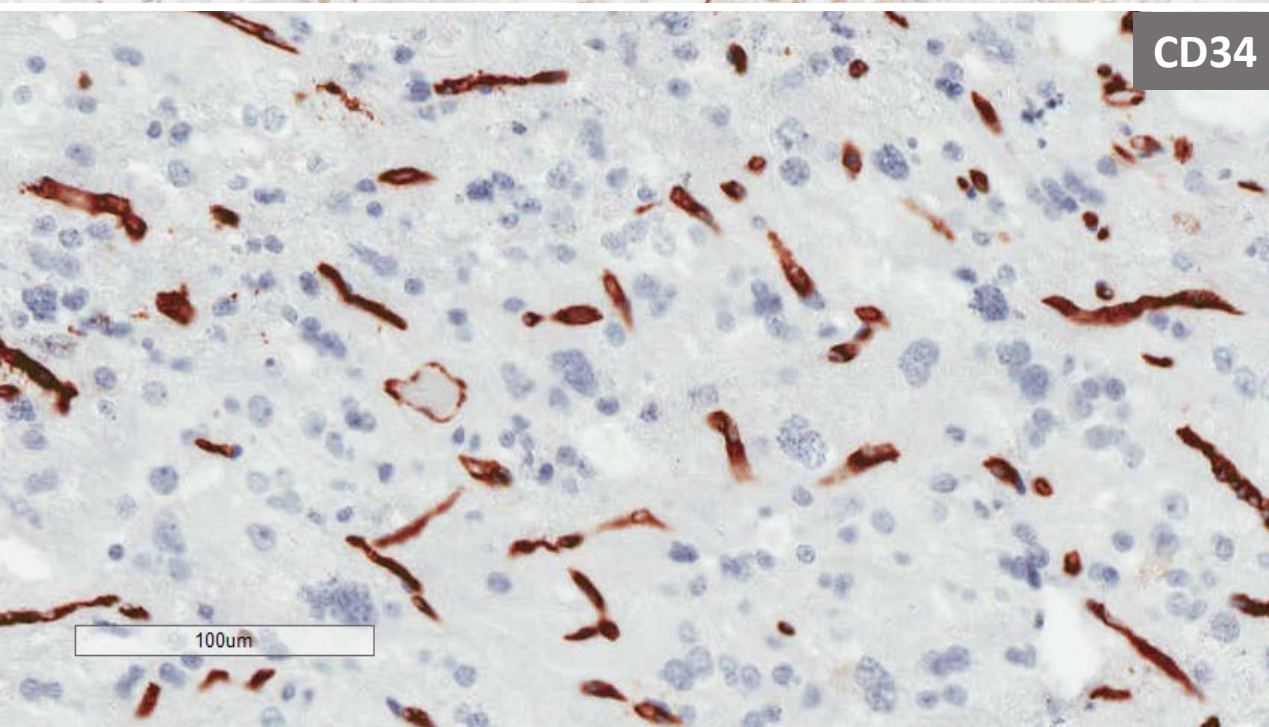
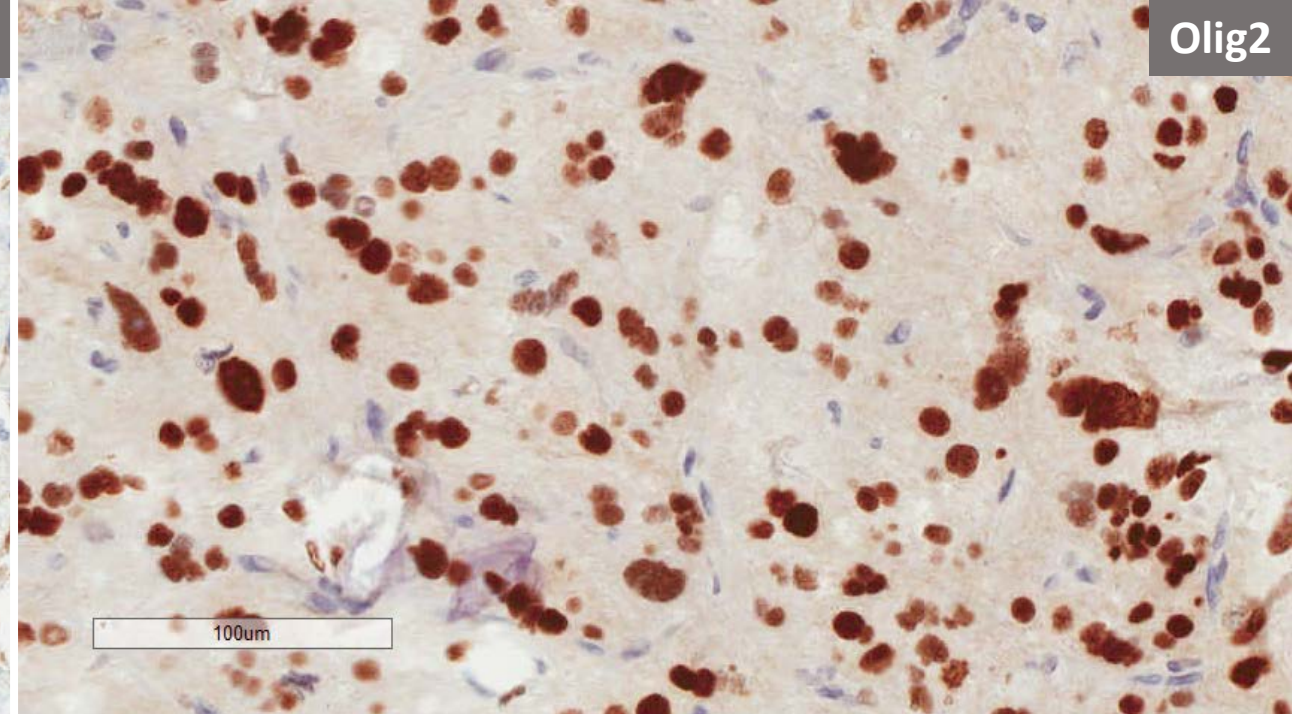
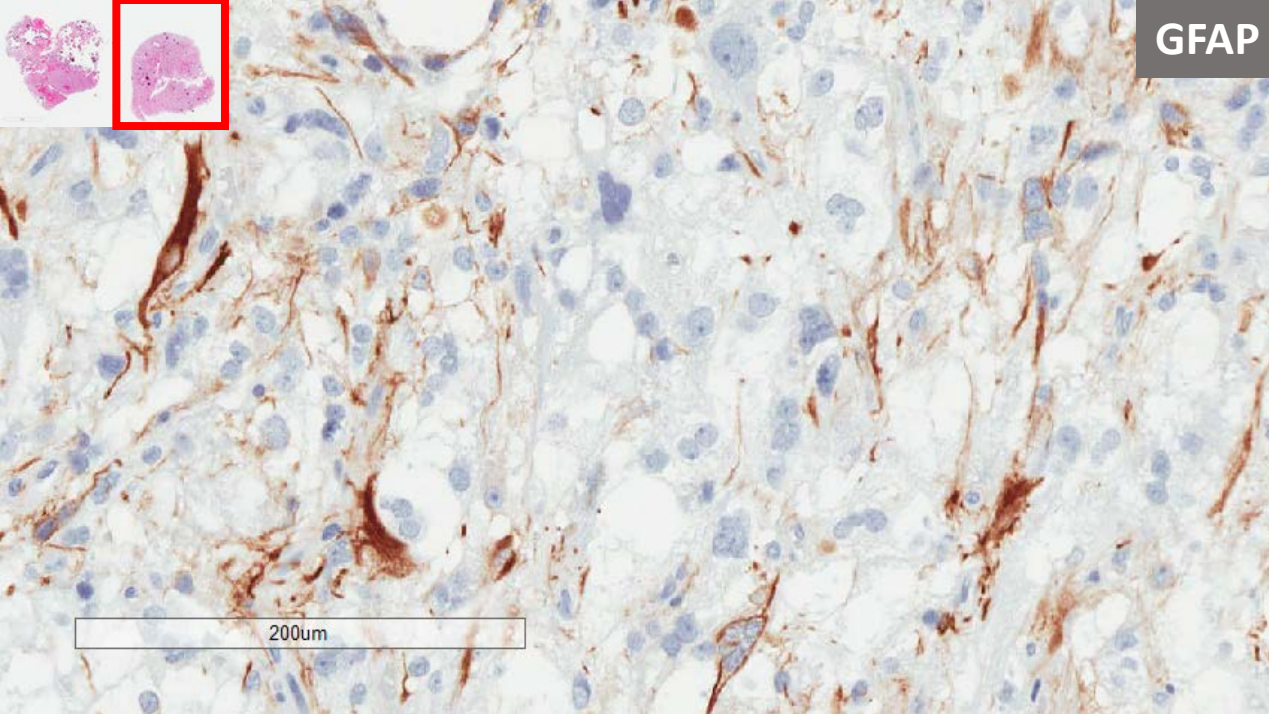


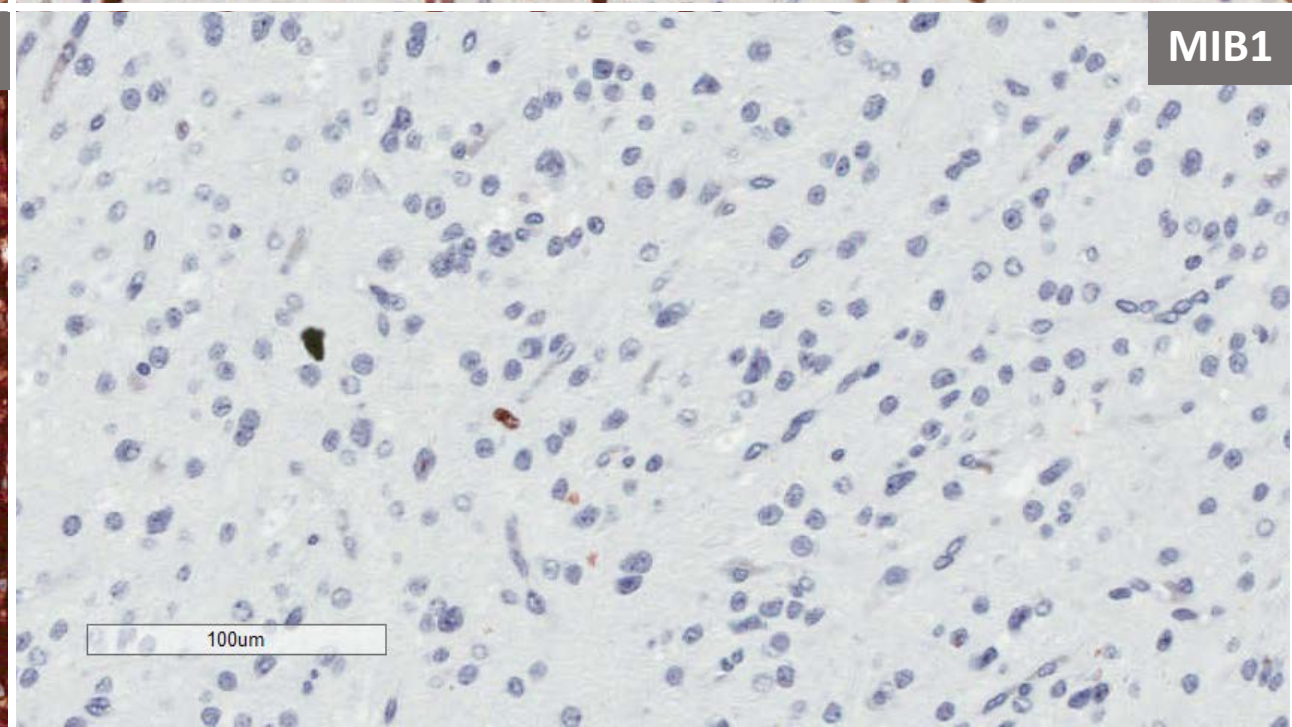
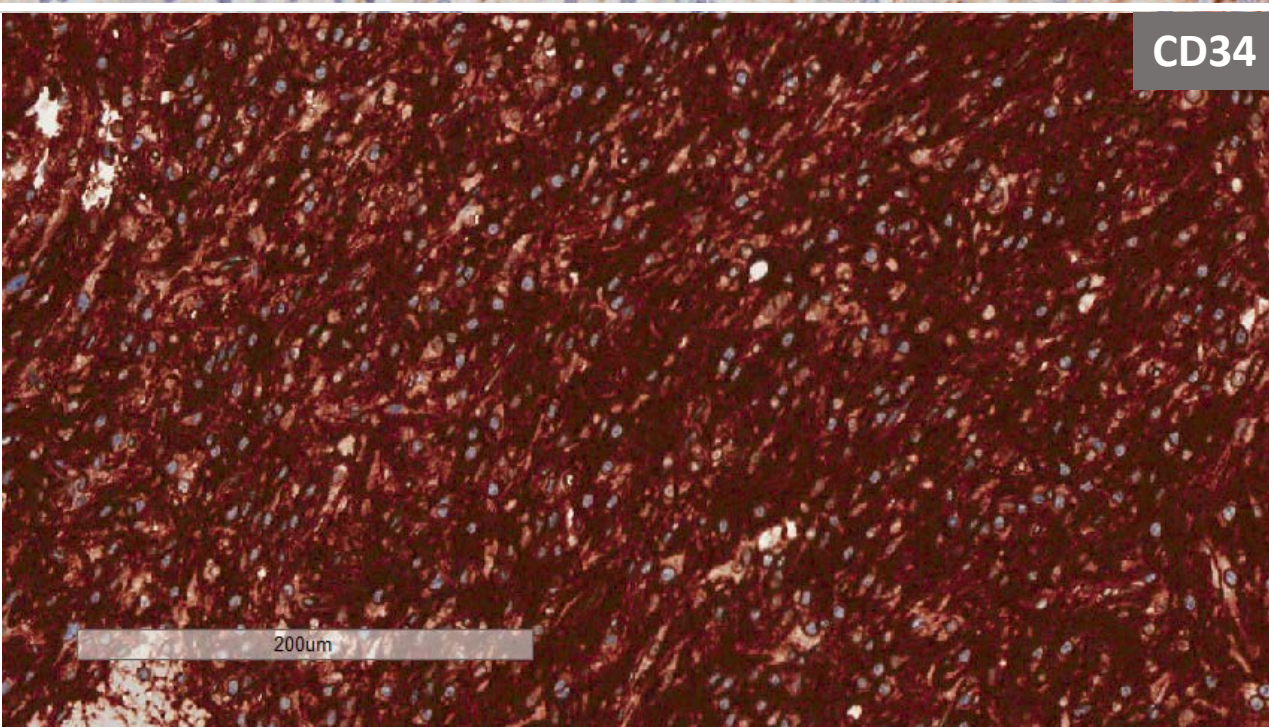
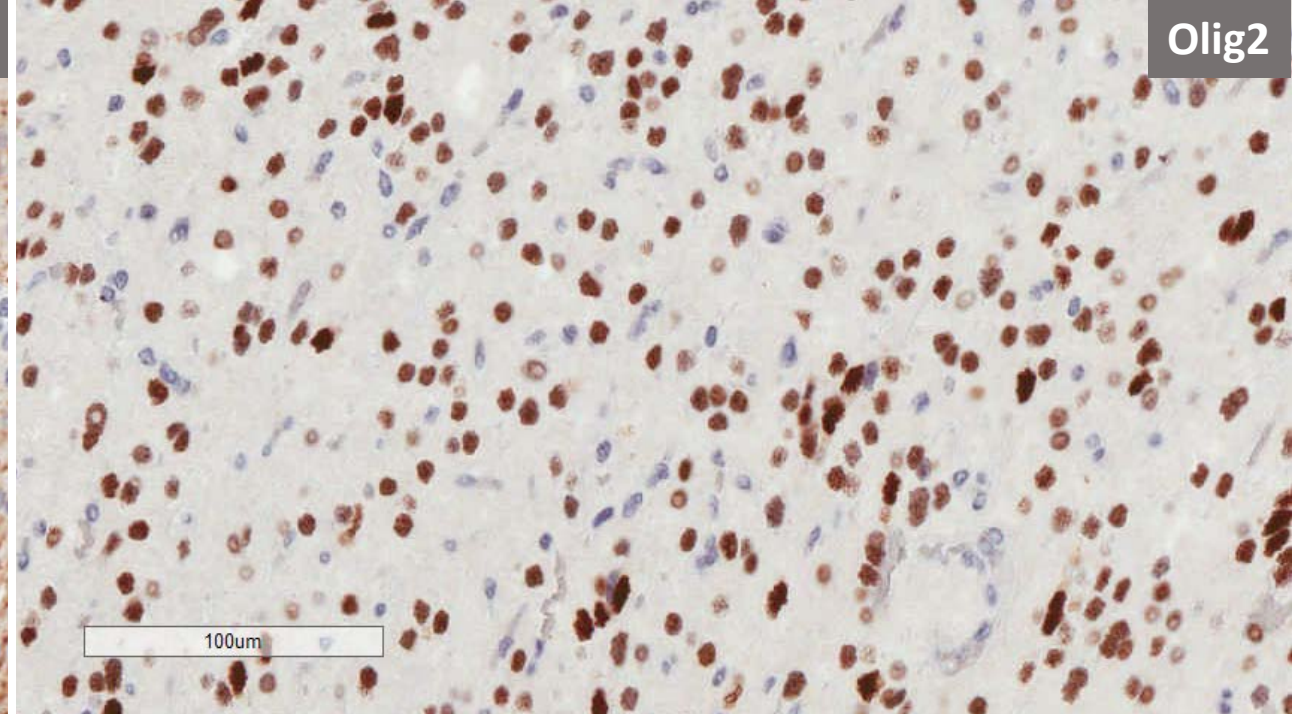
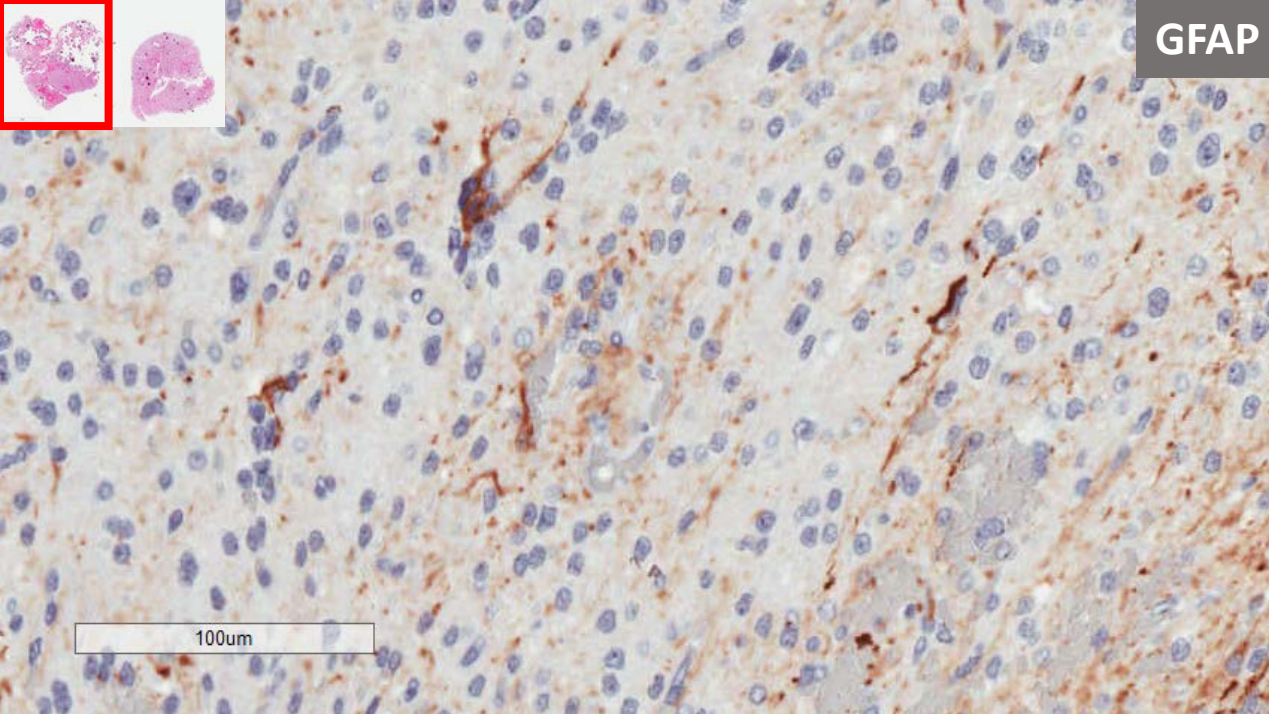
Resection (Sick Kids): Another block



200um

Differential diagnosis?
Additional stains/studies?





Additional stains and molecular pathology

Reticulin negative

1p/19q-codeletion negative

KIAA1549-BRAF fusion negative

EMA negative

Synaptophysin negative

Chromogranin negative

NeuN negative

IDH1 R132H negative

ATRX retained

BRAF V600E negative

Low-grade neuroepithelial tumours

"Adult type"

Diffuse astrocytoma	IDH1/2 ATRX TP53
Oligodendroglioma	IDH1/2 1p/19q -codeletion

DLGNT diffuse leptomeningeal glioneuronal tumour
DNET dysembryoplastic neuroepithelial tumour
PXA pleomorphic xanthoastrocytoma
ITD internal tandem duplication
SNV single nucleotide variant

Adapted from: Chiang and Ellison. J Pathol 2016;241:159-172

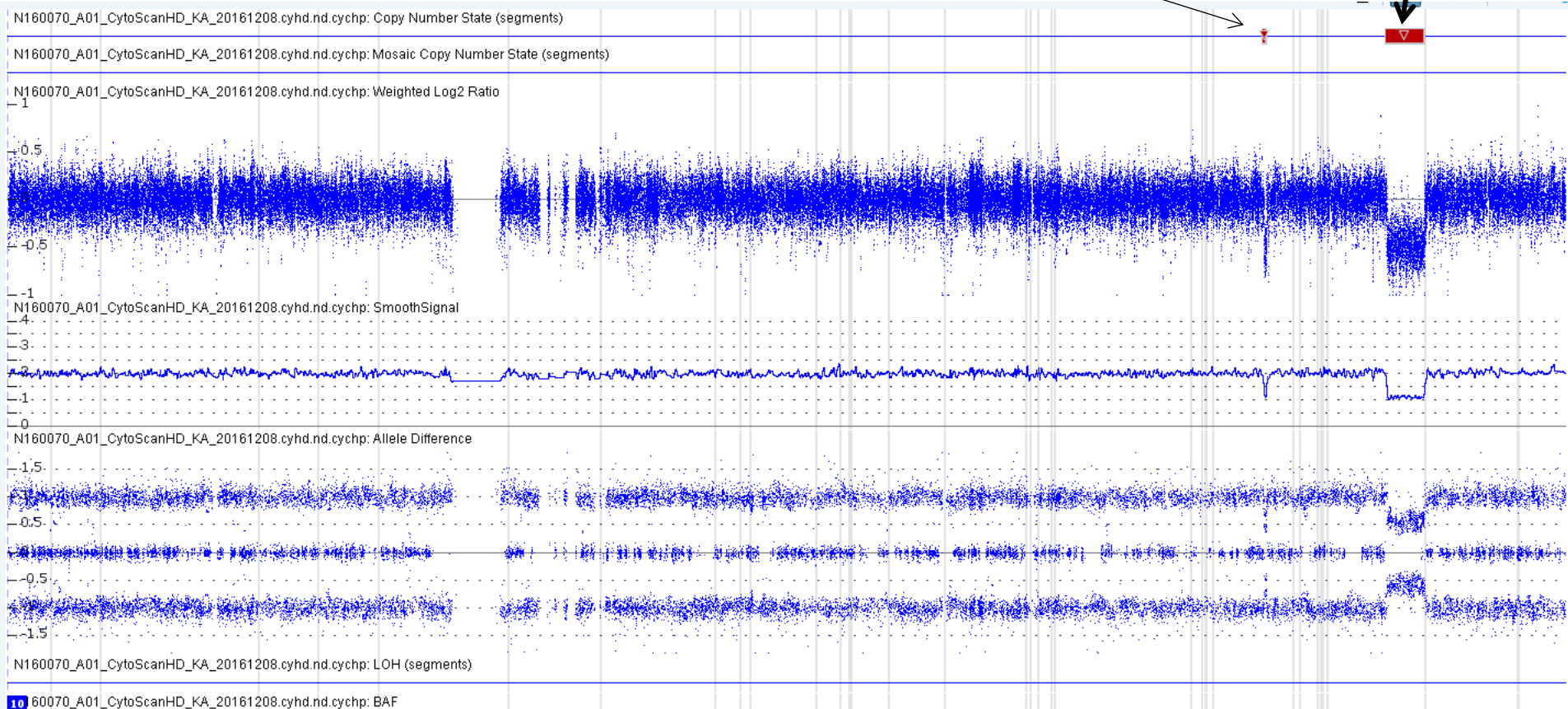
"Pediatric type"

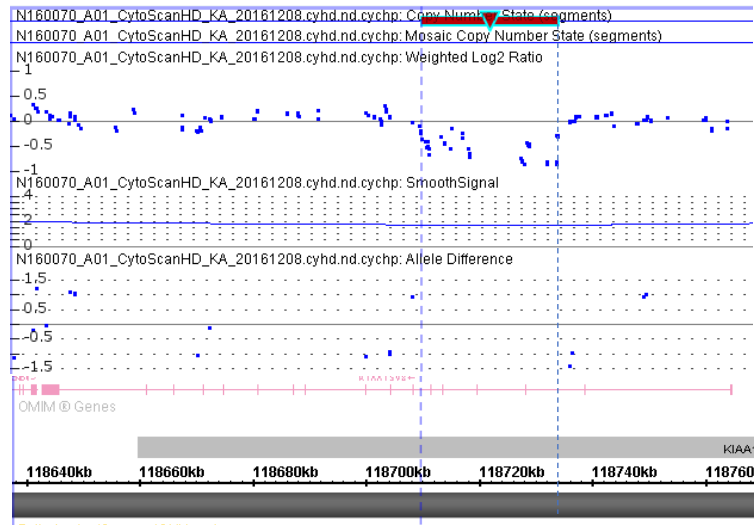
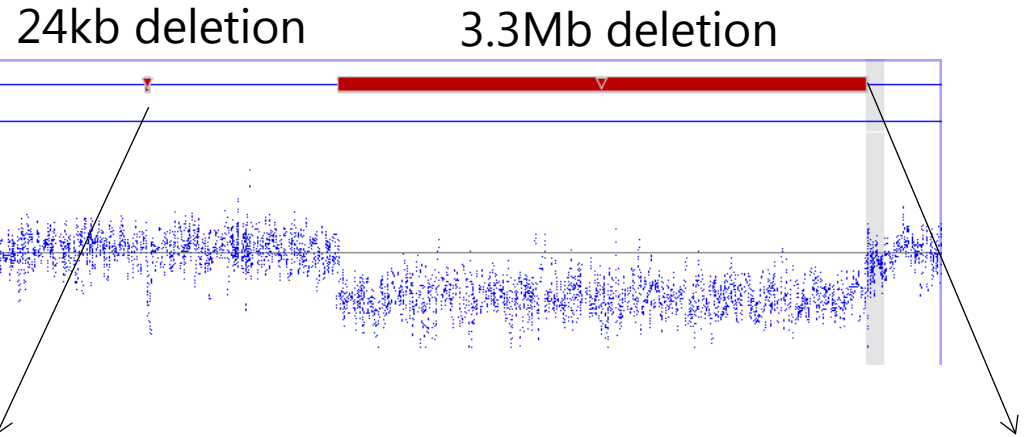
Pilocytic astrocytoma	KIAA1549-BRAF fusion BRAF V600E NF1
Diffuse astrocytoma	MYB/MYBL1 amplification, rearrangement BRAF V600E, fusion FGFR1/3 ITD, fusion
Angiocentric glioma	MYB-QKI fusion
Ganglioglioma	BRAF V600E
PXA	BRAF V600E
Oligodendroglioma	FGFR1 SNV, ITD, fusion
DNET	FGFR1 SNV, ITD
DLGNT	KIAA1549-BRAF fusion and 1p deletion

Chromosome 10

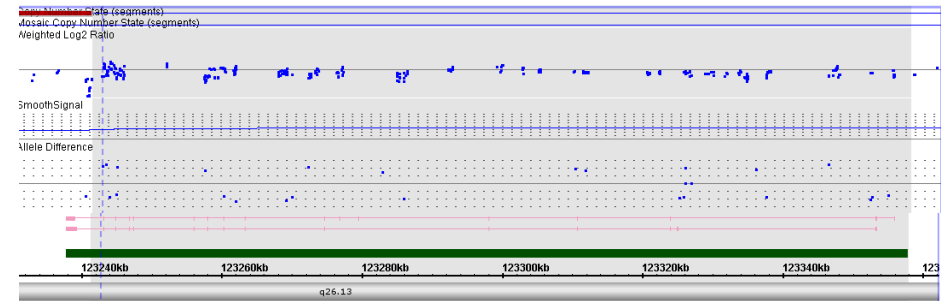
223kb deletion with no coding gene

3.3Mb deletion



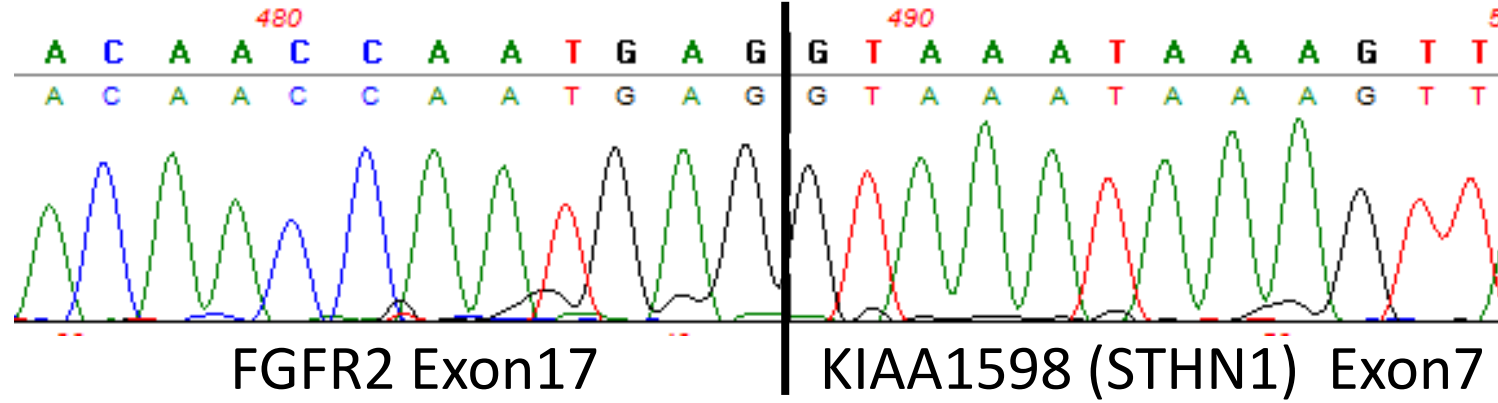


KIAA1598 (SHTN1) <- NM_001127211
 Breakpoint: Intron 6/16 = between exons 6 and 7
 Breakpoint: Intron 2/16 = between exons 2 and 3

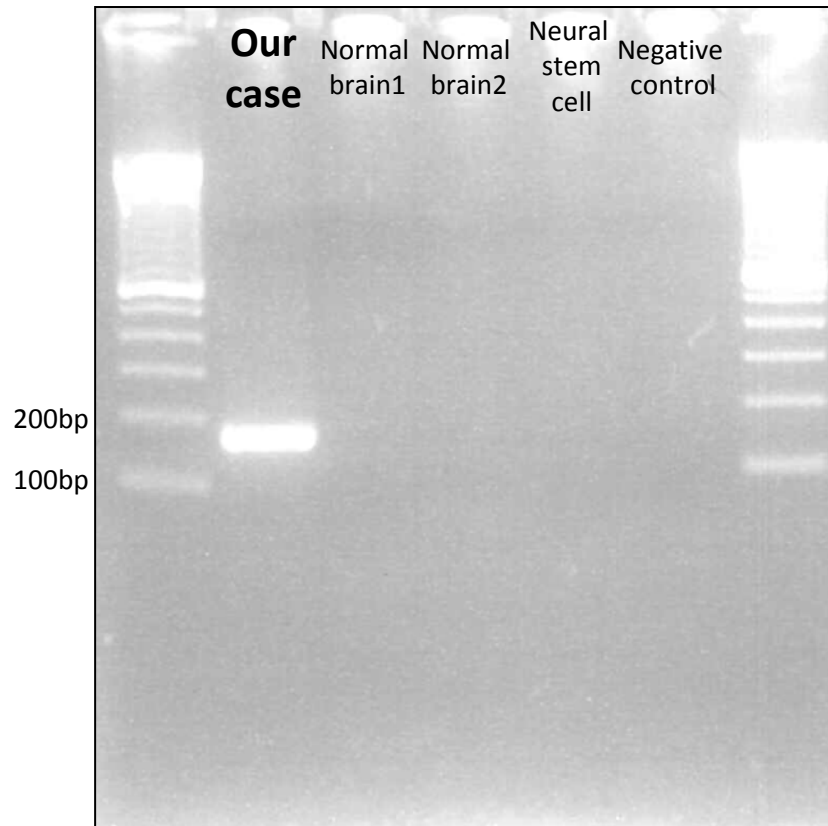


FGFR2 <- NM_001144915
 Breakpoint: Intron 16/16 = between exons 16 and 17

Sanger sequencing



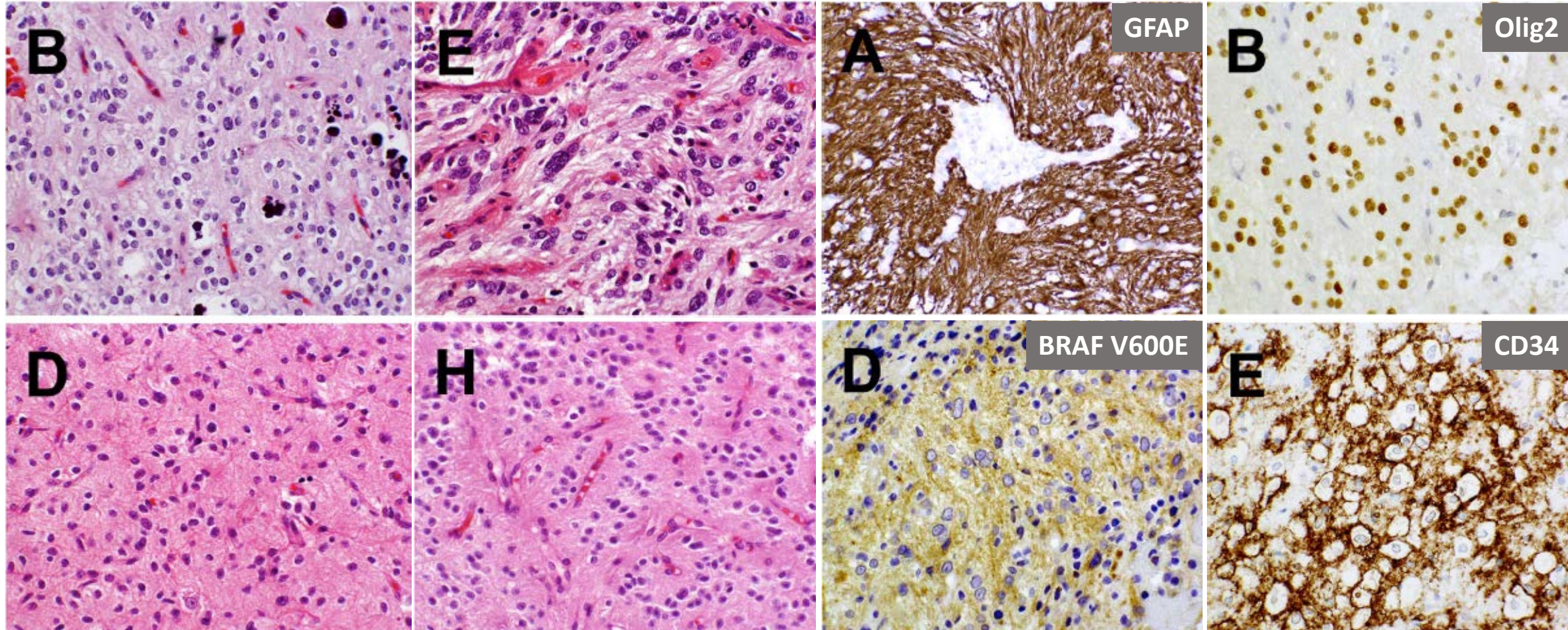
RT-PCR



FGFR2(ex17)-KIAA1598(ex7) fusion

Polymorphous low-grade neuroepithelial tumor of the young (PLNTY):

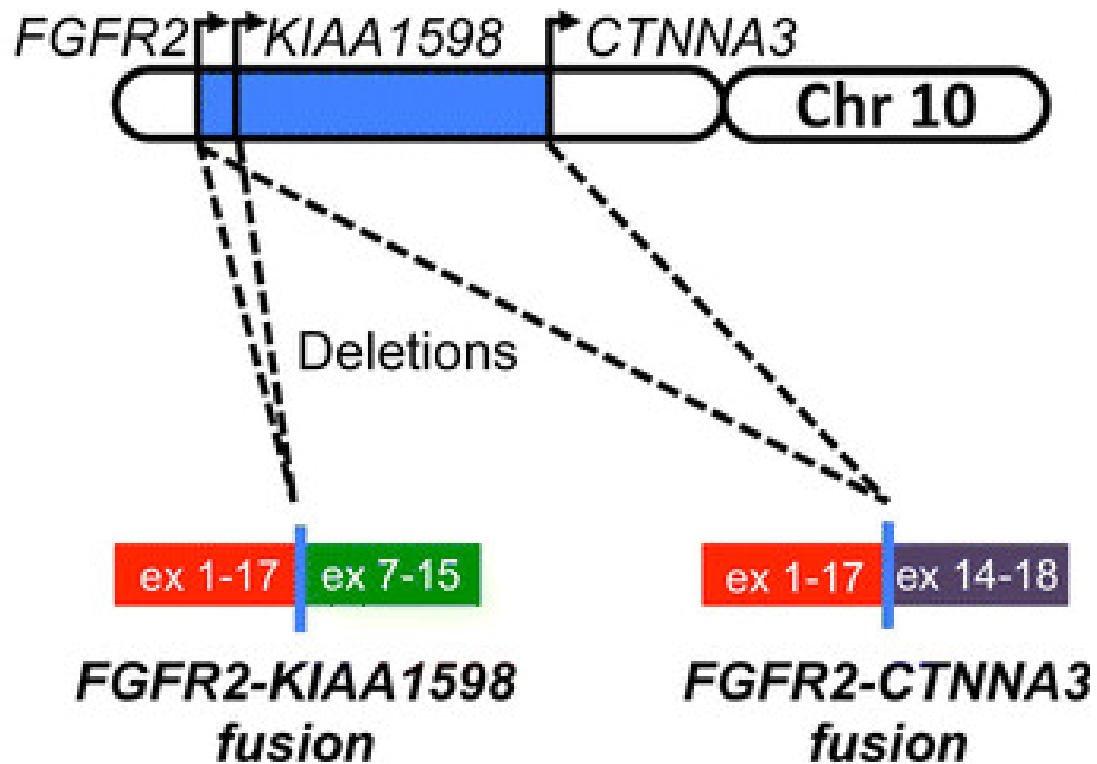
an epileptogenic neoplasm with oligodendroglioma-like components, aberrant CD34 expression, and genetic alterations involving the MAP kinase pathway



Polymorphous low-grade neuroepithelial tumor of the young (PLNTY): an epileptogenic neoplasm with oligodendroglioma-like components, aberrant CD34 expression, and genetic alterations involving the MAP kinase pathway

Table 1 Demographic, clinical, and molecular features of PLNTYs

Case #	Age at Dx (years)	Gender	Clinical presentation	Duration	Location	Treatment	Follow-up (months)	Outcome	BRAF mutation	Fusion transcripts
1	16	M	Seizures	>2 years	R med temporal	GTR	53	NED, no seizures	BRAF V600E	
2	18	F	Seizures	1 year	R med temporal	STR	18	Post-op psychosis, now SD	BRAF V600E	
3	23	F	Seizures	Unknown	R temporal	N/A	N/A	N/A	BRAF V600E	
4	17	F	Seizures	Unknown	R temporal	GTR	89	NED, no seizures	Neg	FGFR3-TACC3
5	4	M	Seizures	Unknown	L temporal	GTR	86	NED, no seizures	Neg	FGFR2-CTNNA3
6	9	M	Seizures	6 years	R frontal	GTR	36	New seizures and MRI abnormality after 36 months	Neg	FGFR2-KIAA1598 ^a
7	10	M	HA/dizziness	6 days	R occipital	GTR	62	NED	Neg	FGFR2-KIAA1598
8	23	F	Seizures	N/A	R medial temporal	GTR	12	NED	Neg	
9	32	F	Seizures	26 years	R temporal	GTR	55	NED, no seizures	N/A	
10	24	F	Visual disturbances	2 years	R occipital	GTR	12	NED	N/A	

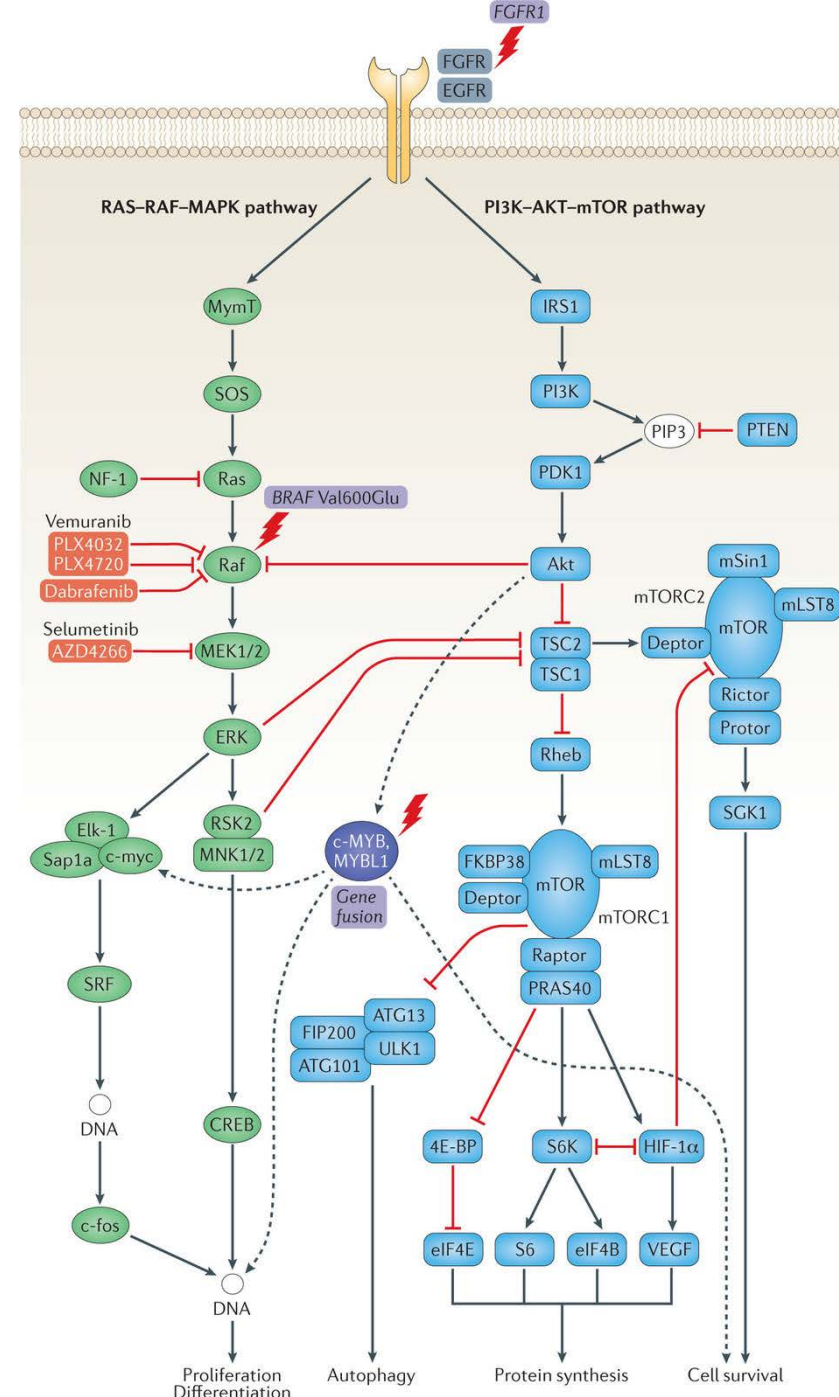


Coiled coil domain in KIAA1598

Constitutive dimerization

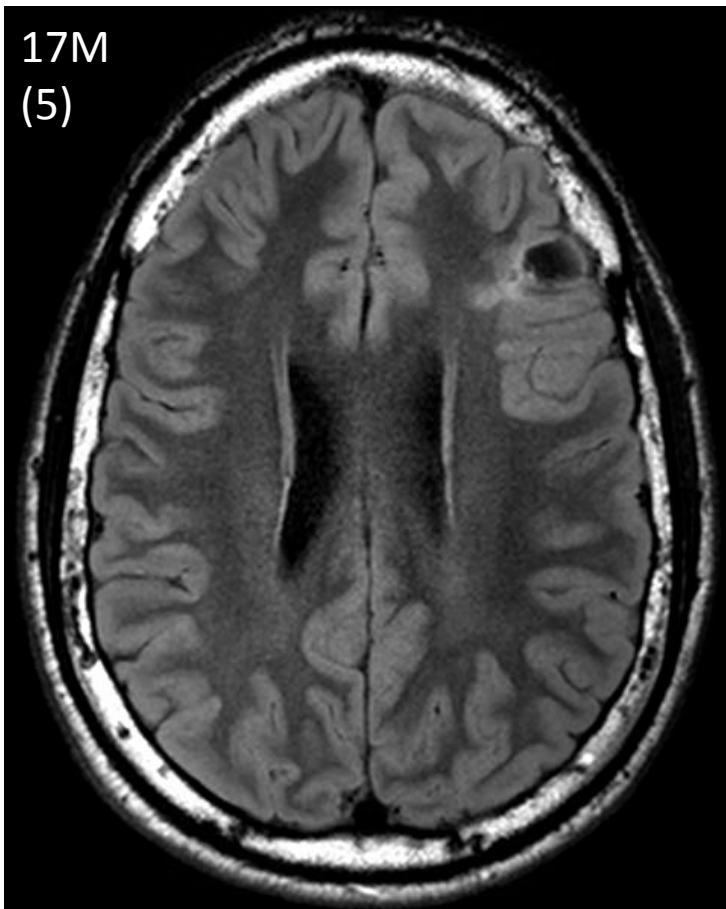
Autophosphorylation

Activation

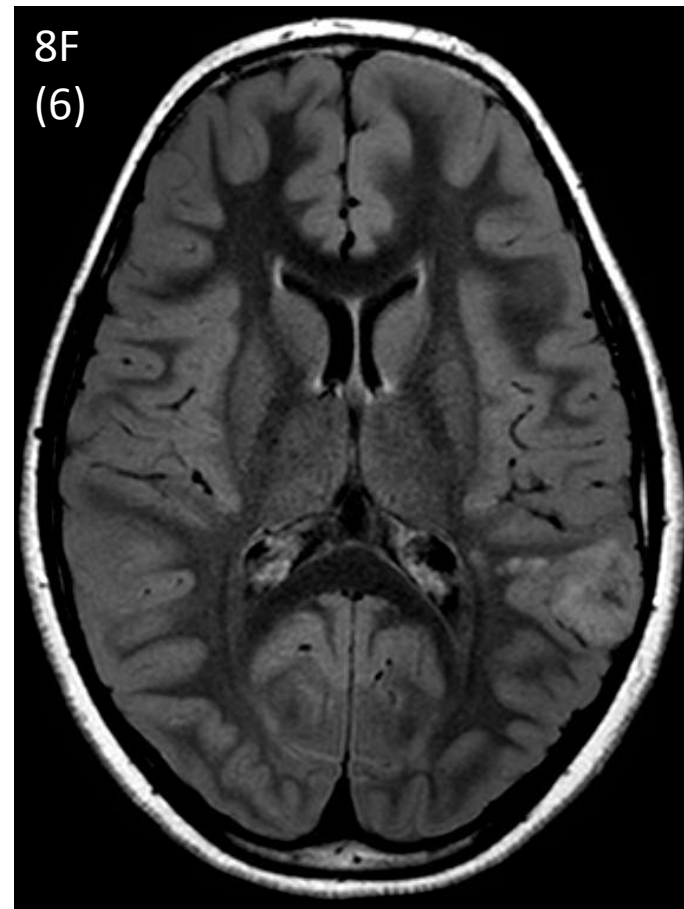

Sick Kids archive

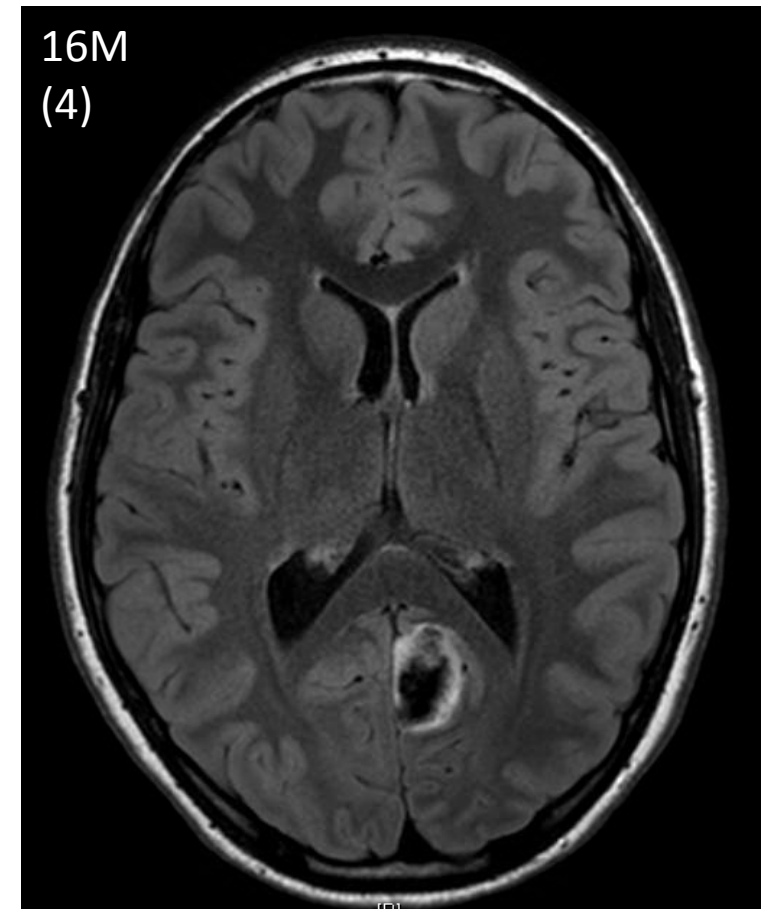
FGFR2(ex17)-INA(ex2)



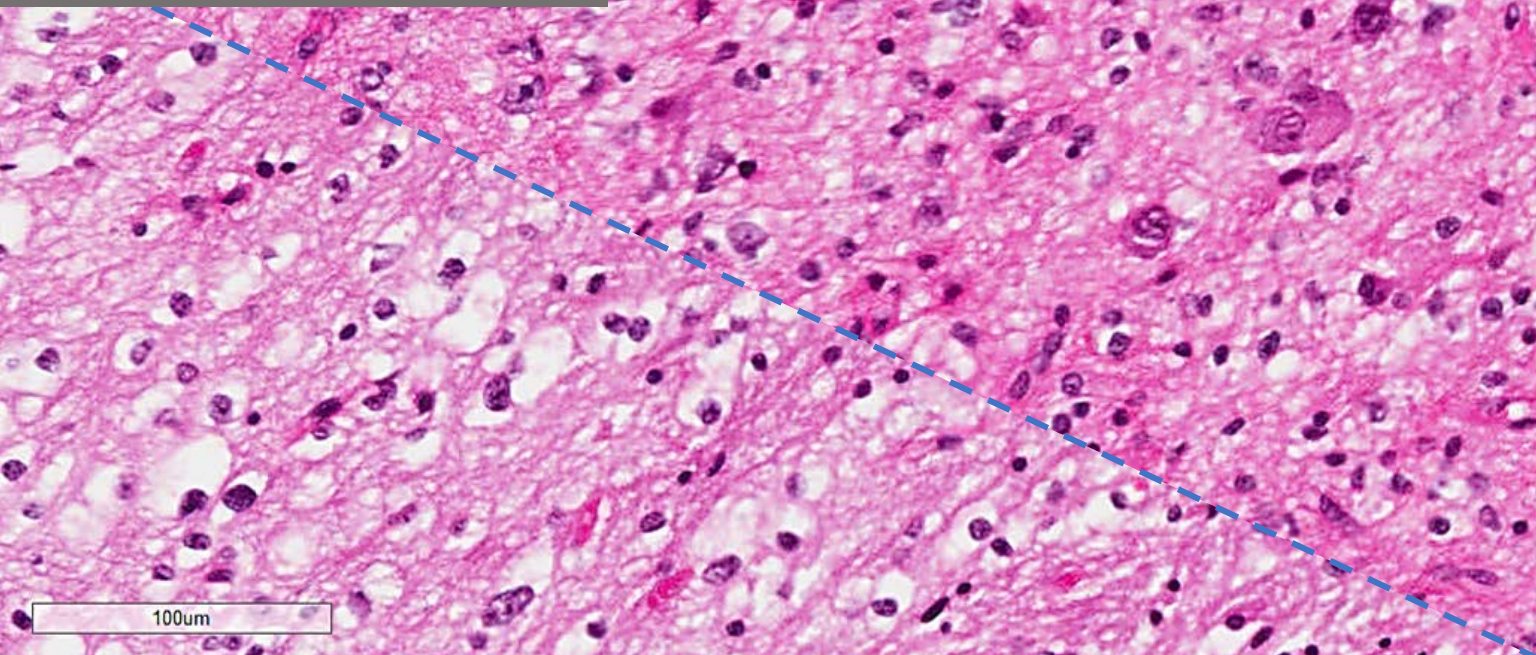
FGFR2(ex17)-CTNNA3(ex14)



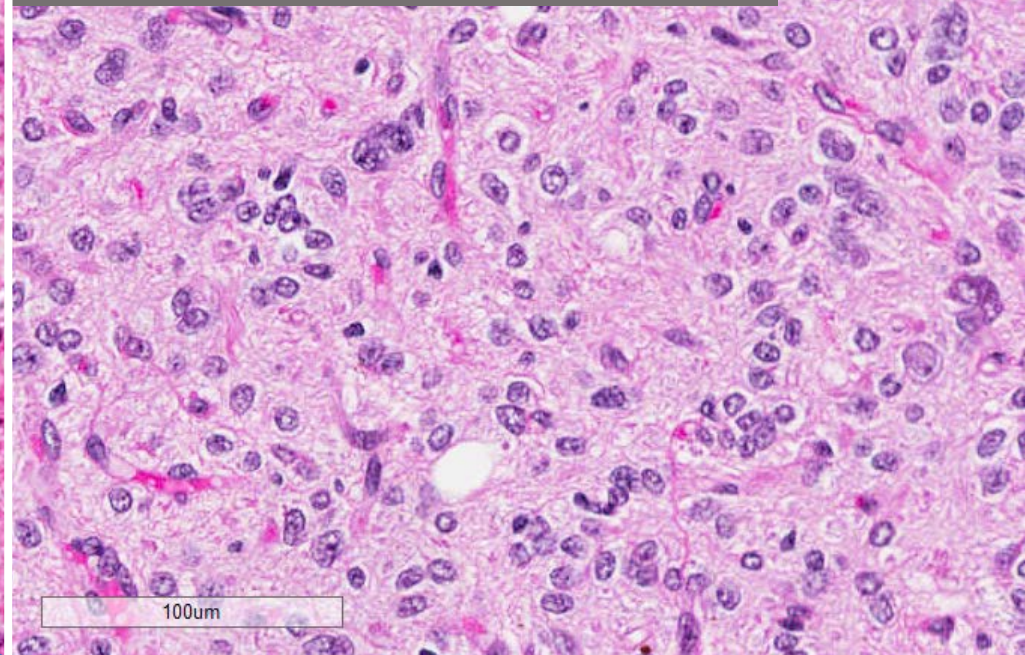
FGFR2(ex18)-ERC1(ex2)



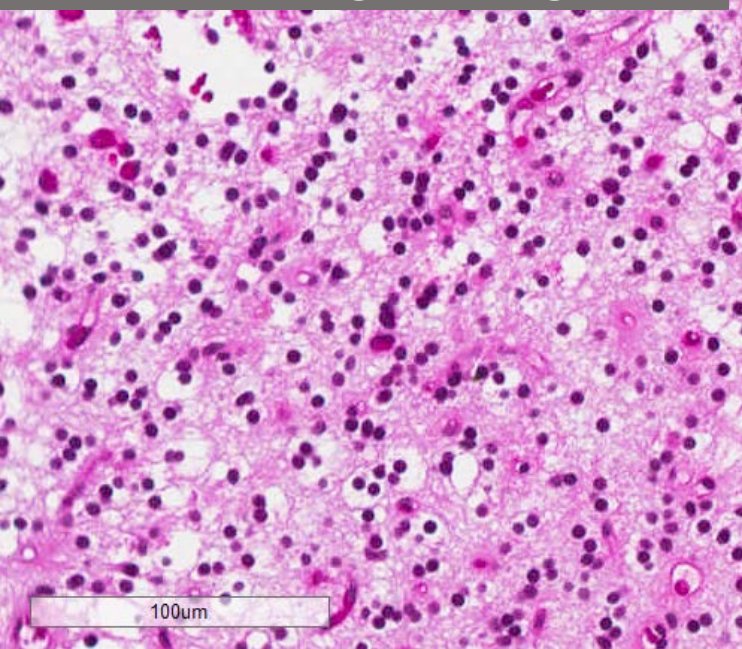
FGFR2-INA "ganglioglioma"



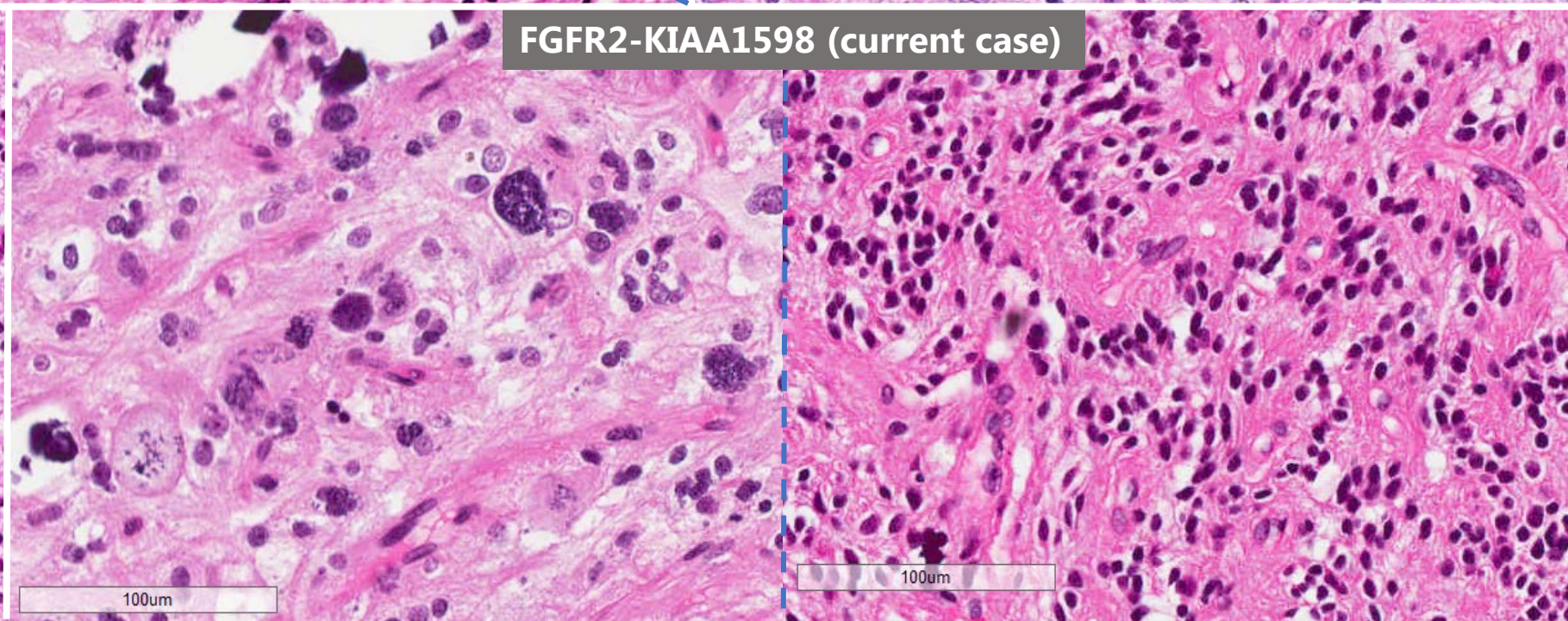
FGFR2-CTNNA3 "oligoastrocytoma"



FGFR2-ERC1 "oligodendroglioma"



FGFR2-KIAA1598 (current case)



Outcome

Table 1 Demographic, clinical, and molecular features of PLNTYs

Case #	Age at Dx (years)	Gender	Clinical presentation	Duration	Location	Treatment	Follow-up (months)	Outcome	BRAF mutation	Fusion transcripts
1	16	M	Seizures	>2 years	R med temporal	GTR	53	NED, no seizures	BRAF V600E	
2	18	F	Seizures	1 year	R med temporal	STR	18	Post-op psychosis, now SD	BRAF V600E	
3	23	F	Seizures	Unknown	R temporal	N/A	N/A	N/A	BRAF V600E	
4	17	F	Seizures	Unknown	R temporal	GTR	89	NED, no seizures	Neg	FGFR3-TACC3
5	4	M	Seizures	Unknown	L temporal	GTR	86	NED, no seizures	Neg	FGFR2-CTNNA3
6	9	M	Seizures	6 years	R frontal	GTR	36	New seizures and MRI abnormality after 36 months	Neg	FGFR2-KIAA1598 ^a
7	10	M	HA/dizziness	6 days	R occipital	GTR	62	NED	Neg	FGFR2-KIAA1598
8	23	F	Seizures	N/A	R medial temporal	GTR	12	NED	Neg	
9	32	F	Seizures	26 years	R temporal	GTR	55	NED, no seizures	N/A	
10	24	F	Visual disturbances	2 years	R occipital	GTR	12	NED	N/A	

Sick Kids cases:

1	9	F	Seizures	“long”	L parietal	GTR	1	Plan for radiation	Neg	FGFR2-KIAA1598
2	17	M	Seizures	12 y	L frontal	GTR	1	?	Neg	FGFR2-INA
3	8	F	Seizures	2 y	L parietal	GTR	24	NED	Neg	FGFR2-CTNNA3
4	16	M	Seizures	12 y	L occipital	GTR	24	NED	Neg	FGFR2-ERC1

Summary: PLNTY

Epilepsy-associated tumour of the young

Polymorphous with oligodendroglial-like component, CD34+

fibrillary, spindled, pleomorphic astrocytic

perivascular pseudorosettes

ganglioglioma

Our case: high-grade histology – prognosis?

MAPK pathway (BRAF V600E, FGFR2/3)

References

Polymorphous low-grade neuroepithelial tumor of the young (PLNTY): an epileptogenic neoplasm with oligodendroglioma-like components, aberrant CD34 expression, and genetic alterations involving the MAP kinase pathway.

Huse JT, Snuderl M, Jones DT, Brathwaite CD, Altman N, Lavi E, et al. [Acta Neuropathol 2017;133:417-29.](#)

Genetic alterations in uncommon low-grade neuroepithelial tumors: BRAF, FGFR1, and MYB mutations occur at high frequency and align with morphology.

Qaddoumi I, Orisme W, Wen J, Santiago T, Gupta K, Dalton JD, et al. [Acta Neuropathol 2016;131:833-45.](#)

Whole-genome sequencing identifies genetic alterations in pediatric low-grade gliomas.

Zhang J, Wu G, Miller CP, Tatevossian RG, Dalton JD, Tang B et al. [Nat Gen 2013;45:602-12.](#)

An integrative molecular and genomic analysis of pediatric hemispheric low-grade gliomas: an update.

Lassaletta A, Zapotocky M, Bouffet E, Hawkins C, Tabori U. [Childs Nerv Syst 2016;32:1789-97.](#)