

Case 2023-4

Gregory M. Chamberlin, MD

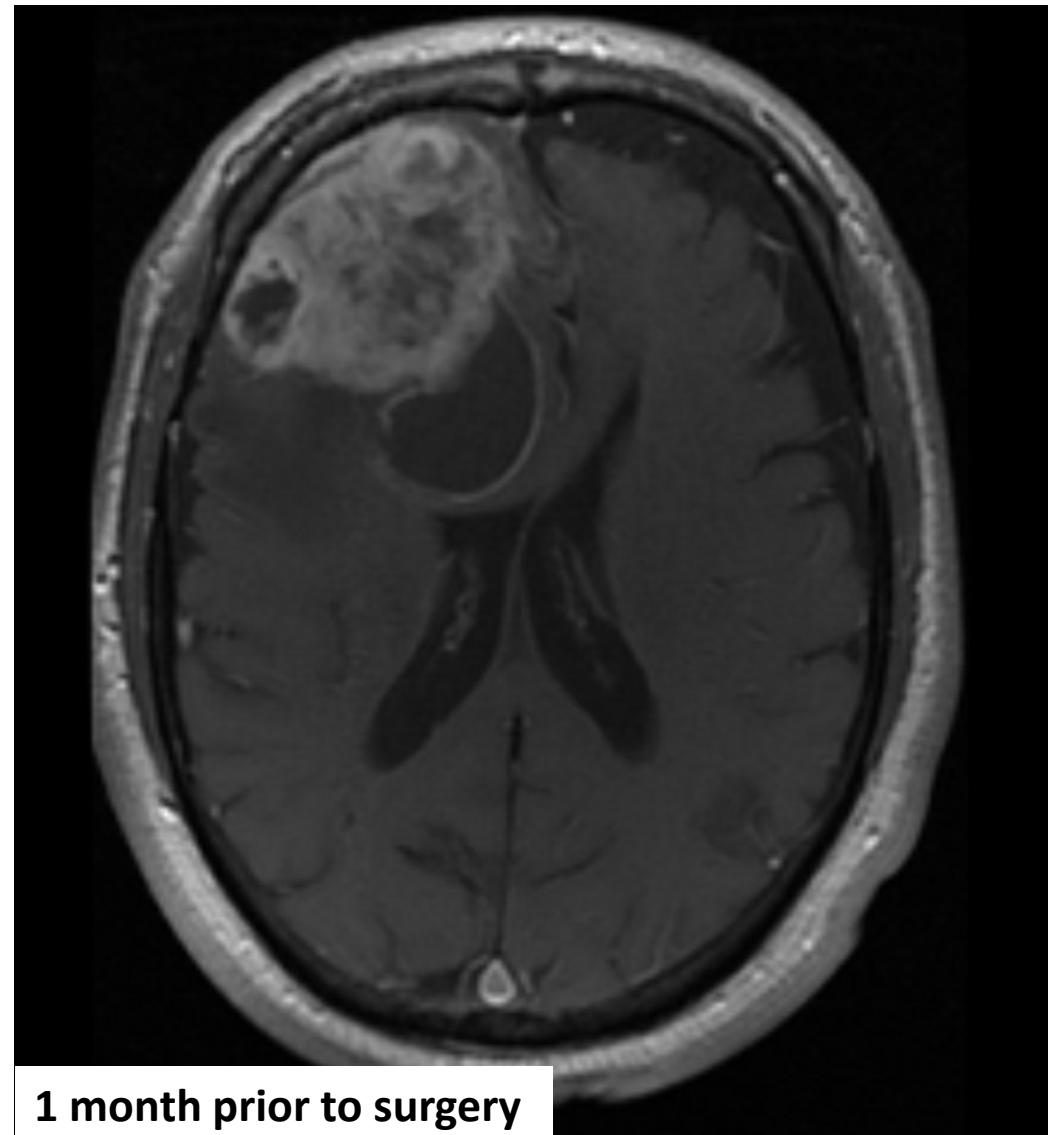
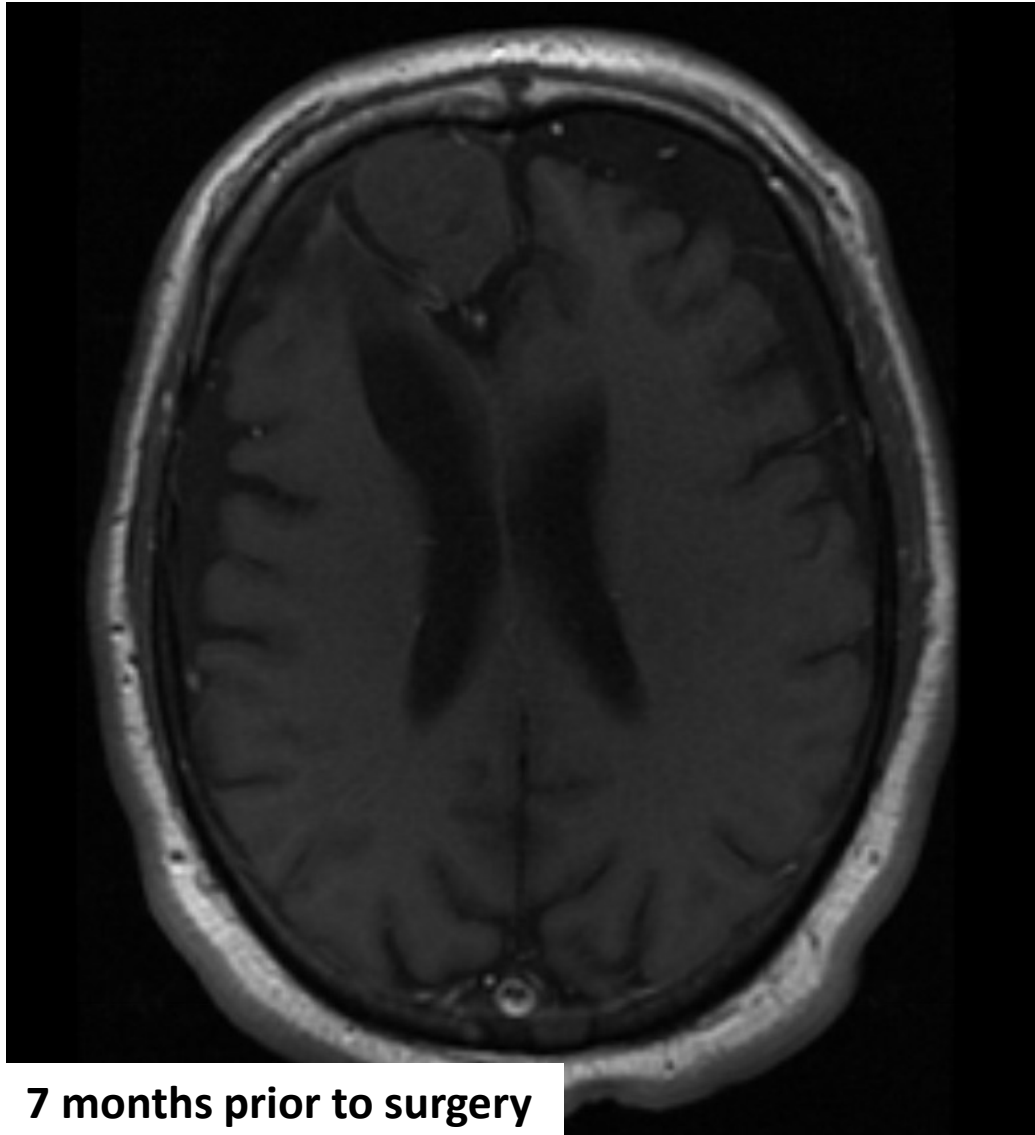
Thomas J. Cummings, MD

Duke University Medical Center

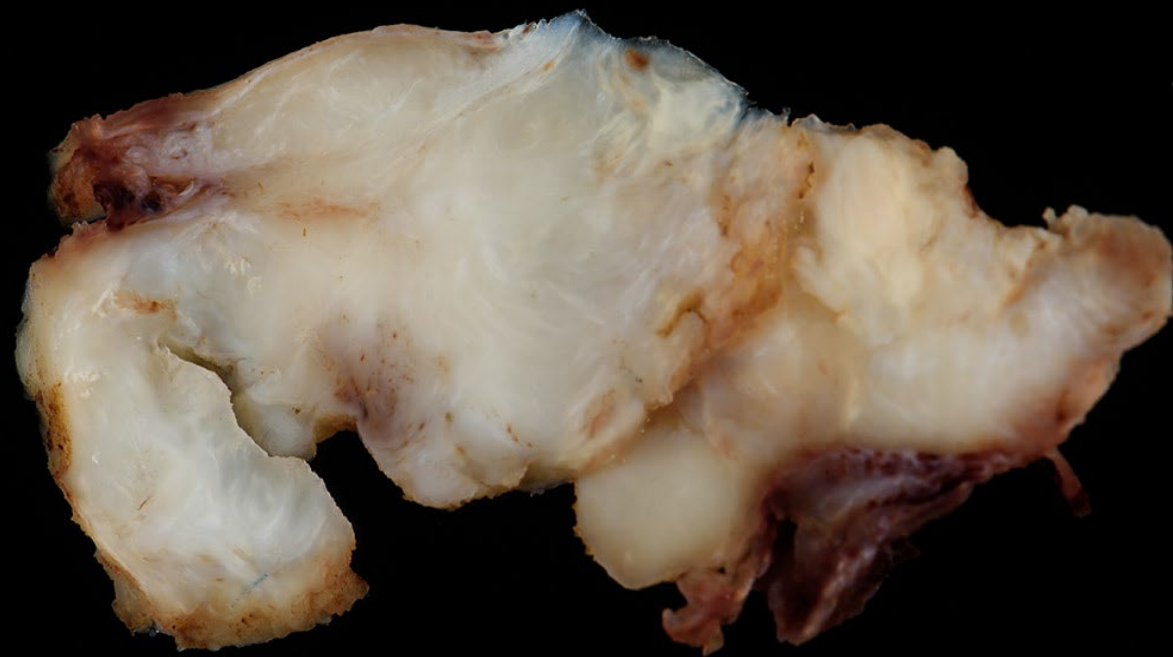
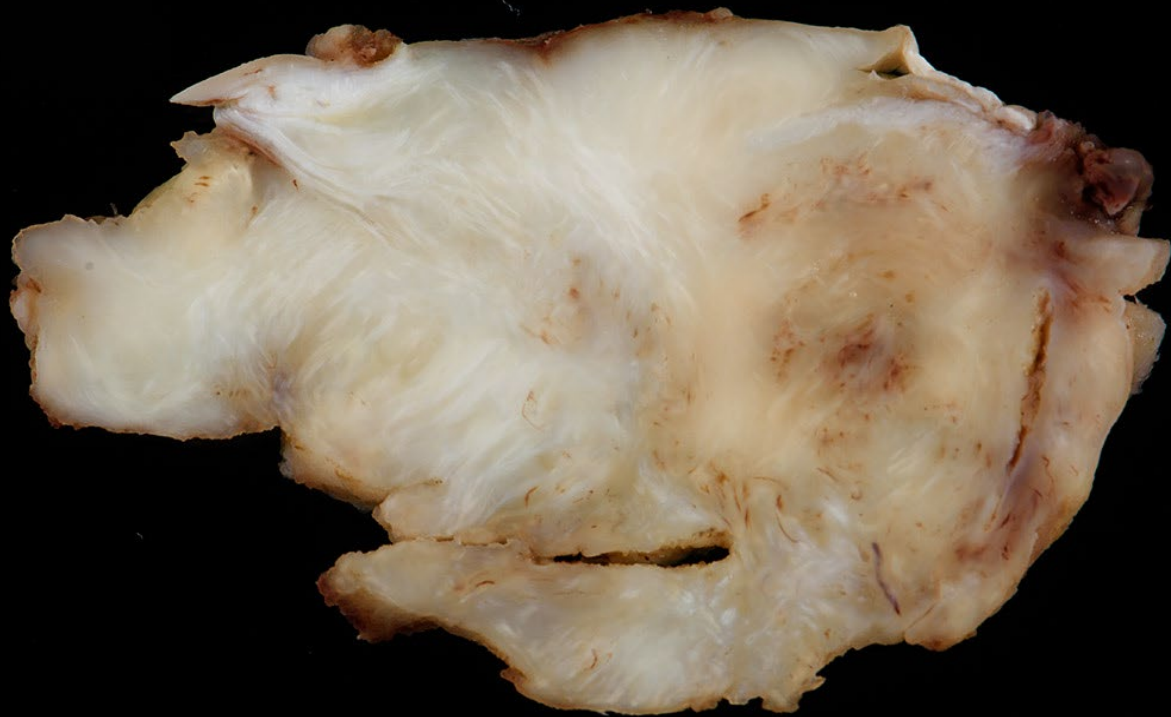Clinical History

- **59-year-old man with history of grade 2 oligodendroglioma of right frontal region, status post resection 17 years prior**
- **1p/19q-codeletion present in initial resection**
- **No adjuvant chemoradiation, followed with serial imaging**
- **New growth and contrast enhancement over 6-month interval**

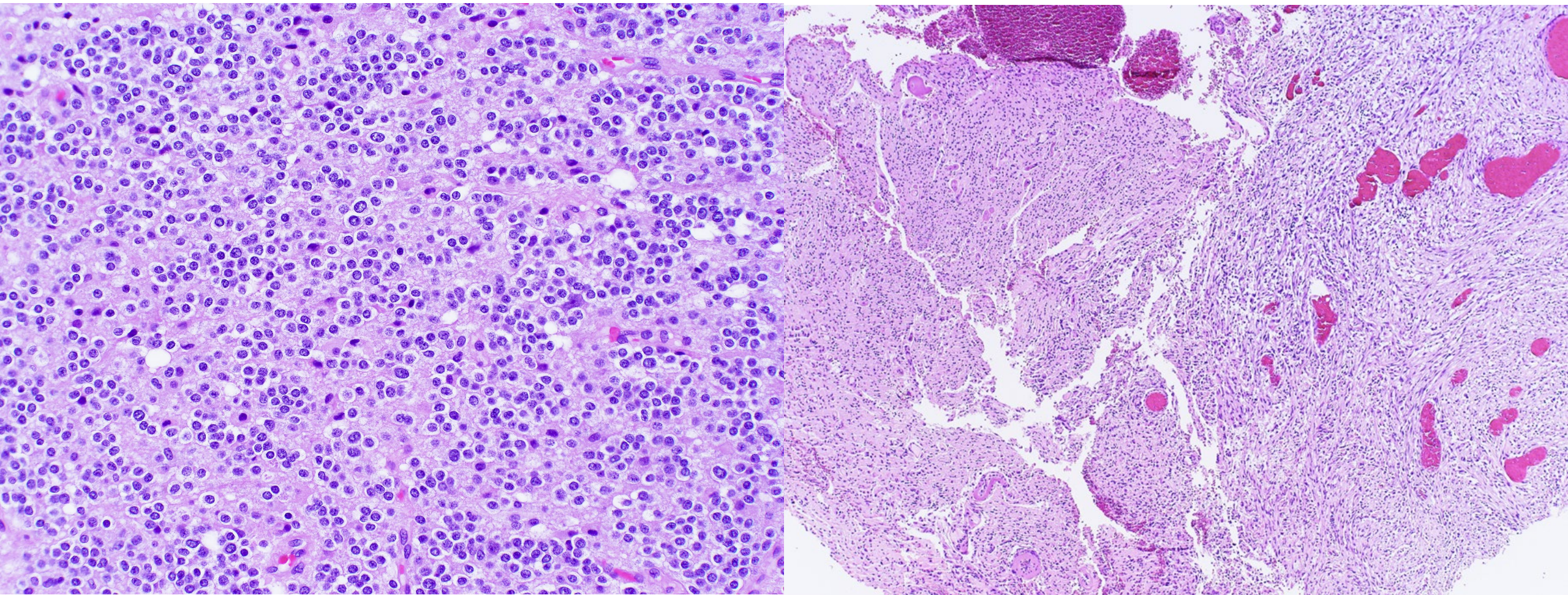
Pre-Operative MRI (T1 Post-Contrast)

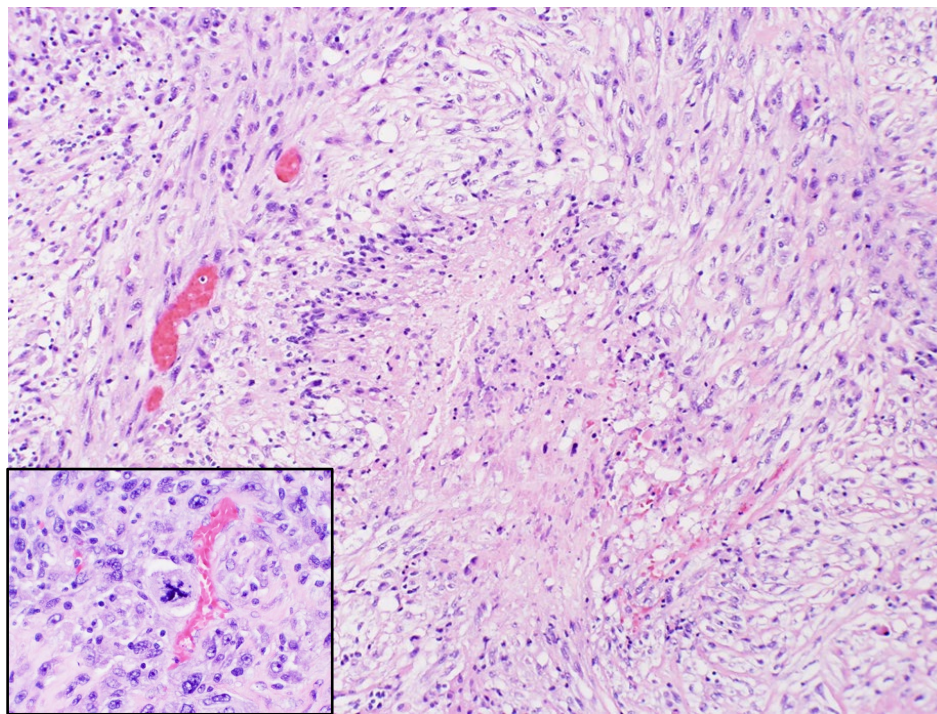
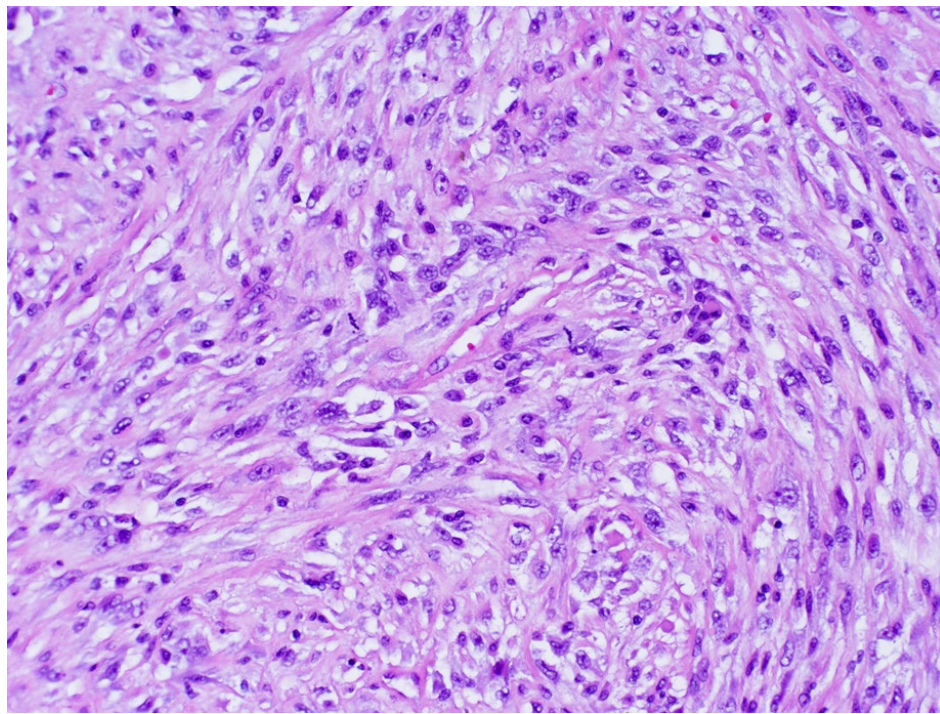
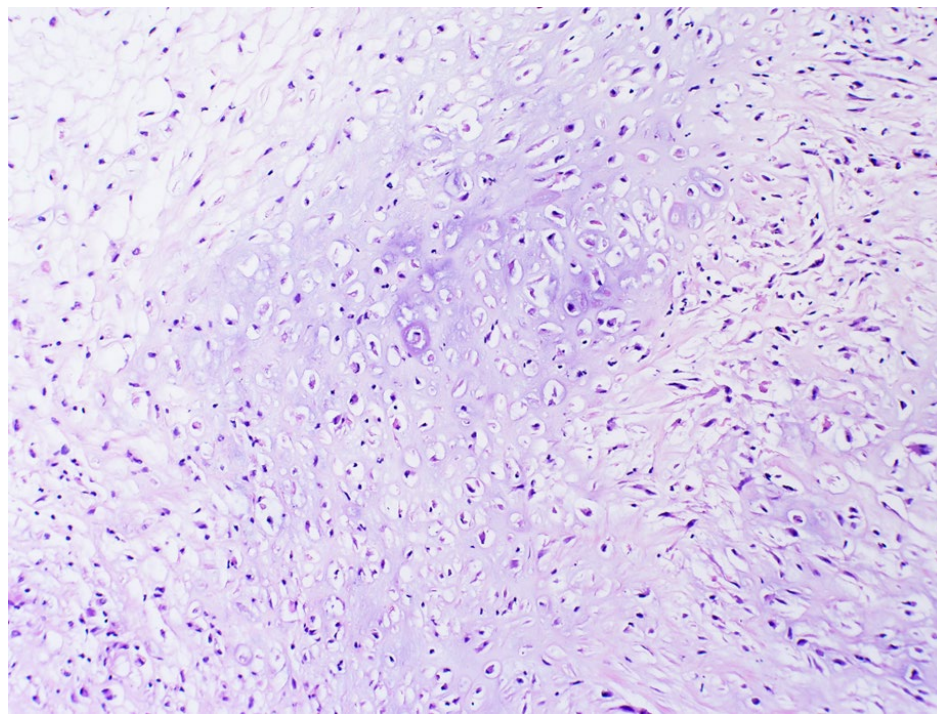
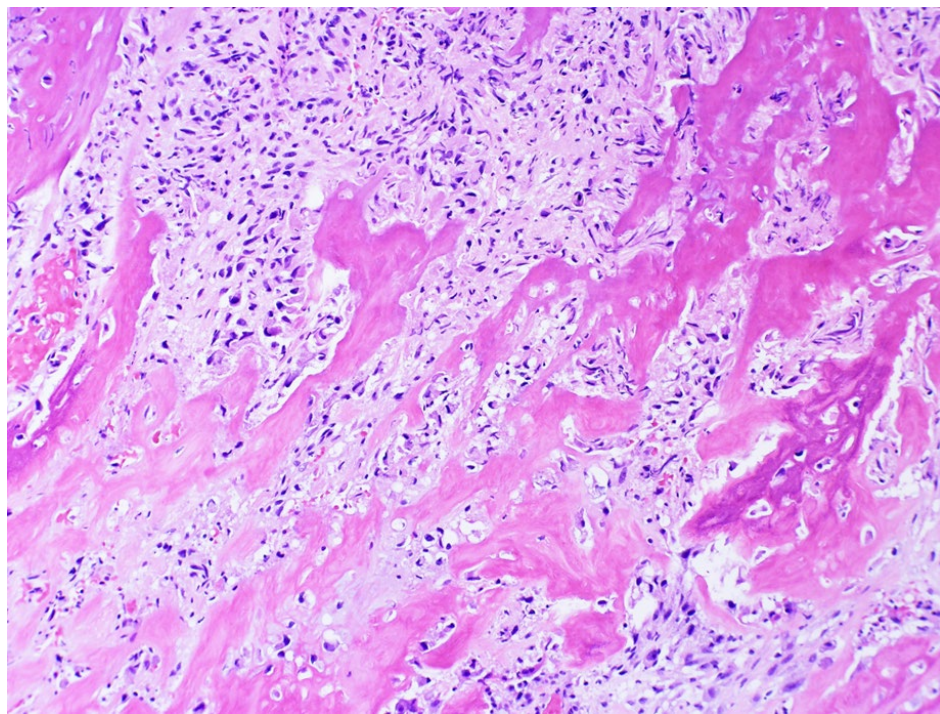


Gross Findings

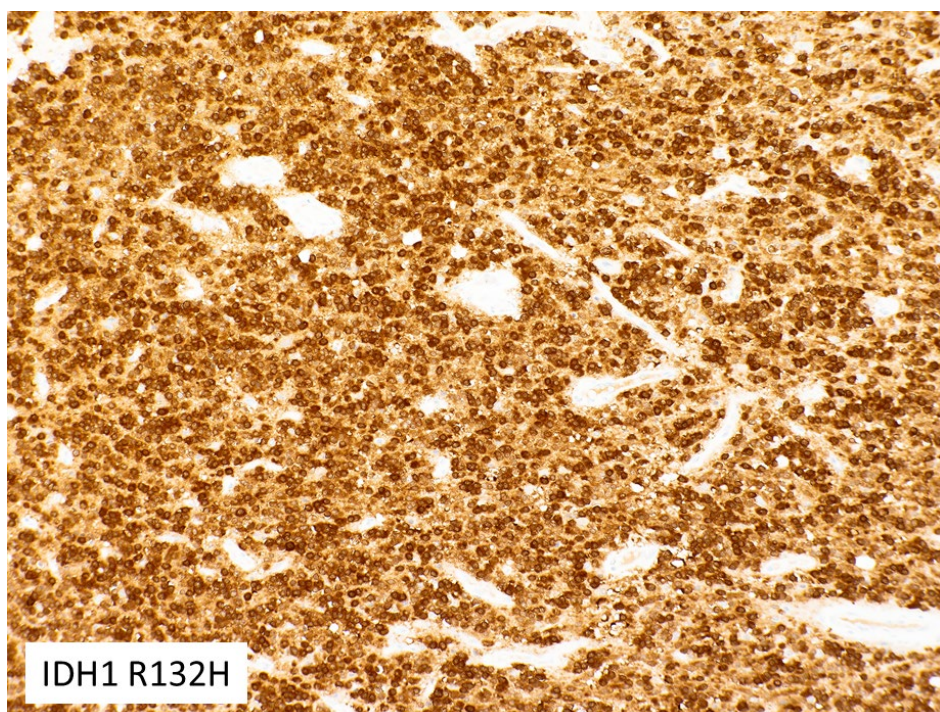


Microscopic Findings

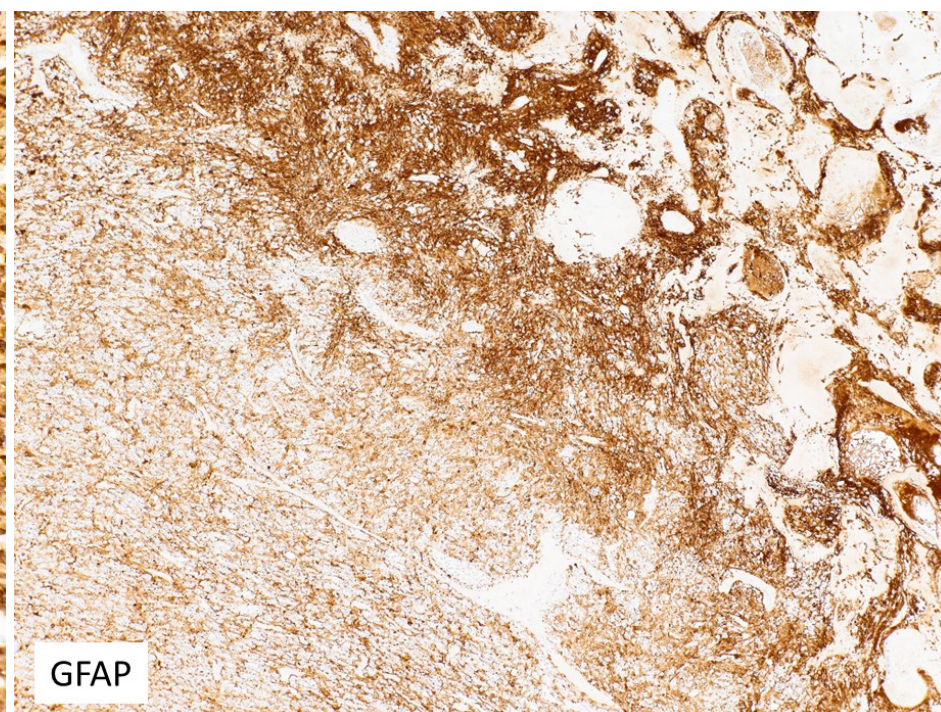




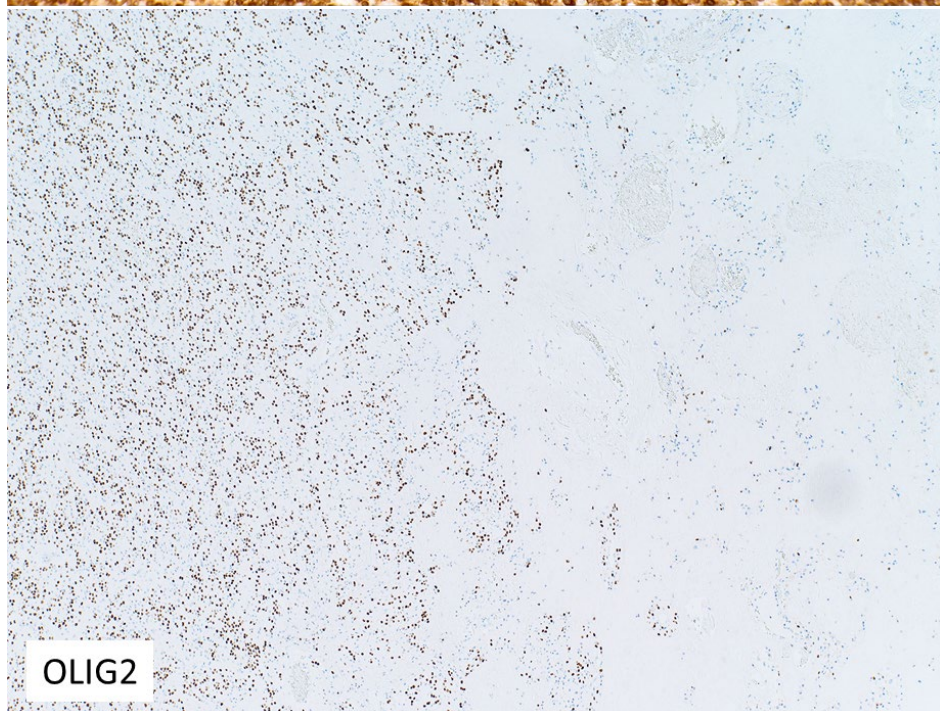
Diagnosis?



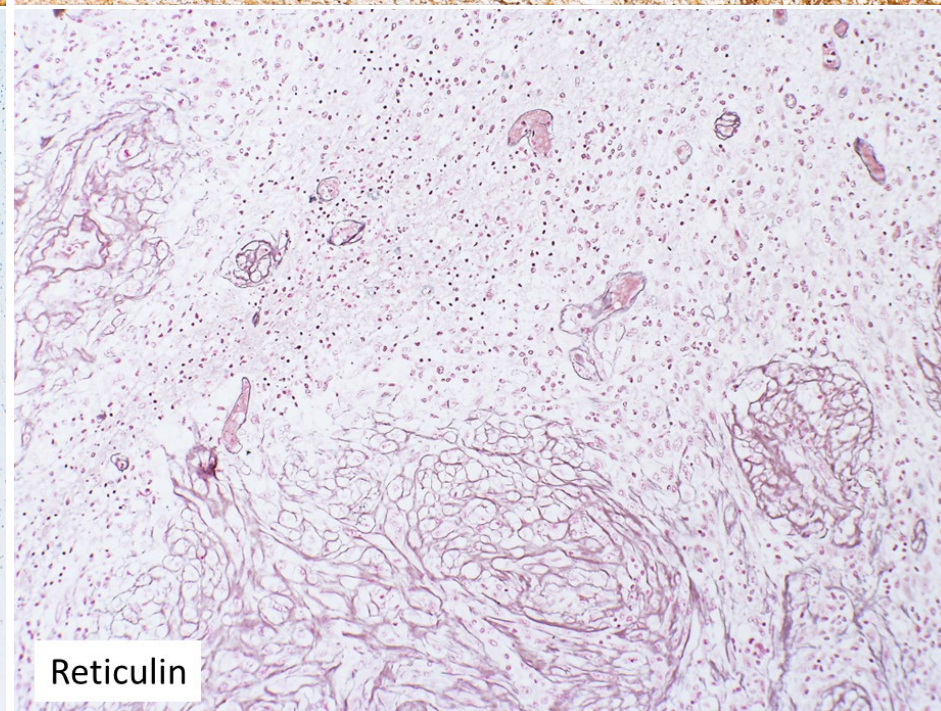
IDH1 R132H



GFAP



OLIG2



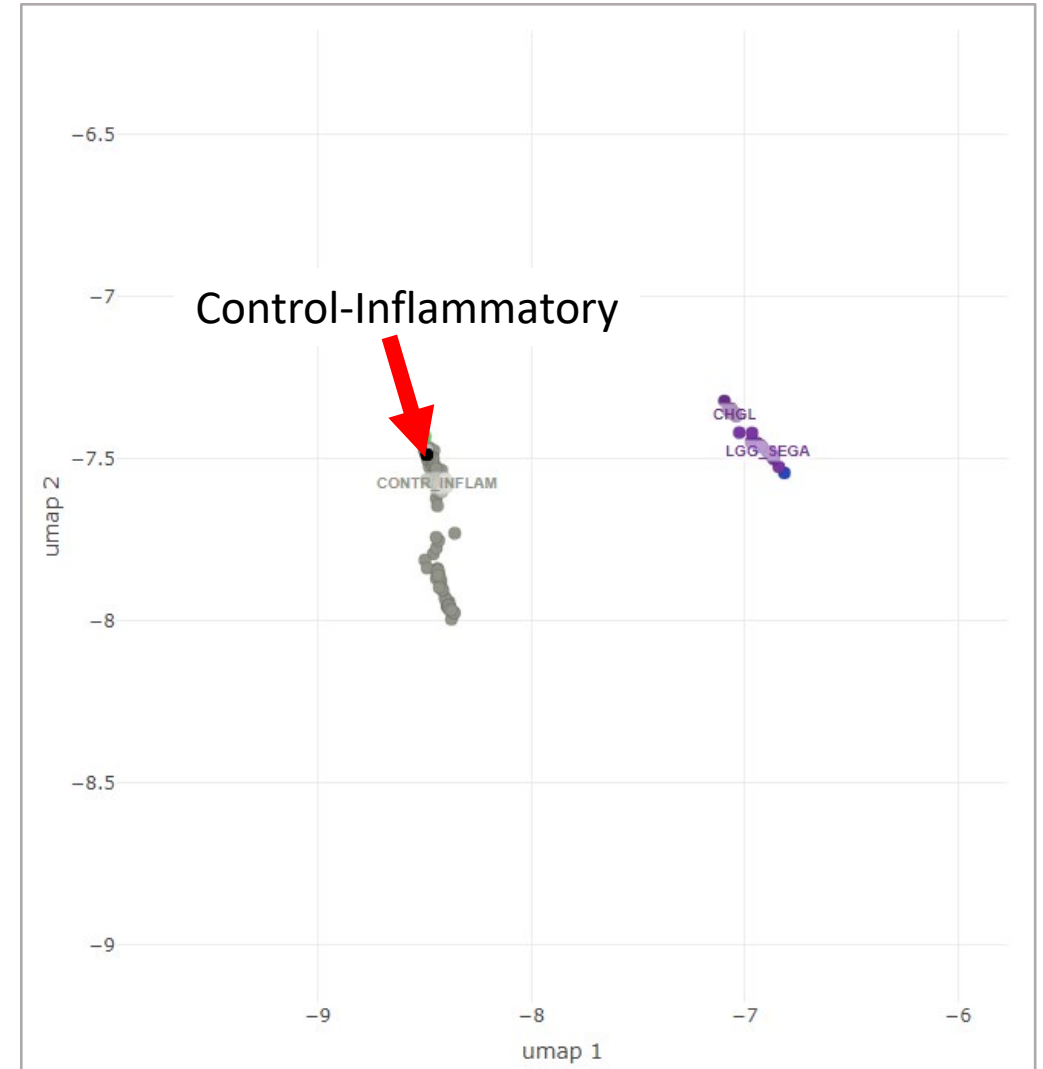
Reticulin

CMA and Molecular Results

- ***IDH1* c.395G>A (R132H)**
- ***TERT* c.-146C>T (C250T)**
- **1p/19q-codeletion**
- ***CDKN2A/B* homozygous deletion not identified**

Whole Genome Methylation Profiling

- No match
- DKFZ v12.6 suggestive of glioblastoma, IDH-wildtype, mesenchymal subtype, subclass B
- UMAP non-contributory
- ***TERT* c.-124C>T and *TERT* c.-146C>T**



CMA and Molecular Results (Continued)

Oligodendroglial Differentiation

- *IDH1* c.395G>A (R132H)
- *TERT* c.-146C>T (C250T)
- 1p/19q-codeletion
- No *CDKN2A/B* homozygous deletion

Sarcomatous Differentiation

- No *IDH1* or *IDH2* mutation
- *TERT* c.-124C>T (C228T)
- No 1p/19q-codeletion
- +7/-10 and *CDKN2A/B* homozygous deletion

Final Diagnosis

- **Malignant glial neoplasm, NEC, mixed/collision tumor consisting of recurrent Oligodendroglioma, IDH-mutant and 1p/19q-codeleted and novel Gliosarcoma, IDH-wildtype, CNS WHO grade 4**

Gliosarcoma Arising in Oligodendroglial Tumors ("Oligosarcoma") A Clinicopathologic Study

- **7 patients; 6 with sarcomatous differentiation at recurrence**
- **FISH confirmed 1p/19q-codeletion in 5, no deletion in 1, failed in 1**
 - **Limited to glial component in 2/5, present in both components in 3/5**
- **Glial component oligodendroglioma (n=4) or oligoastrocytoma (n=3)**
- **Subset may represent gliosarcoma, IDH-mutant astrocytoma with sarcomatous differentiation, or collision tumors**

Oligosarcomas, IDH-Mutant Are Distinct and Aggressive

- **24 IDH-mutant oligosarcomas from 23 patients**
- **1p/19q-codeletion not seen in 5 cases**
 - **Demonstrated either CN-LOH or relative deletion in a tetraploid background**
- **Recurrent cytogenetic abnormalities**
 - **6q loss, monosomy 3 and/or 18, CDKN2A/B homozygous deletion**
- **t-SNE analysis demonstrated distinct methylation class from other gliomas**

Discussion

- **Additional diagnostic consideration – collision tumor between oligodendroglioma and primary sarcoma**
 - **De-differentiated chondrosarcoma (PMID 11793445)**
 - **Recurrent findings: -1p36, -1p13-p22, -4, -5q13-q31, -6q22-qter, +7p13-pter, -9p22-pter, -10p, -10q24-qter, -11p13-pter, -11q25, +12q15-qter, -13q21-qter, -14q24-qter, -18p, -18q22-qter, +19, +20pter-q11, +21q, and -22q13**
 - **Osteosarcoma (PMID 11950895)**
 - **Recurrent copy number variations: 1p11-13, 1q11-12, 1q21-22, 11p14-15, 14p11-13, 15p11-13, 17p, and 19q13, chromosome 1 gain, loss of chromosomes 9, 10, 13, 17**

References

- Ebrahimi A, et al. "Methylation class oligosarcoma may encompass IDH-wildtype gliomas." *Acta Neuropathol.* 2023;145:361-364. PMID 36520193.
- Han SJ, et al. "Primary gliosarcoma: key clinical and pathologic distinctions from glioblastoma with implications as a unique oncologic entity." *J Neurooncol.* 2010;96:313-320. PMID 19618114.
- Mandahl N, et al. "Cytogenetic aberrations and their prognostic impact in chondrosarcoma." *Genes Chromosomes Cancer.* 2002;33:188-200. PMID 11793445.
- Ragland BD, et al. "Cytogenetics and molecular biology of osteosarcoma." *Lab Invest.* 2002;82:365-373. PMID 11950895.
- Rodriguez FJ, et al. "Gliosarcoma arising in oligodendroglial tumors ('oligosarcoma'): a clinicopathologic study." *Am J Surg Pathol.* 2007;31:351-362. PMID 17325476.
- Suwala AK, et al. "Oligosarcomas, IDH-mutant are distinct and aggressive." *Acta Neuropathol.* 2022;143:263-281. PMID 34967922.
- Tanaka S, et al. "Gliosarcoma arising from oligodendroglioma (oligosarcoma): a case report with genetic analyses." *Pathol Int.* 2018;68:567-573, PMID 30246385.
- Vajtai I, et al. "Sarcomatous evolution of oligodendroglioma ("oligosarcoma"): confirmatory report of an uncommon pattern of malignant progression in oligodendroglial tumors." *Pathol Res Pract.* 2012;208:750-755. PMID 23102810.