

A wide-angle photograph of the University of Virginia Rotunda building at sunset. The building is a large, circular neoclassical structure with a prominent portico supported by white columns. The sky is filled with soft, colorful clouds in shades of pink, orange, and purple. The foreground is a large, well-maintained green lawn. Other buildings with classical architectural features are visible on either side of the Rotunda.

DSS Case 12

Lena Young, DO

University of Virginia Department of Pathology

Division of Neuropathology

Case Summary

- 79-year-old-male with history of prostate cancer, squamous cell carcinoma, admitted for sepsis, acute kidney injury, rhabdomyolysis, confusion, leukocytosis and rash in the setting of a recent bite/sting by unknown insect.
- Lumbar puncture showed no elevated white blood cell count, normal glucose and protein.
- Died on day 4 following admission, was never stable enough for MRI.
- Postmortem testing of blood, CSF were negative for tickborne illnesses.

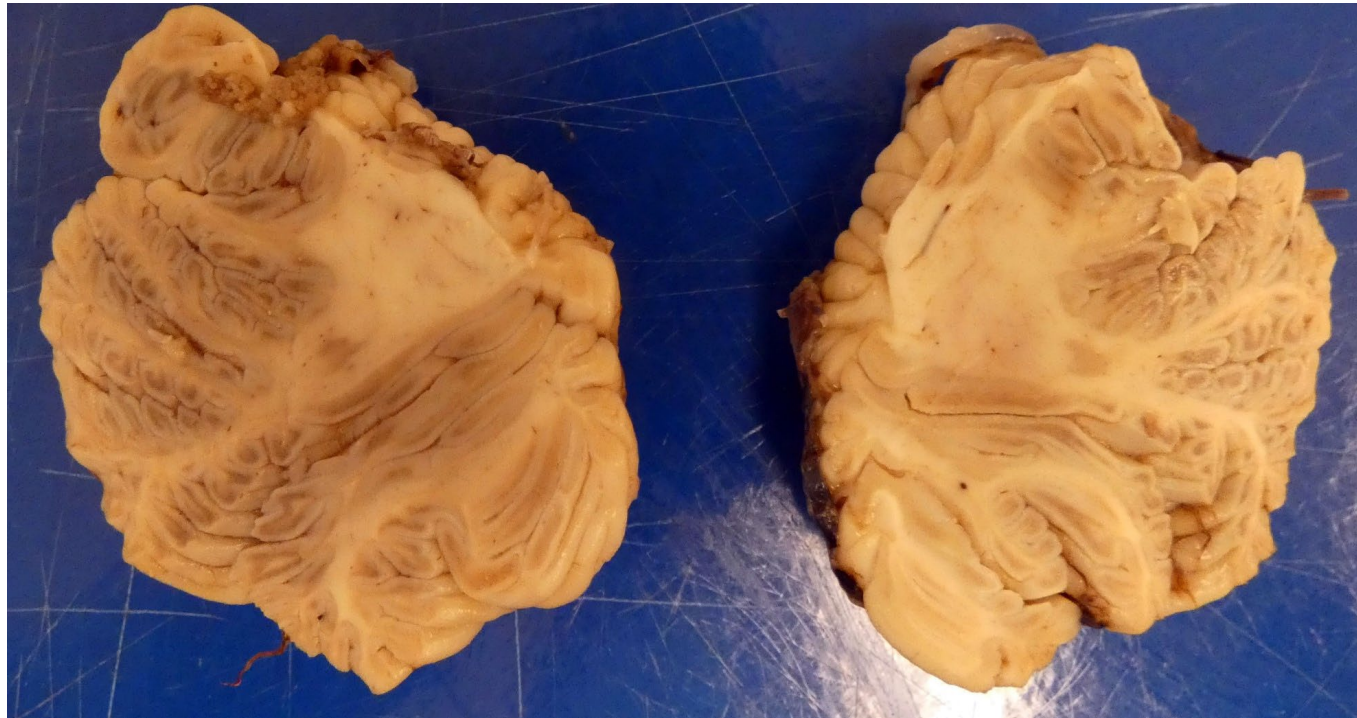
Autopsy Findings

- The cause of death was found to be shock and coagulopathy most likely due to septicemia.

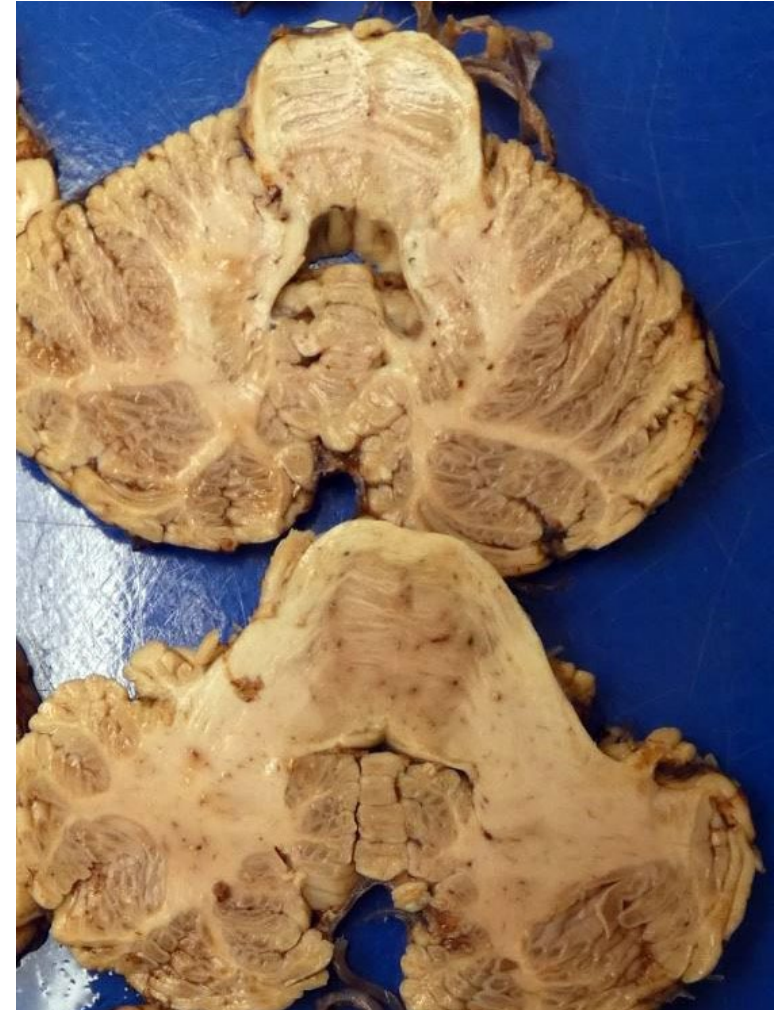Neuropathologic findings:

- The brain weighed 1430 grams.
- Patchy moderate to severe atherosclerosis.
- No evidence of meningitis or encephalitis.
- Neuropathologic changes consistent with Alzheimer disease, low probability (A1, B1, C1).
- Cerebral amyloid angiopathy.

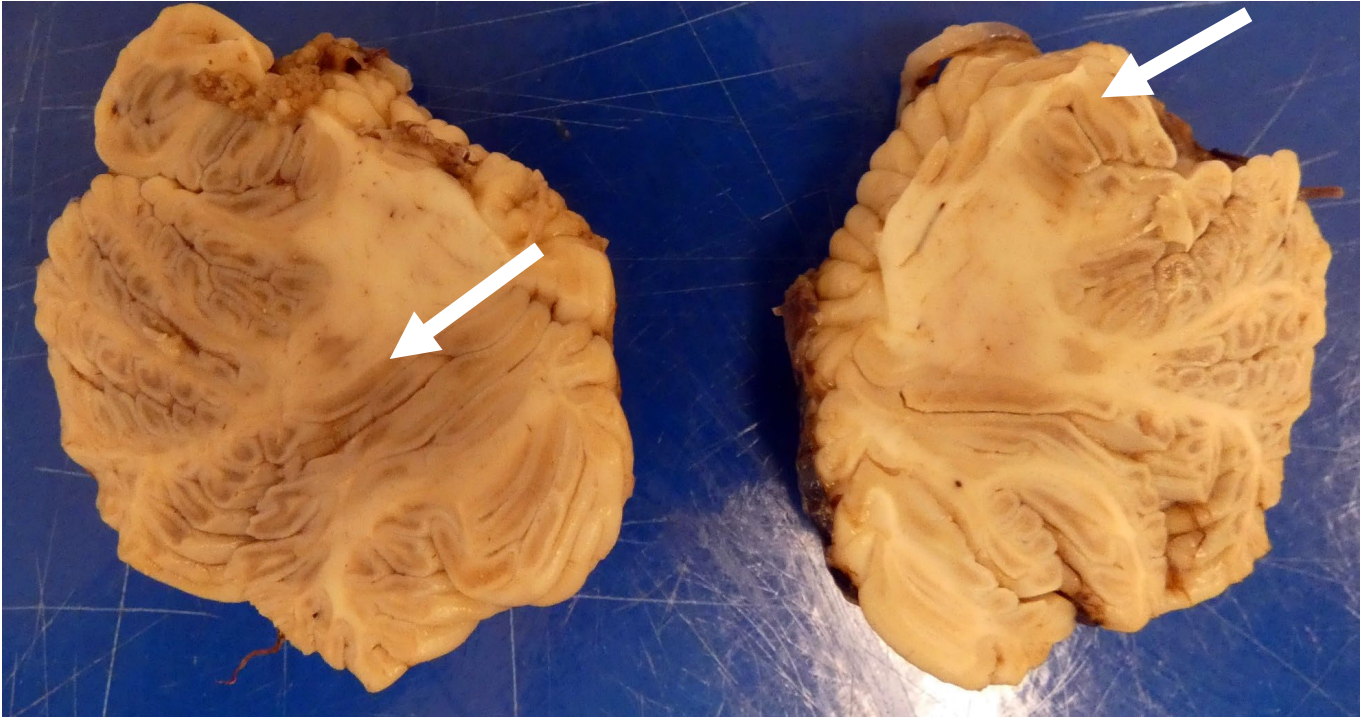
Cerebellar hemispheres



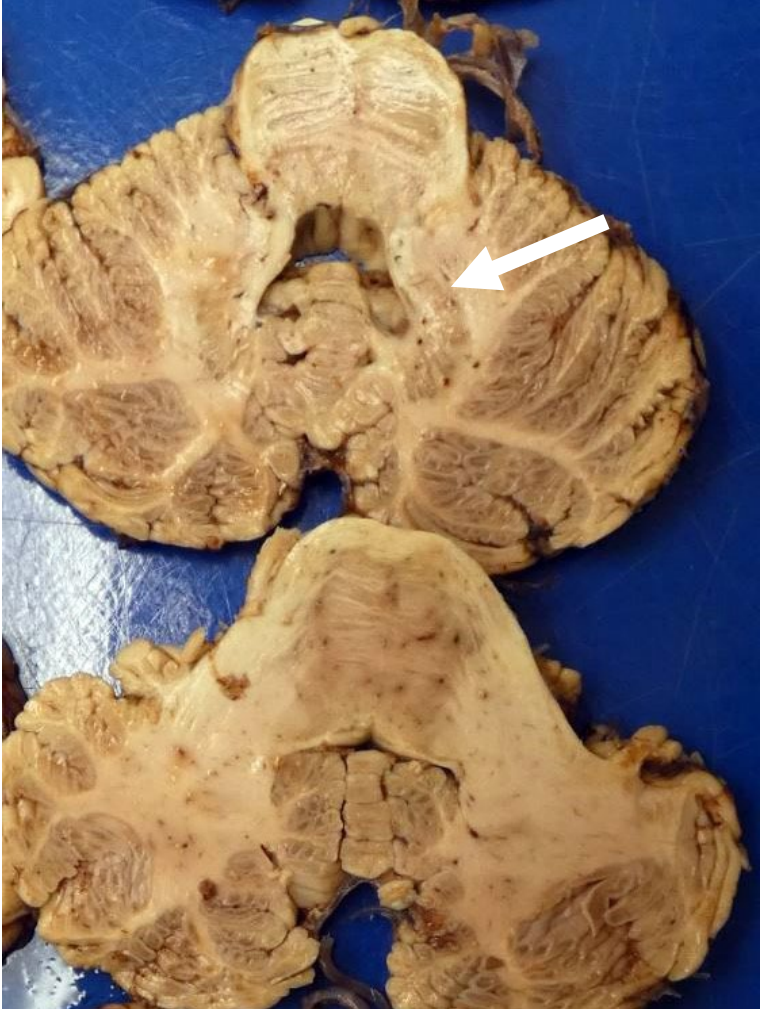
Brainstem and cerebellum

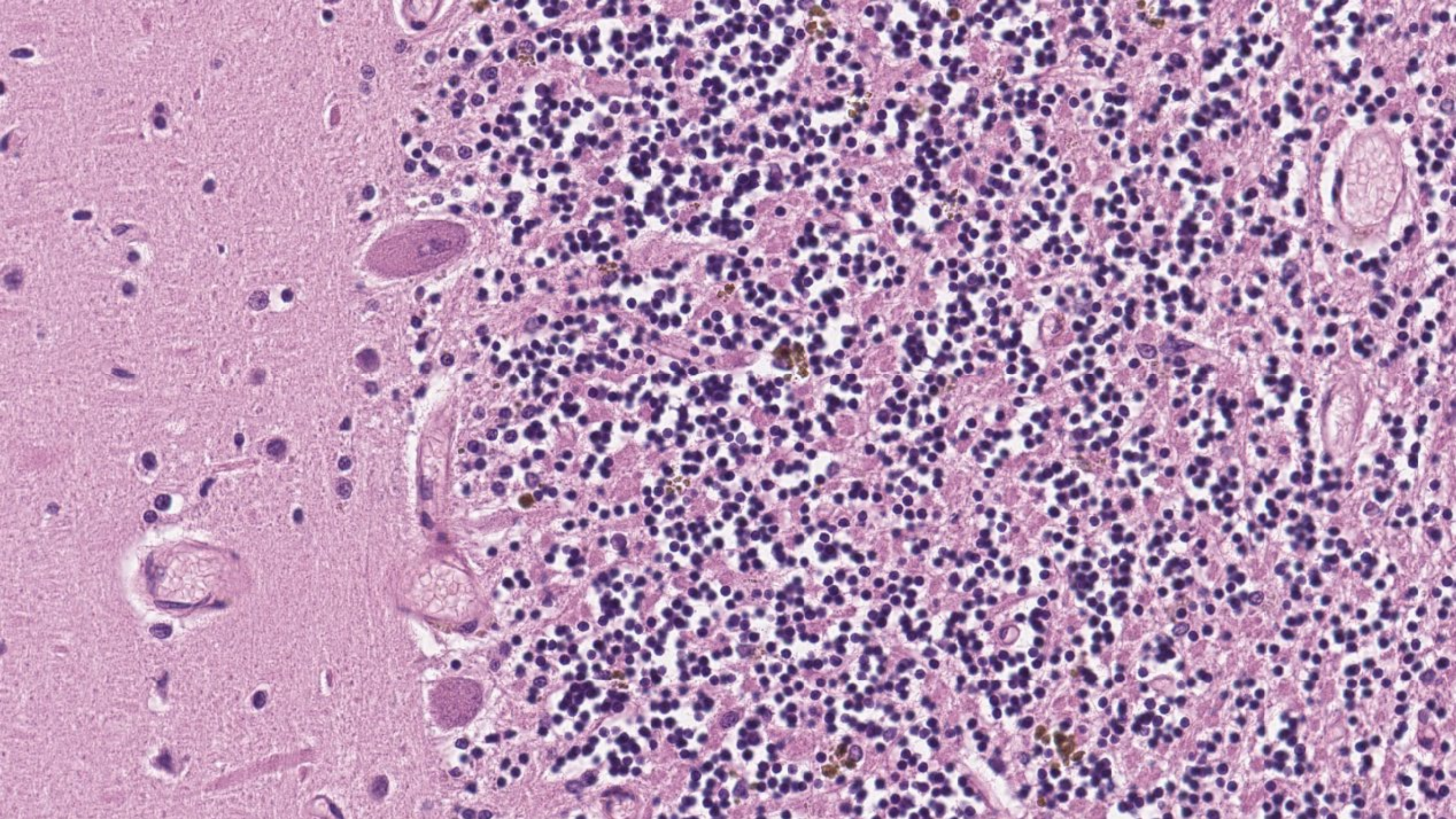


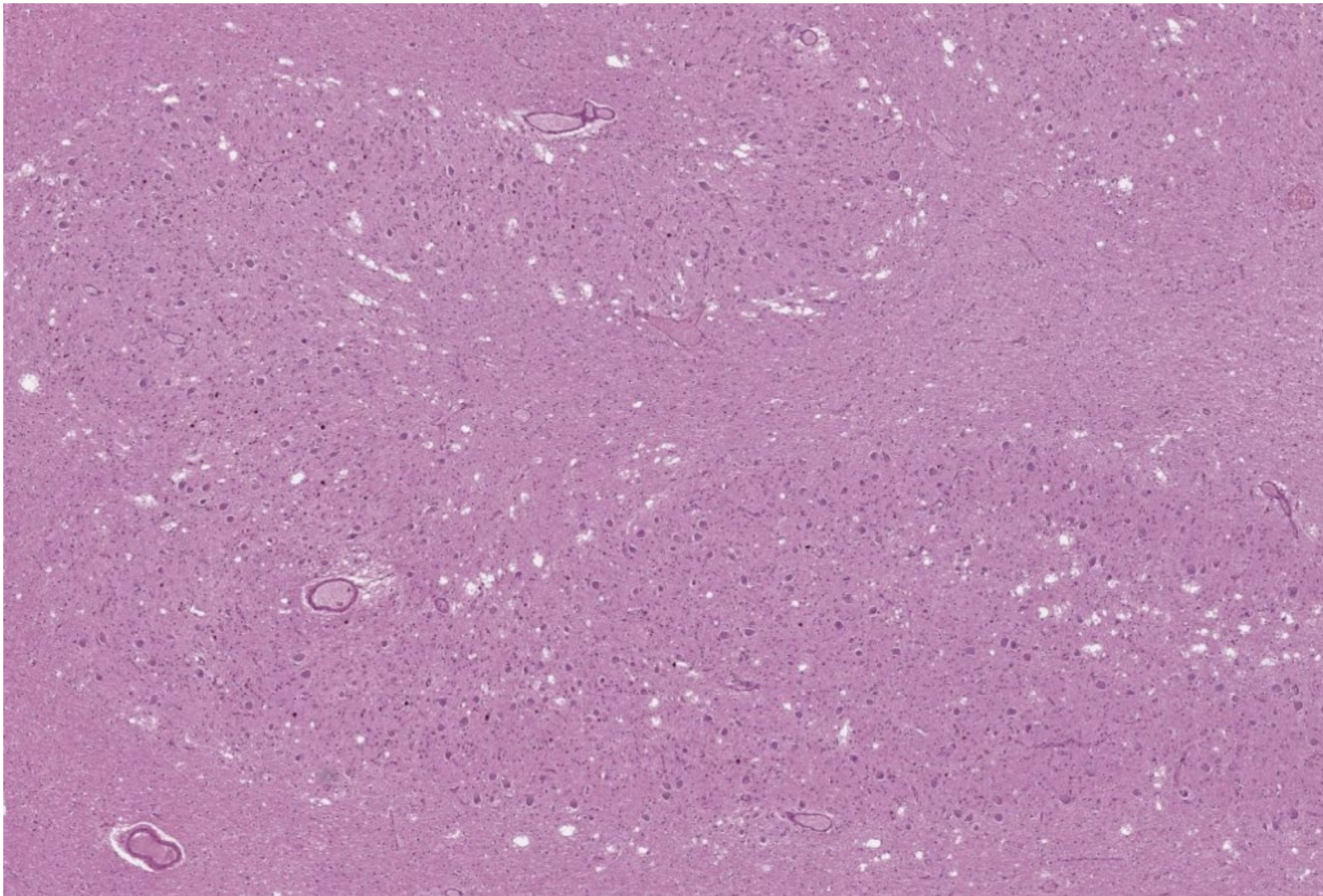
Cerebellar hemispheres

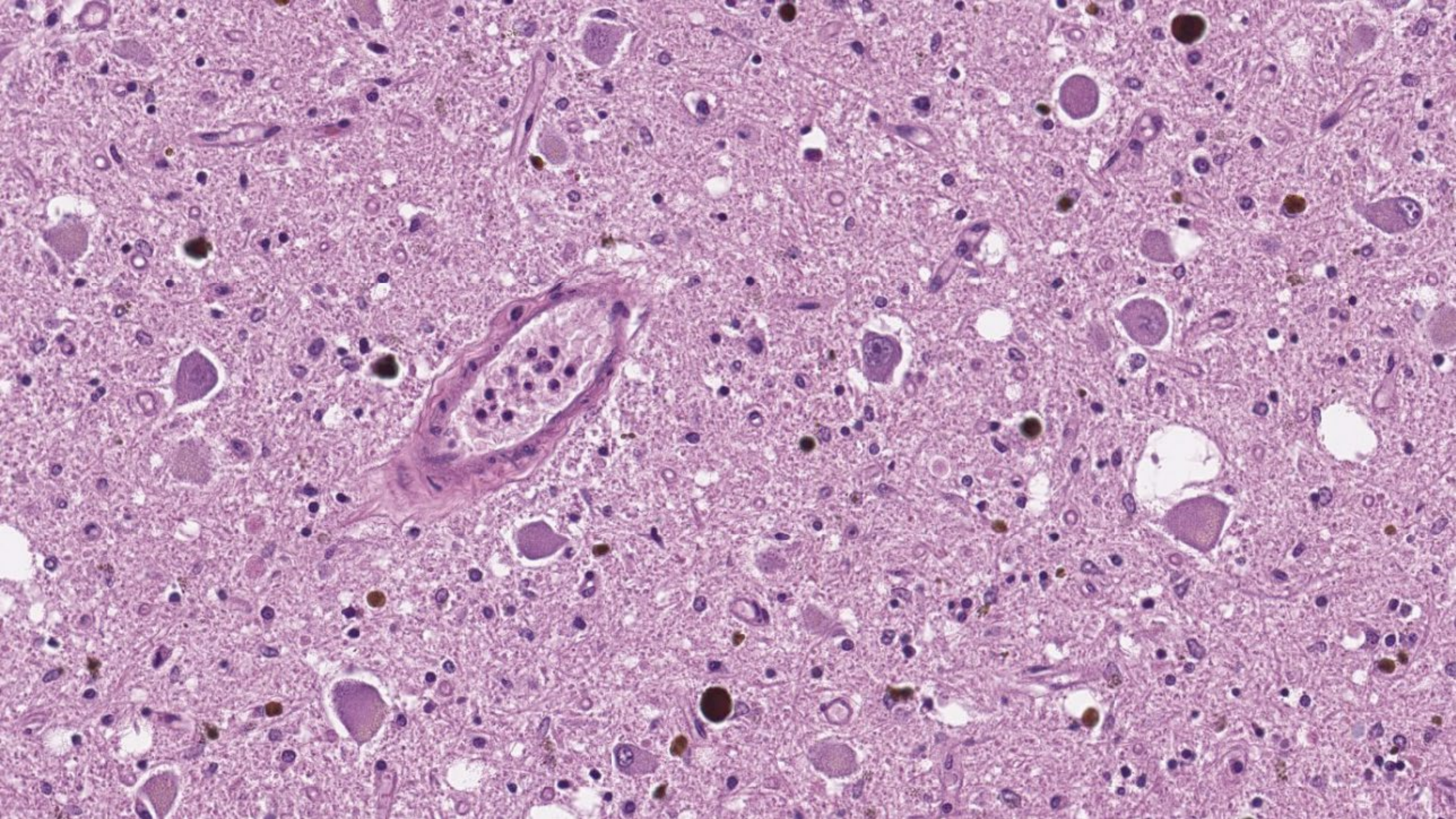


Brainstem and cerebellum

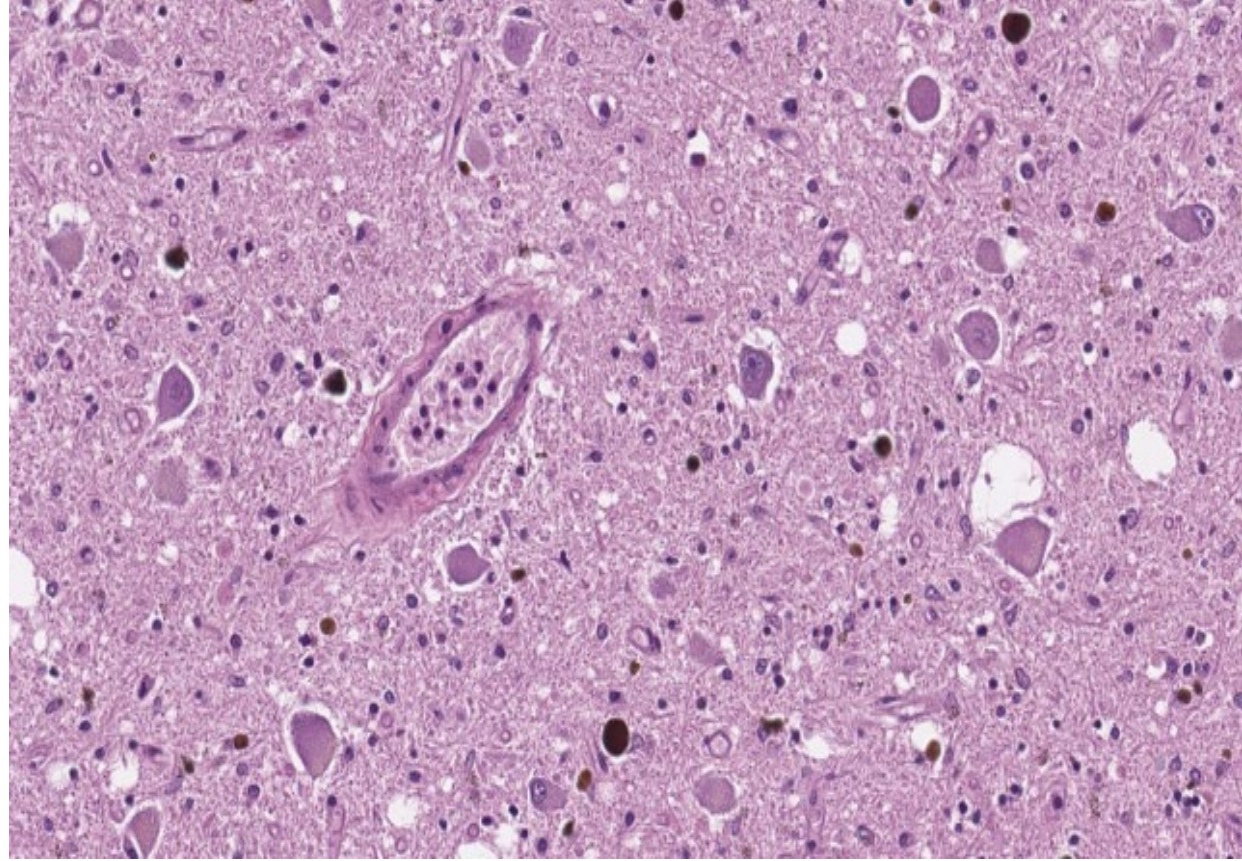
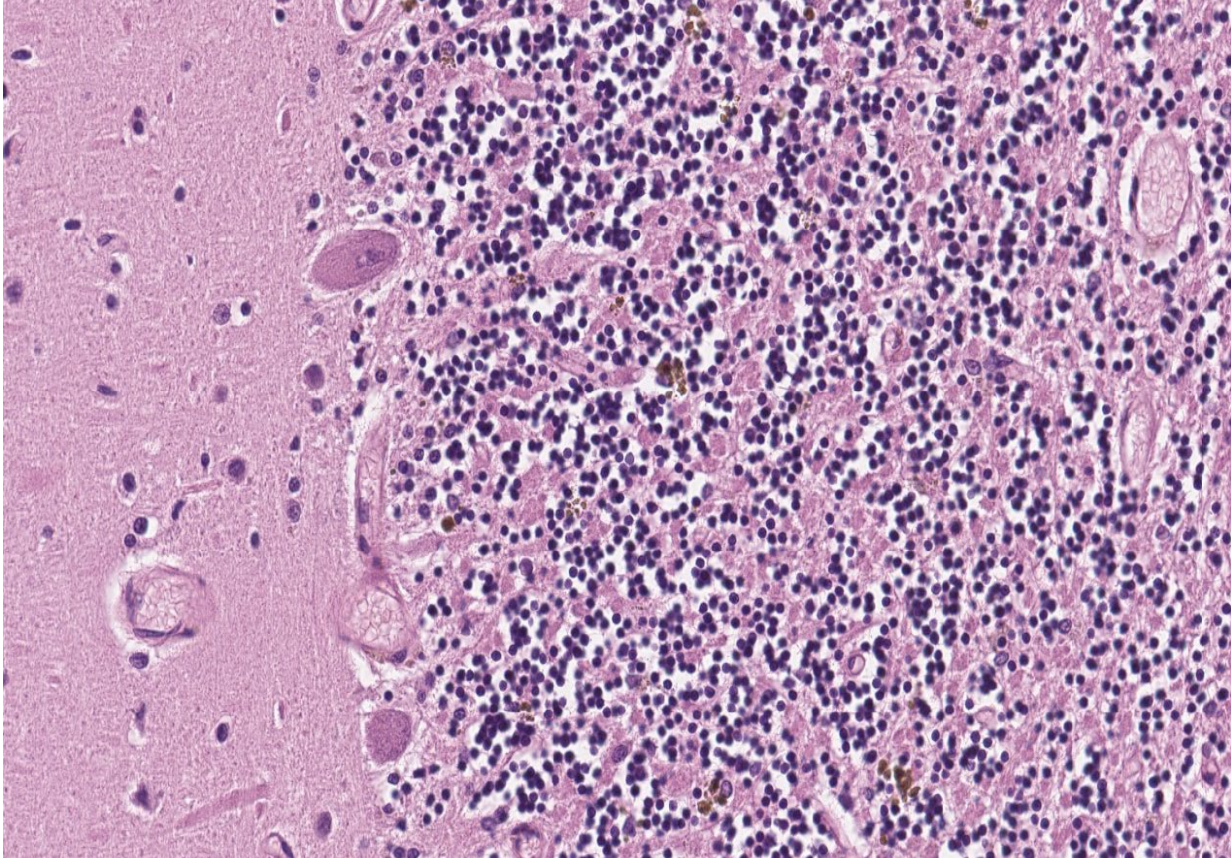




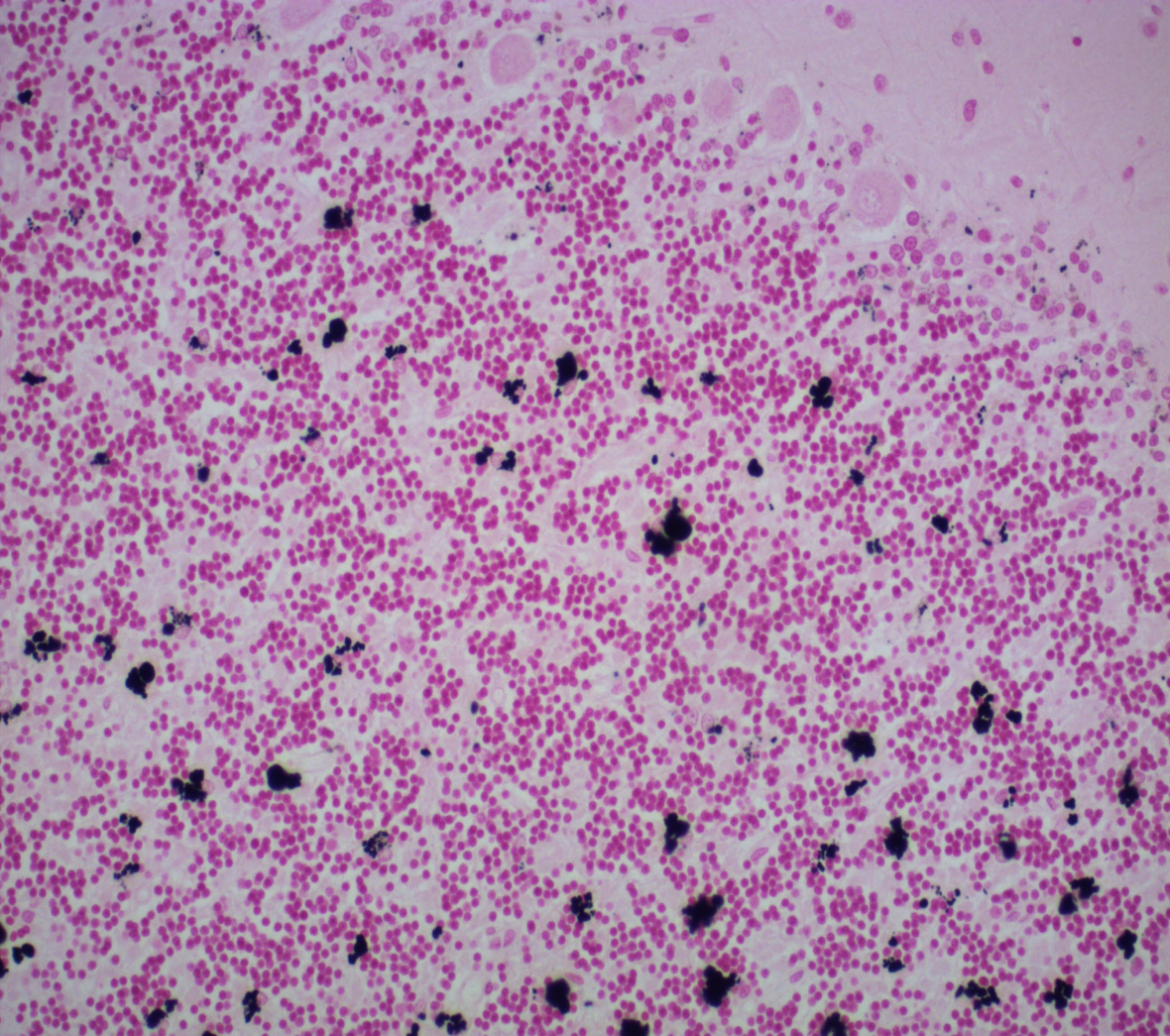




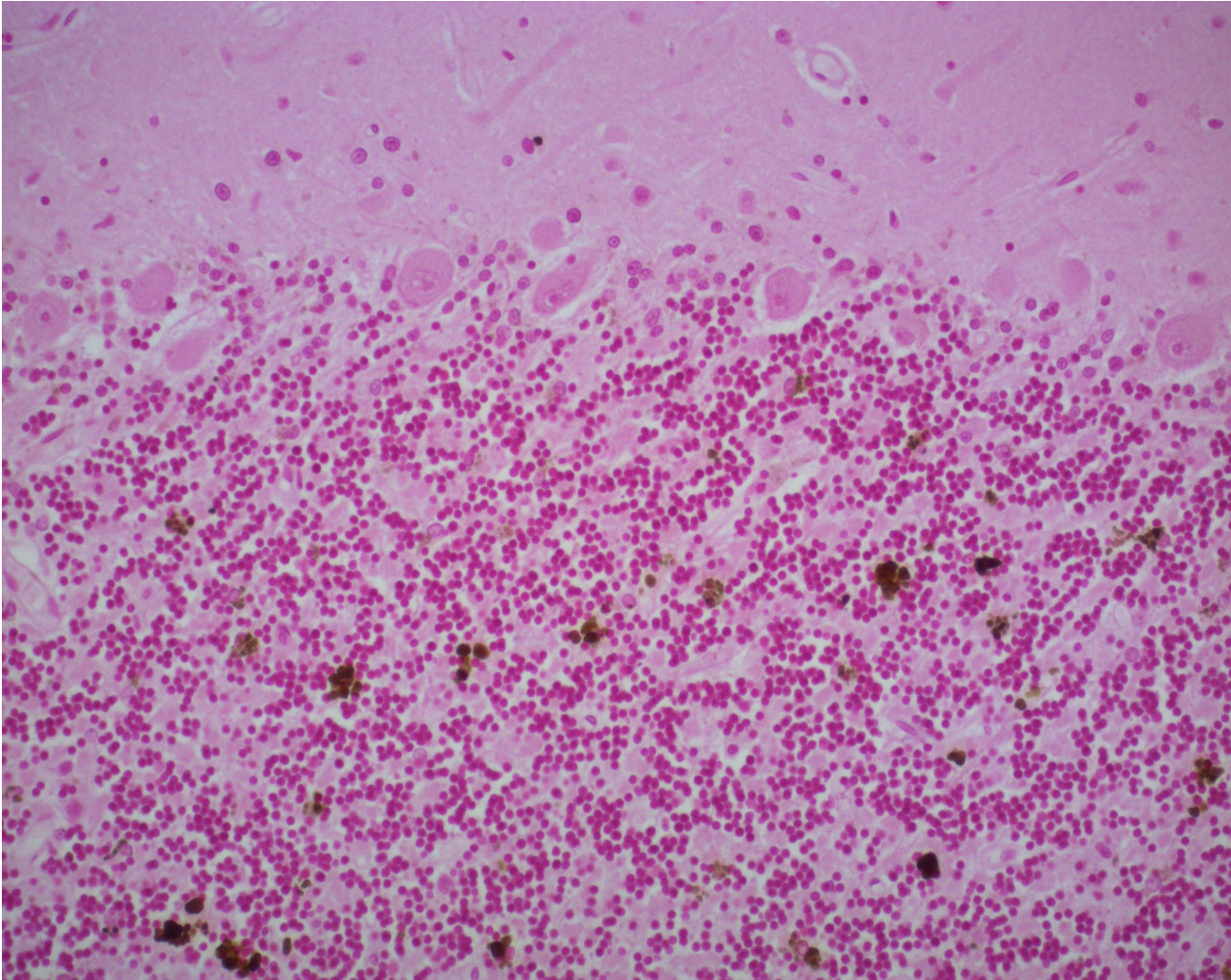
Diagnosis?



Fontana Masson



Iron



Primary Melanosis of the Cerebellum and Dentate Nucleus

Histopathology

- Primary melanosis of the cerebellum and dentate is characterized by accumulation of melanin pigment in the granular cell layer of the cerebellar cortex and the dentate nucleus.
- Specifically, the melanin is found within the neuropil and adjacent to/within reactive astrocytes.



Pigment characterization

- The only other case of primary melanosis of the cerebellum and dentate presented at DSS was in 1999 by Dr. Rojiani and colleagues.
 - They determined the pigment was Fontana positive, bleached with potassium permanganate.
- X-ray analysis of the neuromelanin determined they are predominantly sulfur (96.9%).
- Spectroscopy of neuromelanin shows the spectrum is closer to pheomelanins than eumelanins and the neuromelanin particles in primary melanosis is more likely related to neuromelanin than peripheral pigments.



Clinical features and pathogenesis

- Primary dentate melanosis is not yet known to be associated with any specific pathologic entity or drug.
- The age range spans from 26-104.
- The actual etiology of the localized pigment remains unclear.

References

- Bianchi C, Grandi G, Berti N, Di Bonito L. Melanosis cerebelli. *Acta Neuropathol Suppl.* 1981;7:400-2. doi: 10.1007/978-3-642-81553-9_114. PMID: 6939280.
- Fan KJ, Kovi J, Duhaney SD. Melanosis of the dentate nucleus: fine structure and histochemistry. *Acta Neuropathol.* 1978 Mar 15;41(3):249-51. doi: 10.1007/BF00690444. PMID: 645363.
- Hopley RT, Haller E, Rojiani MV, Rojiani AM. Morphologic and Elemental Analysis of Primary Melanosis of the Dentate Nucleus: Review and Correlation With Neuromelanin. *J Neuropathol Exp Neurol.* 2017 Nov 1;76(11):949-956. doi: 10.1093/jnen/nlx084. PMID: 29044415.
- Rojiani A, Francey J, Haller E, Case 1999-1, 40th Annual Diagnostic Slide Session 1999.
<https://neuro2.pathology.pitt.edu/dsa/api/v1/file/61819c088b53cc0c7af9038a/download?contentDisposition=inline&token=wHMahCLeSewFawabuSakyNeVNxB5ErGd7pP1uXZc6nifiGnpRSBjRCfpEBJFeDx>



THANK YOU