

54th ANNUAL DIAGNOSTIC SLIDE SESSION 2013

CASE 2013 -10

Submitted by: CPT (Dr.) Alan A. George, PGY-1 Pathology Resident and LT. COL. (Dr.) Derek Mathis, US Army Medical Corps, San Antonio Uniformed Services Health Education Consortium, 3551 Roger Brooke Dr.Ft. Sam Houston, TX 78234-6200; Dr. Greg Fuller, M.D. Anderson Cancer Center

Clinical History:

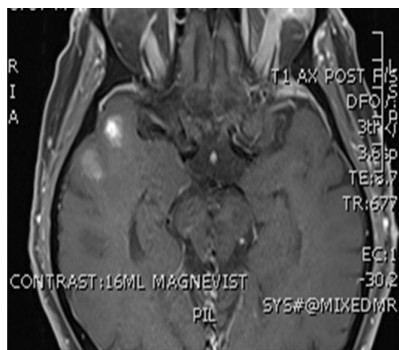
The patient is a 76 y/o M with subacute onset of left eye swelling, proptosis, and ptosis. No pain, redness, or discharge was noted. Antibiotic therapy produced no improvement. The patient also reported occasional tremor in hands for 3 months and had a generalized feeling of fatigue and balance problems. There were no headaches or difficulty with speech. An MRI done to evaluate the eye and orbit revealed enhancing lesions in right temporal lobe with associated edema. A subsequent left orbital biopsy showed diffuse granulomatous inflammation suggestive of sarcoidosis.

Past medical/surgical history: hypertension, hyperlipidemia, ablation for ventricular tachycardia.

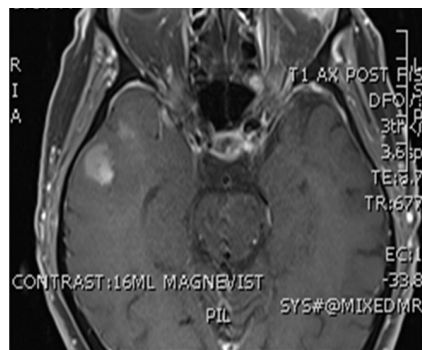
Material submitted: MRI images (T1+contrast and FLAIR), H&E-stained section

Points for discussion:

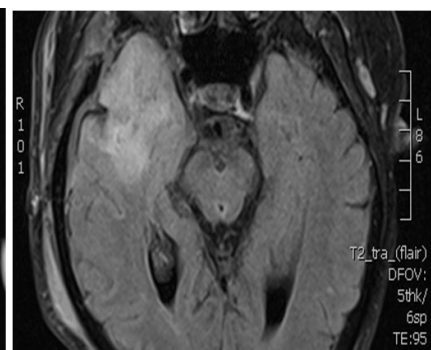
1. Diagnosis
2. Pathogenesis
3. Differential Diagnosis



T1 post contrast



T1 post contrast



T2-FLAIR