

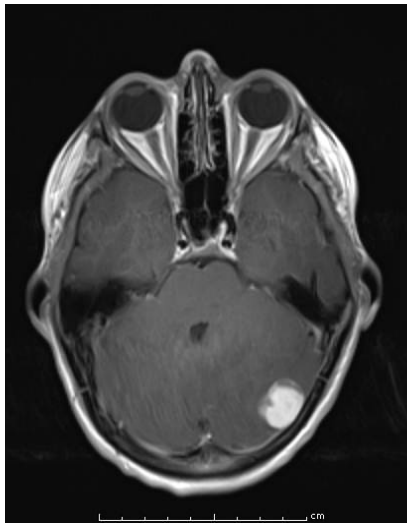
## Diagnostic Slide Session 2016 – Case 8b

**Submitted by:** Tejus Bale, M.D, PhD; Harry Kozakewich, M.D.; Sanda Alexandrescu, M.D  
Department of Pathology, Boston Children's Hospital

### **Clinical History:**

This 12-year-old boy presented with slight headaches of approximately one month duration. Magnetic resonance imaging (MRI) demonstrated a 2.2 centimeter mass in the left cerebellar region (see Neuroimaging). His past medical history was notable for adrenal neuroblastoma diagnosed at the age of 7, and treated with chemotherapy, surgical resection, radiotherapy and stem cell transplant. He responded well to therapy and there has been no evidence of recurrent disease.

**Neuroimaging:** Axial T1 post-contrast MRI: 2.2 cm lobulated, contrast-enhancing, dural mass without a tail-sign, contrast enhancing.



### **Material Submitted:**

- 1) One virtual H&E slide

### **Points for discussion:**

- 1) Differential diagnosis
- 2) Ancillary studies
- 3) Selection of molecular tests