

57th ANNUAL DIAGNOSTIC SLIDE SESSION 2016

Submitted by:

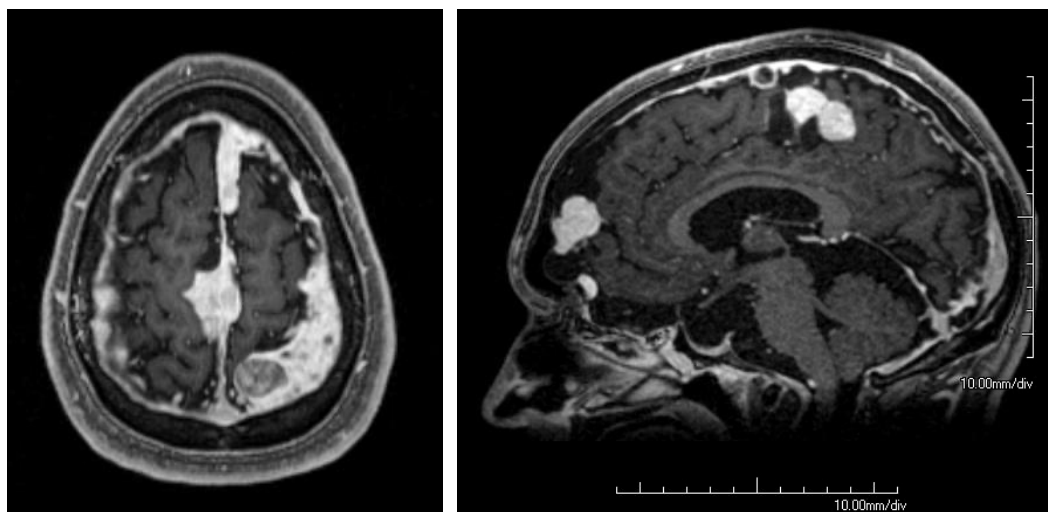
MacLean P. Nasrallah, MD PhD¹; Mariarita Santi, MD PhD²; Maria Martinez-Lage, MD¹

¹Department of Pathology and Laboratory Medicine, Hospital of the University of Pennsylvania

²Department of Pathology and Laboratory Medicine, Children's Hospital of Philadelphia

Clinical History:

A 19-year-old male with history of narcolepsy, but otherwise healthy with normal development and cognition, presented with one month of daily headache and a single unprovoked transient confusional episode consistent with a seizure. During the episode, the patient experienced right upper extremity incoordination, orolingual automatisms and aphasia. Physical examination was notable only for macrocephaly. MRI of the brain revealed multiple heterogeneously enhancing dural-based masses and dural nodularity with mild parenchymal volume loss, thinning and remodeling of the calvarium, remodeling of the skull base, and sagging appearance of brainstem.



Cerebrospinal fluid analysis was normal except for elevated protein content. Electroencephalography (EEG) showed left temporal focal slowing with sharp transients. Extensive serologic testing was within normal limits, notable for normal ANA, ANCA, RF, RPR, Quantiferon Gold, FSH, LH, prolactin, TSH, SPEP, antigliadin antibody, and IgG4, as well as negative HIV. A biopsy of the left parietal dural-based nodule was performed, but did not yield a definitive diagnosis. The patient was treated with levetiracetam and corticosteroid therapy and discharged home with planned outpatient follow up. Approximately four weeks later, he presented with recurrence of severe retro-orbital headache and emesis. A second biopsy, this time of a left frontal dural-based nodule was performed.

Material submitted:

1. H&E-stained section of left frontal dural-based nodule

Points for discussion:

1. Differential diagnosis and ancillary studies
2. Prognosis