

58th ANNUAL DIAGNOSTIC SLIDE SESSION 2017.

CASE 2017 - 9

Submitted by: Sanda Alexandrescu M.D.; Sara O Vargas M.D.
Department of Pathology, Boston Children's Hospital

Clinical History:

The patient is a 3-year-old previously healthy girl, who presented to an outside emergency department with a complaint of 2-3 weeks of intermittent right-sided headaches.

Magnetic resonance imaging (MRI) demonstrated a right superior temporal gyrus tumor involving the cortex and leptomeninges. The tumor was resected. During the surgery, it was noted that the surface of the tumor was richly vascular, and the tumor abutted, but did not attach to the dura. Gross examination revealed red-brown, soft fragments of tissue (3.5 x 2.1 x 1.5 cm).

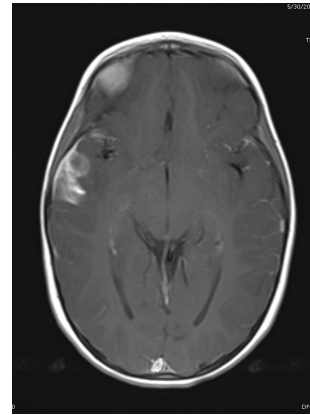


Fig. 1. T1 hyperintense right temporal lobe tumor

Material submitted:

- 1) One virtual H&E slide

Points for Discussion:

- 1) Differential diagnosis
- 2) Ancillary studies
- 3) Integration of molecular test results, and their clinical implications