

60th ANNUAL DIAGNOSTIC SLIDE SESSION 2019.

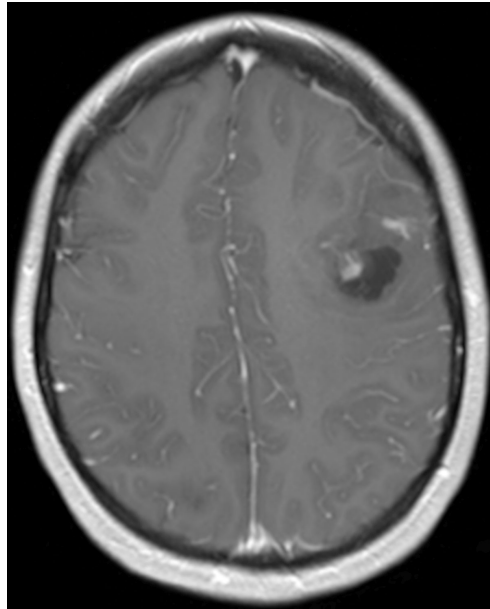
CASE 2019 #1

Submitted by: **Catherine Gestrich DO**, Audrey Jajosky MD, PhD,
Navid Sadri MD, PhD, Marta Couce MD, PhD, and Mark Cohen MD

University Hospitals Cleveland Medical Center/Case Western Reserve
University
11100 Euclid Ave
Cleveland, OH 44106

Clinical History:

Our patient is a 22-year-old female with no significant past medical history who presented to the Emergency Department following two witnessed generalized tonic-clonic seizures. MRI demonstrated an expansile mass located in the left frontal lobe, insula and external capsule. Within the mass, there was a 1.6 x 2.1 cm cystic area located in the left frontal lobe which contained a 7 x 9 mm enhancing lesion. The remainder of the mass demonstrated no enhancement.



Material submitted: - an H&E section of left frontal mass
- diagnostic MRI

Points for discussion: 1. Differential diagnosis
2. Diagnostic work-up
3. Prognosis