

50th ANNUAL DIAGNOSTIC SLIDE SESSION 2009

CASE 2009-3

Submitted by: Sandra Camelo-Piragua, M.D. and Matthew P. Frosch M.D., Ph.D.
C.S. Kubik Laboratory for Neuropathology, Pathology Service, Massachusetts General Hospital, 55 Fruit St, Boston, MA 02114

Clinical History: A 61-year-old man presented to his primary care physician complaining of episodes of lightheadness and hot flashes. He also reported subtle word finding difficulties, progressive loss of right leg strength, forgetfulness, and difficulty with attention at work.

His past medical history included hypercholesterolemia, gastroesophageal reflux, depression, anxiety, sleep apnea, asthma, and benign prostatic hypertrophy.

MRI showed a heterogeneously enhancing lesion with an ovoid shape located in the medial left frontal lobe and cingulate gyrus. The lesion was T2 hyperintense with areas of nodular and peripheral rim enhancement. The mass appeared to extend into the falx with linear enhancement of the anterior and posterior portions of the falx around the lesion. There was a suggestion of cortex displaced posteriorly by this lesion, favoring an extra-axial location.

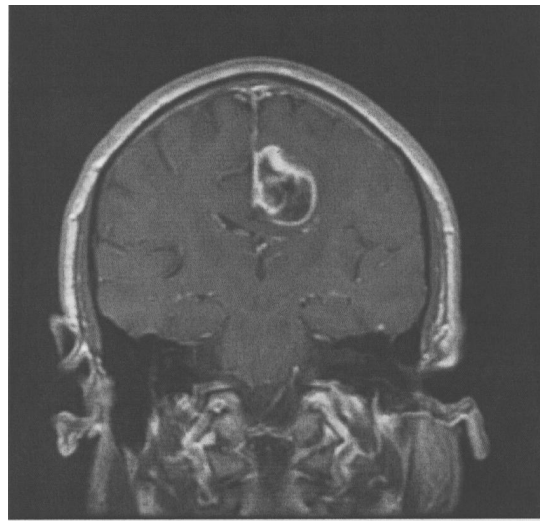
The patient underwent a bifrontal craniotomy for tumor resection.

Material submitted:

One representative H&E virtual slide from the surgical specimen and a representative T1 MRI image from the lesion

Points of discussion:

1. Differential diagnosis



T1 weighted post-contrast MRI